



(http://www.rxpgonline.com/)

Mobile Edition (http://www.rxpgonline.com/mobile) | Help/Newbie? (http://www.rxpgonline.com/forum61.htm) | 24/7 Support (http://www.rxpgonline.com/help)

RxPG Forums

GO

RxPG Sections

GO

HOT (http://www.rxpgonline.com/hot.html) | **PrePG** (http://www.rxpgonline.com/pg-india.html) | **MCQ** (http://www.rxpgonline.com/forum33.htm) | **DNB** (http://www.rxpgonline.com/dnb) | **Careers** (http://www.rxpgonline.com/careers.html) | **Books** (http://www.rxpgonline.com/textbooks) | **Colleges** (http://www.rxpgonline.com/colleges) | **Dental** (http://www.rxpgonline.com/rxbds.html) | **DocIndia** (http://www.rxpgonline.com/docindia) | **PLAB** (http://www.rxpgonline.com/plab-uk.html) | **USMLE** (http://www.rxpgonline.com/usmle-gre.html) | **Australia** (http://www.rxpgonline.com/amc-australia.html) | **Canada** (http://www.rxpgonline.com/mccee-mccqe.html) | **GLOBAL** (http://www.rxpgonline.com/international.html) | **OffBeat!** (http://www.rxpgonline.com/offbeat.html)

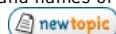Articles (http://www.rxpgonline.com/latestarticles.html) | **Forums** (http://www.rxpgonline.com/forums.html) | **MCQ Crammer** (http://www.rxpgonline.com/modules.php?name=Crammer) | **Downloads** (http://www.rxpgonline.com/downloads.html) | **Mnemonics** (http://www.rxpgonline.com/mnemonics.html) | **Revision Tools** (http://www.rxpgonline.com/modules.php?name=Revision_Tools) | **Recent Shouts** (http://www.rxpgonline.com/modules.php?name=shouts) | **All Features** (http://www.rxpgonline.com/features.html)

Special Offer: Amazon Prime Free for A Month (http://www.amazon.co.uk/gp/feature.html/?ie=UTF8&docId=1000784673&tag=rxpgonline-21)

RxPG PLAB 1 Forum (http://www.rxpgonline.com/forum138.htm)

All Plab Past Papers HERE

Note for PLAB 1 forum users: Do not use this forum for buying/selling/trading of materials and books, even if it is for free. Do not try to post your email address in the p not post the brand names of any coaching courses. These are serious violations of RxPG terms of service and your account and IP can be permanently banned



(modules.php?name=Forums&file=posting&mode=newtopic&f=138)



(modules.php?name=Forums&file=posting&mode=reply&f=138)

Goto page 1, 2 (postx108126-0-50.html) Next (postx108126-50-100.html)

Page 1 of 2

Author

**Syrian** (http://www.rxpgonline.com/threads70530.html)

(http://www.rxpgonline.com/modules.php?name=Messenger&file=buddy&op=compose&to=Syrian)

Titan



Posts: 124

Credits: 7019 (http://www.rxpgonline.com/docs/credits)

Message

Fri May 21, 2010 10:33 pm (4 years ago) #1 (modules.php?name=Forums&file=viewpost&tid=70530)

Recall: All Plab Past Papers HERE

Dear September Plabbers .

I would like to present you all the past papers which i have ...

I collected them from this Website , and i hope they can help ..

DON'T FORGET TO CHECK THE ANSWERS

BEST WISHES.....

report this post to a moderator (http://www.rxpgonline.com/report/index.php?p=899337&h=1&u=)

please rate this post (http://www.rxpgonline.com/modules.php?name=usertools&file=pvote&vote=up&u=503349&s=70530&n=1&f=138&t=108126&p=899337)

(http://www.rxpgonline.com/modules.php?name=usertools&file=pvote&vote=down&u=503349&s=70530&n=1&f=138&t=108126&p=899337)



(modules.php?name=Forums&file=posting&mode=reply&t=108126) (modules.php?name=Forums&file=posting&mode=quote&p=899337)



(http://www.rxpgonline.com/modules.php?name=usertools&file=pvote&vote=up&u=503349&s=70530&n=1&f=138&t=108126&p=899337)

(http://www.rxpgonline.com/modules.php?name=usertools&file=pvote&vote=down&u=503349&s=70530&n=1&f=138&t=108126&p=899337)

Back to top

UNANSWERED: **Study partner in UK for plab 1** (http://www.rxpgonline.com/postt267375.html)**Syrian** (http://www.rxpgonline.com/threads70530.html)

(http://www.rxpgonline.com/modules.php?name=Messenger&file=buddy&op=compose&to=Syrian)

Titan



Posts: 124

Credits: 7019 (http://www.rxpgonline.com/docs/credits)

Fri May 21, 2010 10:35 pm (4 years ago) #2 (modules.php?name=Forums&file=viewpost&tid=70530)

February 2010

Theme: abdominal pain in women (repeated)

1. abdominal pain, excited cervix Ectopic pregnancy
2. abdominal pain, several partners, vaginal dischargePID
3. patient with dyspareunia ,dysmenorrhea, multiple nodules on (
- ligament.....endometriosis
4. infertile lady had three children with previous partners ...fibroids
5. rebound right lower abdominal painappendicitis

Theme: incontinence (repeated)

6. urge incontinence.....detrusor instability
7. a lady gets incontinent when she coughs or carries her baby 3 weeks after delivery c
- second baby.....weak pelvic floor muscles
8. another was a lady who is wet all the time after a pelvic operationfistula

Theme: vaginal bleeding (repeated)

9. A 24 years old woman comes with intermittent vaginal bleeding. She is on OCP for 7
- When viewed, her cervix appears ectropion erosion and doesn't bleed on touching. What
- SINGLE most appropriate initial management cervical smear
10. a lady done a smear and was mild dyskeratosis what is the next step.... colposcopy
11. A woman on HRT treatment had regular withdrawal bleeds until 3 years ago now present
- brown stained discharge. What is the SINGLE most appropriate diagnostic test... Transv
- ultrasound scan
12. A 39 years old woman presents with 10 months amenorrhea. She has a familial history of
- menopauses. .

What is the SINGLE most definitive test ...FSH/LH

13. lady with menorrhagia feeling tired all the time initial investighb concentration

Theme: PPH (repeated)

14. A lady with bleeding PV 10 days after delivery. Uterus well contracted. ... retained pr of conception/infection

15. A lady, diabetic, baby 4.8kg... Large placenta

16. 38 yr old women has delivered after an induced labor which lasted 26 hrs.... atonic

17. delivery with rotation forceps...cervical trauma

18. still born infant vaginally.... DIC.

Theme: prenatal screening

19. cystic fibrosisChorionic Villus sampling

20. Pregnant lady, 18 weeks pregnant, want to know whether her baby has spina bifida l

21. Duchenne muscular dystrophycord blood

22. Pregnant woman did not take folic acid, want a definite test for spina bifidaAFP

23. Couple, man's father has Huntington's disease, want to know if pregnant, the chance of baby having it.... Parents genetic analysis

24. Pregnant woman, had short limb child before, want to know whether this baby has the problemUSG

Theme: congenital heart disease

25. murmur extending from systoli to diastoli (in that case it is pansystolic) and obscuring S2, infection ventricular septal defect.

26. presented within first few days of life with severe cyanosis that did not respond to O ...transposition of arteries

27. with radiofemoral delaycoarctation of aorta

28. A child with bounding pulse, early diastolic murmur Epsteins syndrome

Theme: non-accidental injury (repeated)

29. A child with fracture parents said he fellskeletal survey

30. A child irritable with retinal haemorrhageCT

31. A child with bruises in different shape and ages.....skeletal survey

32. child with bruises, lymphopathy, splemegaly, cared by stepped faterFBC

Theme: Fluid resuscitation in children (repeated)

33. An infant with s/s of mild dehydration only....dry mucous membranes but good skin tur ORS 90 Na mEq/L

34. An infant with dry membranes, drowsiness, decreased skin turgor...(its more the dehydration) IV fluid bolus over 20 minutes

35. A baby girl has got diarrhoea 10 days ago, now presents with his mother who is conc about his status...baby has moist mucous membranes Reassure

Theme: Management of electrolyte imbalance (repeated)

36. A young man presents with nausea and vomiting. Weight loss/ or gain. investigation shc 129, K 5.2, UREA 12, GLUCOSE 4 ... IV n saline plus steroids

37. A young man with weight loss, thirst and urinary frequency. NA 148, K 5.2, UREA 12, GLL 30 ... IV 0.9% saline with insulin

38. A 20 years old man involved in RTA suffers multiple fractures and crush injuries.4 days lat is anuric with pulmonary oedema. NA 150, K 7.7, UREA 60 ... dialysis

39. A 50 years old man has had admitted for investigation breathlessness and weight loss. t been taking a thiazide diuretic for raised blood pressure for 2 years. His blood press 150/100. NA 138, K 2.9, UREA 5.8 ... potassium orally

40. An 8 years old boy with gastroenteritis gave a 2 day history of profuse diarrhoea and von NA 148, K 2.2, UREA 20 saline plus potassium

Theme: chest x ray appearance (repeated)

41. man with trauma to chest and was in shock ... wide mediastinum

42. man with guarding abdomen and tender abdomen ...gas under diaphragm

43. man with operaton for oesophagus and some more history ... gas in the mediastinum

44. MI ... normal Xray.

45. decreased broncho vasc marking.... pneumothorax

Theme: investigation of epigastric pain

46. A patient with epigastric pain. Had similar complaint 4 years back for which he was tr with 3 drugs.

.....endoscopy

47. Abdominal pain radiate to back, diagnosed with gall stone 2 years agoERCP

48. RUQ pain, nausea (picture of cholecystis).....USG

Theme: bacteria causing diarrhea

49. A man had seafood in a wedding, diarrhea?

50. diarrhea after antibiotics C difficile

51. A man diarrhea after eating in a restaurant?

52.

53.

Theme: arrhythmia

54. SVT + HR 200 adenosine

55. VT with hypotension Amiodarone/DC

56. AF with hypotension DC/DIGOXIN

57. Complete heart block in MI Cardioversion/Transthorasic pacing/ATROPINE

58. irregular pulse etc Digoxin

Theme: investigation and diagnosis of haematuria

59. Guy with gross haematouria with clotscystoscopy

60. A guy presents with high bp 180/ 100 and haematouria ten yeas ago recurrent heamtouria

61. Girl with frequency and blood at the end of micturition plain xrMSU?
 62. Man, Rhinorrhea, haematuriaWegner's disease

Theme: testicular mass investigation (repeated)
 63. mumps. neck swelling and testicular swelling ... reassurance
 64. Leukemia ... testicular biopsy (no CT option)
 65. blue scrotum ... reassurance

Theme: diagnosis of endocrine diseases (repeated)
 66. Man, increased BP (very vague symptoms)....pheochromocytoma
 67. decreased serum KConn's
 68. Man, lost weight, palpitation, investigationThyroid function

Theme : Cranial nerve lesions (repeated)
 68. A patient has problem in moving shoulder after a surgery in neck... Accessory nerve XI
 69. A patient with some lesion of fore-head which has affected cornea too.... Trigeminal ner
 70. A patient with drooling of saliva and can't open his eyes. ... Facial nerve VII
 71. A patient tongue deviates to left side on protrusion.... Hypoglossal nerve XII
 72. A patient has diplopia on looking upward and fixed dilation of right pupil.... Oculomotor III

Theme: serology (repeated)
 73. Police bitten by heroin addict..... Hepatitis-B serology
 74. Man came from Zambia with swinging Fever T39..... Malaria serology
 75. girl walked in forest Lyme disease (bordetella . P)

Theme: reduced vision (repeated)
 76. A elderly man with reduced vision, not improving with spectacles. Fundoscopy shows yell lesions seen at centre of posterior pole.... Macular degeneration
 77. A lady on treatment for Rheumatoid arthritis, now having reduced vision. Red reflex absent examination....
 Cataract
 78. A man with sudden loss of vision in an eye which resolved soon. Had similar episodes in past....Amoroxis fugax
 79. A man with hypertension with sudden and painless diffuse redness of an eyeSubconjunctival bleed
 80. A person with reduced vision, retinal microaneurysms on fundoscopyDiabetic retinopathy

Theme: Deafness
 81. A woman after pregnancy presented with reduced hearing, bone conductive hearing Weber's test not lateralising Otosclerosis
 82. A 6 years old girl is not able to hear well at school. bone conduction normal, Weber's test lateralizing threshold reduced on both ears. ... Otitis media with effusion. X
 83. An elderly man finding it difficult to hear in background noise tympanic membrane retracted etc.... presbycusis
 84. A young man with a history road accident a few months ago. and x-ray showed parietal fracture... Functional deafness / head injury
 85. vesicles in ear..... herpes

Theme: orthopaedics (repeated)
 85. pt with LBP and sciatica after lifting....Disc prolapse
 86. LBP and iritis....Ankylosing spondylitis
 87. LBP WITH high esr and proteinuria....myeloma
 88. pt on prednisolone treatment for RA.... osteoporotic vertebral fracture

Theme: Psychiatry
 89. A young patient thinks his intestine got obstructionNihilistic/precutory
 90. A patient thinks he is responsible for world wide famine Guilt
 91. Young man claims when he reads newspaper he can communicate with the authordelusion of reference
 92. A patient thinks he has got some sort of cancer..... Hypochondria
 93. A man blames his friend to swing his hand to stranger.....Precutory/control/nihilistic
 94. a wife is convinced that her neighbour was using her shower when nobody at home husband believed this and called the police..... faux pas (a delusion shared by 2 people)

Theme: anxiety neurosis (repeated)
 95. A lady feels anxiety and uncomfortable whenever she goes out of home. She is comfortable while in her home... Agoraphobia
 96. A lady complains episodes of breathlessness, peri-oral tingling, and palpitations. This happened after her mother died in a disaster. ... adjustment disorder (typical panic attack picture, but I think it's adjustment disorder bc the death of her mother, not sure, panic attack was in the option list)
 97. A person doesn't go outside the home because he thinks that people will look at him and about him found it difficult to associate with his peers in a restaurant. ... social phobia

Theme: drugs side effects
 [snip]. A patient who is taking gentamicin and benzylpenicillinOtotoxicity
 99. ciprofloxacintendon rupture
 100. cotrimoxazole Stevens-Johnson
 101. vancomycin.... grey man syndrome
 102. flucloxacillin.... cholestatic jaundice
 SBA
 103. A COPD patient presents with breathlessness and purulent sputum with oxymetry (Repeated). Pa O2 = 7.6, Pa CO2 = 7. Which is the appropriate management... 24%O2 (Repeated)
 104. Woman, breathless after taking a flightCT (no V/Q option) (repeated)
 105. An asthmatic patient uses b2 agonist and the highest doses of steroid inhalers still present

- with night symptoms. Which drug should be added in the next step... oral theophylline?
106. pneumothorax ... needle thoracocentesis/inset wide bore canula
107. Obese pt with day time sleepiness & tired obesity... sleep apnea (repeated)
108. Pt on low molecular heparin developed PE... increase dos and ctpa
109. A patient presents with a mass in subclavicular R side and petosis,... (Repeated). What most likely location of tumor... right bronchial ca/pancoast
110. Man, right lower abdominal pain, lost weight, occult blood in stool Celiac ca (repeated)
111. Man, left lower abdominal pain, not mention bloody stool sigmoid ca?
112. A 45 years old African Caribbean woman patient with BP= 160/100. What is the SINGLE likely treatment) Ca-channel blockers
113. a body with big heart, regular heart beat 200 carotid massage
114. A patient presents with yellow visual halos, arrhythmias, nausea. Which drug's side effect ... Digoxin (Repeated)
115. Man, poor urine stream, palpable abdominal mass. Initial management urinary catheter
117. Man, quickly growing lump at right side of neck, stridor thyroid ca (repeated)
118. a person with lid lag also he has some difficulty in looking upwards... Tension test
119. Pt brought unconscious, one eye dilated, not reactive to light extadural bleed ... possible bleed (subarachnoid bleed was another option)?
120. another pt also dilated pupile, unconscious subarachnoid bleed
120. An elderly man with h/o fall & injured his knee. Answers slowly & quietly. Diagnosis Transient ischaemic attack
121. An old woman has ulcer in labia 3cm with 1.5cm deep. Which lymph node will be involved Superficial inguinal lymph node (Repeated)
122. a lady with multiple lumps on vulva human papilloma virus
123. Woman with abdominal pain, vaginal discharge, antibiotic to use ciprofloxacin metronidazole (empirical treatment for PID)
124. A woman presents after delivery with painful and tender, red breast. What is the causative organism... Staphylococcus aureus (repeated)
125. A lady who was infertile and they were asking about the best test to prove ovulation ... luteal cycle progesterone (repeated)
126. A woman who was diagnosed with hydatidiform mole, what is the follow up from six weeks to 6 months serum b-hcg (repeated)
127. A pregnant lady with h/o seizures. Best way to prevent further seizures..... / (repeated)
128. child with crusting on face and neck topical/oral antibiotic
129. a child with barking cough and fever 37.9 Oxygen by mask/IV antibiotic
130. pregnant lady who left her child unattended for several hours... maybe the child took iron concentration
131. patients bring 1 month old girl, had been anemia and jaundice since 1 week old, they were unable to see doctors earlier biliary atresia (repeated)
132. An African man presents with some raised lesions on the shin. He comes with cough, breathlessness and arthralgia and on examination hilar lymphadenopathy is present. What SINGLE investigation most likely lesion on skin... Erythema nodosum (repeated Q)
133. A middle aged man complains of a node which has been grown in his nose for six months. Now it is firm with central depression/umbilication. Its size is 0.6 cm. What is the SINGLE most likely diagnosis ... Basal cell carcinoma
134. A 30 years old woman took 100 paracetamol tablets, now he is in A&E. You want to give treatment but she has simply refused and doesn't allow any treatment. She wants to be discharged. What is the SINGLE most appropriate next action ... assess ability to refuse (repeated)
135. A female with s/s of severe depression, still presents with no improvement even after anti-depressants. What is the SINGLE most appropriate investigation ECT (repeated)
136. A man with history of prostatectomy and post MI man presents with symptoms of depression. What is the SINGLE most appropriate treatment ... Fluoxetine (repeated)
137. A man who hears the voice of his dead brother telling him he is being spied on. What SINGLE most appropriate treatment.... Olanzapine
138. A man becomes aloof, hears his dead uncle telling him to die, diagnosis schizophrenia (repeated)
139. An alcoholic patient comes to emergency (or he is in ward for some reason) his glucose is unstable he has got opthalmoplegia.. His blood glucose is 3.5mmol. What is the SINGLE most appropriate next action... Thiamine (repeated)
140. The guy who wants a drug to stop drinking without unpleasant systemic effects - acamprosat (repeated)
141. a young girl was visited by Diabetes nurse. she misses most of her insulin dosage at school meals. she is really upset as she looks different from others in school. ... Consult psychologist/dietitian
142. 80 lady with distal fracture radius 10 deg dorsal tilt, what to do... BEC. X (close reduction)
143. A patient with upper respiratory tract infection, now with worsening periorbital swelling and proptosis ... CT orbit (repeated)
144. A patient who is already on warfarin is planned for abdominal surgery. What would you do next... Stop warfarin and start heparin (repeated)
145. Prophylactic antibiotics for a patient posted for surgery for carcinoma sigmoid colon. What broad spectrum antibiotic at induction/ Something 3d before surgery

146. A person on antibiotics, now having loose stools (pseudomembraneous colitis pic Treatmentmetronidazole (repeated)
147. A pt with carcinoma having severe anorexia, treatment..... Oral steroids (repeated)
148. Pt with inoperable carcinoma stomach with pain due to metasis, treatment1 week t steroids
149. A patient presents with polyuria and polydipsia, lethargy and weakness, secondary malignancy. What is the most likely single initial management ... IV fluid (Repeated)
150. An 82 years old man came with intestinal obstruction due to adhesion of previous oper He was dementia and no history was available. He died after operation. Pathologist i multiple nodules scattered in the liver, with central depressions. What is the SINGLE most diagnosis.... Secondary CA
151. A woman has been stung by bee, she has Erythema, hypotention, tachycardia but overal and O2 saturation was around 92%. What is the SINGLE most appropriate treatment... Adrenal (repeated)
152. A child attending nursery a child with sore throat, fever is dribbling saliva. What SINGLE investigation most appropriate treatment.... Call anaesthesiologist (repeated)
153. risk of DVT in a patient who undergone a spleenectomy and smokes 5 cig per day and has mobilised splenectomy
154. Anatomy hallmark for indirect inguinal hernia , , , deep inguinal ring (repeated)
155. A guy with wheeze fever with chronic problem, elevated urea and creatinine which should be used with cautionclarithromycin
156. a breast cancer women with metastasis.... dexa scan (repeated)
- 157 Woman with RA, NSAID does not help, next step ... steroids
158. type 1 DM with ketoacidosis symptom. .. do ABG (repeated)
160. child with epistaxis..... pinc soft part of nose (repeated)
161. a women with postural hypotension..... standing and lying bp (repeated)
162. angina on exertion..... echocardiography (repeated)
163. child with 4% burh crying loudly... give analgesia (repeated)
- Theme: investigation/diagnosis of childhood asthma
164. Child has asthma, mother does not know when to give him inhaler.. .. peak flow diary.
165. Child had two episodes of asthma in the past year. Mother is atropic. .. Spirometry.
166. Child with exercise induced asthma and now normal cromoglycate

Theme: detoxication

167. a heroin addict wants to quit..... methadone
168. an alocoholic wants admitted to prevent delirium tremens... chlodianzopoxide
- 169 Woman, taking amphetamine, but not ready to withdrawl from it completely... ?

Theme: brain hemorrhage

170. Patient with fluctuating consciousness .. Extradural hemorrhage
171. Alcoholic with falls.... Subdural hemorrhage
172. Patient with speech problems and paresis..... Cerebral hemorrhage

Theme: investigation of seizures

- 173.. a patient with seizure toxicity..... serum drug level
174. a boy with symptoms af absence seizure.. EEG

Theme: haematuria (continue of an above theme)

175. Patient with facial rash and features of glomerulonephritis Lupus nephritis
177. A girl with perineal bruising and hematuria IVU


SBA

178. a patient with petecie over neck and multiple fracture.. fat embolism
179. a boy with swollen knee and fever.... septic arthritis
180. a boy with red eye and discharge..... antibiotic eye drop
181. a patient with hyperemesis gravidarum.indial investigation.... serum urea and electrolyt
182. a patient with mood disorder on lithium wants to become pregchange to something is it lorazepam?
183. a patient with jaundice and itching.... cholestyramine
184. A child with fever and rash on the body, drawsy.... Blood culture
- 185 A man with TIA .. initial management .. Aspirin
189. an elderly woman falls and she live alone and wants to be independant. what investigat CT brain





A few questions below, not sure whether they were in the test or not:

190. Man, using monoscope to spy his neighbor because he suspect them stealing his cattle ...
191. cushing syndrome.
192. Anatomy hallmark of carpel tunnel syndrome ... medial N at wrist level
193. cervix x-ray ...C8/T1.

report this post to a moderator (<http://www.rxpgonline.com/report/index.php?p=899339&h=2&u=>)

please rate this post  (<http://www.rxpgonline.com/modules.php?name=usertools&file=pvote&vote=up&u=503349&s=70530&n=2&f=138&t=108126&p=899339>)

(<http://www.rxpgonline.com/modules.php?name=usertools&file=pvote&vote=down&u=503349&s=70530&n=2&f=138&t=108126&p=899339>)

 [Reply](http://www.rxpgonline.com/modules.php?name=Forums&file=posting&mode=reply&t=108126) (modules.php?name=Forums&file=posting&mode=reply&t=108126)  [quote](http://www.rxpgonline.com/modules.php?name=Forums&file=posting&mode=quote&p=899339) (mo name=Forums&file=posting&mode=quote&p=899339)  [Scrapbook](http://www.rxpgonline.com/modules.php?name=RxPGites&mode=scrapbook&uid=70530) (http://www.rxpgonline.com/modules.php?name=RxPGites&mode=scrapbook&uid=70530)  [PM](http://www.rxpgonline.com/modules.php?name=Private_Messages&file=index&mode=post&u=) (mo name=Private_Messages&file=index&mode=post&u=

Back to top

**Syrian** (<http://www.rxpgonline.com/threads70530.html>)(<http://www.rxpgonline.com/modules.php?name=Messenger&file=buddy&op=compose&to=Syrian>)

Titan



Posts: 124

Credits: 7019 (<http://www.rxpgonline.com/docs/credits>)**November 2009**

- 1.A person with long standing 1 cm lesion that started to bleed on touchsquamous carcinoma.
- 2.A person with acute onset of red eye ,pain,blurry vision,periorbital oedema. Single best management?.....iv morphine (or i think was antib) and emergency opththamological refer
- 3.A patient with transitional ca of the bladder wanted to know what was the main risk fact him acquiring it.....aniline dye.
- 4.A woman post partum presented with an episode of fit and ele bp...treatment?.....magnesium sulphate
- 5.A 4 wk old baby presented with expiratory wheeze , nasal discharge ...diagnosis?...bronchiolitis
- 6.A patient with classic signs oh panic attack...treatment? Rebreath in an airbag

Theme on depression management

7. An elderly woman stopped eatind and drinking ,was diagnosed of psychotic disorder in her 30 shad 10 episodes each requiring hospital admission she presently on long term antidepressant and lithium electroconvulsive therapy
- 8.a 35 yr old woman with 4 admissions to psychi ward 2 with depression 1 mania.....lithium
- 9.A 26 yr old previously suffered from 'blues ' after the birth of her first baby, now with 2nc she is withdrawn,depressed etc and convinced her husband trying to kill her baby ,she is al on antidepressants.....electroconvulsive therapy
- 10.A young dentist thinks he is a failure and developed low mood despite evidence t contrary, he has no confidence in himself etc but there are no somatic symptoms of deprcognitive behaviour therapy
- 11.A woman develops tearfulness,finds it difficult to concentrate,lost her confidencetricyclic

Theme on investigation of acute dyspnoea

- 12.A man presented to A&E with SOB of 3 days duration , coughing and using his salbutamol i more frequently?..... Peak expiratory flow
- 13.A man presented to A&E with sudden sharp right sided chest pain and SOB with reduc entry on the right side.....CXR
- 14.An elderly woman brought to A7E by family presented with breathlessness ,occasional etc with coarse creps at lung baseCXR
15. A woman returned from holiday develop sudden left sided chest pain and SOB.....CT (chest .

Theme on headaches and eye problems

16. Elderly woman feeling generally unwell and anorexic with loss of weight sudden loss of etcESR
- 17.Woman with sudden onset of severe occipital headache.....CT brain
- 18.Woman with headache,nausea vomiting she noticed haloes etcintra ocular pressure
18. A child was admitted (after trauma i think) with initial GCS of 15 then during night the noticed GCS to be reduced to 13.....CT scan of the brain .

GI theme ...Single most important aetiological factor

- 19 . A young man with 3 moths history of epigastric pain that smoke 20 cigarettes a day .. helicobacter pylori
- 20.Elderly woman with long standing back painNSAIDS
21. A woman with RA who is intolerant to NSAIDS....CORTICOSTEROIDS
- 22.A woman with primary parathyroidism responding poorly to PPI ...gastrinoma
23. Elderly man with heartburn for many yrs with acid reflux....Barret's oesophagus

Speech disorder Theme

24. 14 month old child not yet walking independently with no abnormalities on neurologicalReassure
25. A 3 yrs old boy has no vocabulary and does not respond to his moth's command etc....h test
- 26.A baby not showing any interest in his mother while playing , he does not fix and follow an exam for urgent opthamology referral
27. A 2 yr old child , motor development normal, has become upset,remains , does not like t in conversation with other children etcreferral to social worker (an aloof indicates abuse)

- 28 . A woman 12 wks pregnant with E.coli UTI treatmentTrimethoprim (I hope u car that to preg mothers guy)

- 29.A man hit on the superior part of the knee which fossa involved....prepatellar fossa
- 30.A child had tonsillectomy and adenoids removed presented with infection signs and bleedingantibiotics and urgent referral to surgery
- 31.A man has developed a red ,raised rash on trunk after playing football , he had asthma as a ,rash is becoming increasing itchy ..appropriate treatment ?.....oral chlorpheniramine.

GI theme most appropriate management

32. Child with recurrent abdominal pains, occasional headaches but she maintains a appetite , no abnormal signs , FBC,U&E etc normal....Reassure
33. Child with right sided abdominal pain,symptoms of UTI, abdominal US shows right

Hydronephrosis and excretory isotope scan showed PUJ obstructionpyeloplasty percutaneous nephrostomy)
 34.14 yr old boy recurrent abdominal pains, malaise ,wt loss over 6 months ,vague mass in iliac fossa, colonoscopy and biopsy show transmural inflammation GRANULOMATA.....sulphasalazine
 35.A child had recurrent abdominal pain , appetite reduced, faecal soiling ,masses through o abdome, dilated loaded rectumenema and laxatives
 36.12 yr old recurrent abdominal pain,relieved by food ,tender in epigastrium,test reveal Pylori infectiontriple therapy .

Investigation theme

37. Elderly man with bone pain,anaemia ,wt loss,renal failure ,hypercalcemia....Bone m aspirate
 38.a patient with leg swelling , ++++proteinuria, serum creatinine elevated.....Renal biopsy
 39.Elderly man with frequency of micturation,poor stream, incompetence, serum crea elevated...renal biopsy
 A woman with urinary frequency,wt loss, hematuria,blood clots,abdominal inconclusive...Cystoscopy

Psychi Theme

40. Man talking about various topics.....Flight of ideas
 41.Woman admitted to psychi ward believes that staff know exactly what she is thThought broad casting
 42.A man with some problem and he recognises he has a problem ...insight
 43.A woman speaking rapidly without pausingPressure of speech

Diagnosis of scrotal swelling .

44. a man with painful swelling with dysuria ,frequency of micturition and tem 38 C....epidid orchitis
 45.A man with painless swelling one testis is 3 times the size of the other and tender...hydrocele
 46.A man with painless 1 cm swelling to upper pole of right testis...epididymal cyst
 47. Child presented with severe unilateral testicular pain of sudden onset...torsion of testis.

48. A man who smokes and long history of breathlessness on exertion ,productive cough pres with the following blood gas result

PO2 7.0 kPa

PCO2 6.5 kPa

pH 7.30

WHAT IS THE SINGLE MOST APPROPRIATE TREATMENT

- a. aminophylline infusion
- b.invasive ventilation
- c.non invasive ventilation
- d.24% OXYGEN.....correct answ (dont forget in type 2 respiratory failure CO2 respiration so dont ever give 100% oxygen)
- e. 100% OXYGEN

49. A child presented after trauma with glucosuria that subsequently resolved. Why?

- A. DM
- B. Pre -diabetic case
- c. stress induced ...correct answer

Theme on investigation for abnormal bleeding

50. A 39 yr old woman with early menopause signs.....FSH/LH
 51. A woman after treatment for breast ca comes to discuss her bone health following a fracture in a metatarsal bone .. DEXA scan(doing serum calcium concentraion may be c too ...i dont know)
 52. A woman on HRT treatment had regular withdrawal bleeds until 3 yrs ago now present brown stained discharge....transvaginal US
 53. A woman presented with blurred vision,intermittent clumsiness for 3 months. Reflex brisk in her arm and optic discs pale....Single test to confirm diagnosis.
 a. CSF analysis
 b. EEG
 c.EMG
 d. MRI of the brain..... CORRECT ANSWER
 e. visually evoked responses

54. Patient with paracetamol overdose refusing drug intervention.....evaluate pa ability to refuse treatment

Theme of seizure diagnosis

55. Patient with wt loss ,haemoptysis and other symptoms of tb presented with seizure...CT option for TB test i think
 56.Child with limb jerking ,teacher noticed that times he does not concentrate in class....EEG
 57. A man travelling alone,admitted from airport unconscious following a seizure in his b needles and syringe.....Plasma glucose concentration
 58. A woman developed jerking in one hand that subsequently spread into a generalised seizure with loss of consciousness.....EEG

Prostate theme

59. An elderly man with ca prostate with severe back pain waking him u nights.....radionuclide bone scan
 60 . Elderly man with ca prostate with confusion, thirst, abdominal pain and abn ECG.....serum calcium level

61. man with ca prostate on treatment comes for follow -upPSA
 62. Man with ca prostate spread outside the capsule he has acute renal failure ...i know tl should be US scan of abdomen but some how i think i didn't put this .

THEME ON HEAD TRAUMA

63. A boy fell and hit his head in the playground at school he did not lose consciousness . t swelling and tenderness of the right cheek with subconjunctival haemorrhage on his eye.....i put skull x- ray but i am now thinking that facial x-ray was an option as well if there then that is the ans.

64. A man was slapped over his right cheek presented blood coming from his external au canal , pain , deafness, ringing in his ears....otoscopy

65. A man hit his head at work. Hwe did not lose consciousness his GCS is 15 and his employ sent him to be checked.....Skull xray (this must be done for medico-legal reasons)

Theme on deafness

66. A woman who was poregnant presented with conductive hearing loss etc....otosclerosis
 67. child not hearing well at school , bone conduction normal, weber's test not lateralisir treshold reduced on both ears..... otitis media with effusion .

68. elderly man finding it difficult to hear in background noise tympanic membrane r etc....prebycusis

69. A young man after head trauma and x-ray shoed skull fracture.....
 i put functional deafness head injury was an option too which i think was too obvious to answer .

70. A baby with discrete spot to sacrum area in an afro caribbean woman reassure

71. A man was noted post hemicolectomy to have a drop of urine output from 40 mls..... check functioning of the catheter

Anatomy theme

72. extradura fracture.....middle miningeal artery

73. pt with mesenteric ischaemia of small bowels....superior mesenteric artery

74. pt with cardiac tamponade other CVS signsi put pulmonary (not sure of the anser guys)

75. Nerve injury for patient with decrease sensation , wrist swelling etcmedian nei wrist

76. A patient with decrease sensation to lateral 4th & 5th digits etculnar nerve

77. A patient with decreased sensation to dorsum of foot etc common peroneal nen

78. A woman with family history of berry aneurysm etcsubarrachnoid heamorrhage

79 A patient with pulsatile mass etcAortic aneurysm

(I am getting tired now guys so i will basically put answers)

Theme on arrhythmia.

80. ventriculat tachy....amidarone

81. SVT....adenosine

82. S&S of heart block.....cardioversion

83. irregular pulse etcdigoxin

84. An sba on a patient with yellow tingue to vision side effect of which drug Digoxin

85. Another question about a child who took grandmother medication etcdigoxin

86. I choose ace inhibitor 2 times as answers

87. A pregnant woman presented with signs of kussmal's breathing etc ...DKA

88. a answe about Acute cholecystitis

89. Treatment for paracetamol overdose....n-acetycystine

90. A Child presented after fracture with cast applied with pain and swelloing to limb but were present and limb warm and perfuse.....answe lies between remove cast or remon and replace cast with more padding .

91. A 19 yrs old girl presented with menorrhagia and irregular menses.....OCP
 92. Woman unable to conceive who had a regular 28 days cycle ..21 day progesterone was to be normal...treatmentclomiphine

93. Patient presented with offensive discharhe and lower abdominal pains... PID

94. woman with tense ascites etc with ovarian caparacentesis cytology(i think ther an entire theme on ovarian ca....cant remember now maybe later)

95. A man with blood results showing 8% reticulocytes , spherocytes , anaemia , jaundic asking for investigation....i put G6 PD enzyme assay(not sure)

96. Woman presented after havinf 2 CS, she is a smoker , BMI 27 etc.

what is the main risk factor for DVT IN THIS WOMAN ?

a. obesity

b. previous CS ... i chose this ans not sure

c. smoking

d.....

97. A question about a patient with a mole and want to know how do you know when the becomes malignant..... various colour and something about the edge.

[snip]. A patient on oral morphine for mets ca but unable to follow that regime ...what is the step in mangementdiamorphine subcutaneous infusion

Theme on breast Pathology

99. After trauma...fat necrosis

100. 20 mmm smooth mobile mass ...fibroadenoma
 101. pregnant woman with fluctuant swelling to breast...breast abscess
 102. breast ca
 103. a man wanted to abstain from alcohol...
 104. After penicillin treatment child presented with generalised rash, mouth ulcers, fi etc....epidemolysis [bleep]
 105. maculopapular rash in child etc ...kawasaki
 106. Mother with one child with cystic fibrosis wants to know the chance of her other ch getting it one in every four child
 107. A woman eating in a restaurant presented with sudden oral oedema etc anaphlacti
 108. A man notice father presenting with weakness to one side etc ...stroke not sure if TIA v option too
 109. Baby presented with progressive deeneing jaundice, vomiting etc biliary atresia
 110. A woman presented with folate and iron deficiency....villous atrophy
 111. Another answer i chose as Vitamin B12.
 112. a woman with hypothyroidism , and pernicious anaemia etc what is the cause c pernicious anaemia.....intrinsic factor deficiency
 113. woman delivered baby at 26 weeks baby died at 19 days following birth.....perinatal d other options early neonatal, late neonatal, postnatal)
 114. An elderly woman presented with tiredness , microcytic anaemia and right ilia mass....ca caecum
 115. Answer i choose on monospot test
 116. haemodialysis *2
 117. plain abdominal x-ray for patient presented for signs and symptoms of abdominal obstruc
 118. A theme on vaginal bleed with answers such as BhCG, trans vaginal US etc
 119. About 2 sba asking treatment for DB
 120. A couple of CT head answers
 eme: Arrhythmia treatment

- a) adenosine
- b) DC
- c) Transthoracic pacing
- d) amidarone
- e) Digoxin
- f) amiodarone

1. SVT + HR 200...(adenosine)
2. VT with hypotension.... (Amidarone or DC)
3. AF with hypotension (DC)
4. Complete heart block in MIcardioversion OR Transthoracic pacing
5. irregular pulse etcdigoxin

Theme: Investigations of palpitations

- a. CXR
- b. TFTs
- c. ECG
- d. Echocardiogram
- e. 24 hrs ambulatory ECG

1. A woman develops lassitude, purulent sputum and palpitations over 24 hrs, pulse rate 81 ECG shows sinus rhythm.....CXR
2. A woman presented with wt loss over 12 months, she also noticed that she loses her te easily, regular heart rate etc..... TFT
3. elderly man frequent episodes of breathlessness ,irregular heartbeat, regular pulse at 60 ECG shows sinus rhythm24 hrs ambulatory ECG
4. 35 yrs old woman has woken up 5 times in the previous month with a feeling of thumping chest .On sitting up for about two minutes and taking a few deep breaths the sensation sul .ECG shows sinus rhythm.....Echocardiogram
5.?
6. SBA: a child who took grandmother medication with yellow tongue and vision side effi which drug etcdigoxin
7. SBA: An 83 year old lady, with 3 BP readings at three different intervals. What is the advice for her, to keep her BP normal?

- a. weight loss was
- b. ACEI
- c. beta blockers
- d. Furasemide
- e. thaizides

Chest medicine

Theme: Investigation of Acute Dyspnoea

- a. Peak expiratory flow
- b. CXR

c. CT of the chest
d.

8 A man presented to A&E with SOB of 3 days duration, coughing and using his salbutamol more frequently?.....Peak expiratory flow
9 A man presented to A&E with sudden sharp right sided chest pain and SOB with reduced entry on the right side.....CXR
10 An elderly woman brought to A&E by family presented with breathlessness, occasional etc with coarse crepitations at lung baseCXR
11 A woman returned from holiday developed sudden left sided chest pain and SOB.....CT of chest.
12?

Infectious Diseases

13 SBA: a man with TB n was asked how we can prevent the spread of infection? treat him urgently with Rifampicin

Oncology & palliative therapy

14 SBA: A patient on oral morphine for metastatic ca but unable to follow that regime ...what the next step in management?
...diamorphine subcutaneous infusion

Endocrinology

Theme: Investigation of neck mass

a. Ultrasound
b. FNAC

15 A man with swelling in midline of neck come out with protrusion of tongueinvestigations ..ultrasound (it is thyroglossal cyst) or FNAC
16 A child with a neck mass that transilluminates brightly... cystic hygroma... USS
17
18
19

20 SBA: Obese and DM .. Bigunide

21 SBA: A pregnant woman presented with signs of Kussmaul's breathing etc.....DKA

22 SBA: Patient coming in with hypercalcemia, what is the initial tx for his hypercalcemia fluids

Renal medicine

23 SBA: A person who takes Atenolol, Thiazides and another drug with calcium stones, who is responsible... hyperparathyroidism or drug induced
24 SBA. hypercholesterolemia and microalbuminuria.... Statins and ACE inhibitor
25 SBA: A lady with type 2 DM and proteinuria and cholesterol 5.7, (BMI = 22)

a. ACEI and sulfonylurea.
b. statins and metformin
c.
d.

26 SBA: a man with poor stream come with haematuria, dysuria, and temperature, weight loss, urethral discharge, causative organismE. coli.
27 SBA: pyelonephritis in pregnant.....cefotaxime or cefuroxime
nitrofurantoin Trimethoprim
28 40 yr old man with features of puffy face and all ... Membranous nephropathy
29 A child having diarrhoea with renal functions damaged? Haemolytic uremic syndrome..... GI

Theme: causes of dyspepsia

a. NSAID
b. Helicobacter
c. Corticosteroids
d. Barrett's oesophagus
e. Gastrinoma

Single most important aetiological factor

30 A young man with 3 months history of epigastric pain that smokes 20 cigarettes a day .. helicobacter pylori
31 Elderly woman with long standing back painNSAIDs
32 A woman with RA who is intolerant to NSAIDs....CORTICOSTEROIDS
33 A woman with primary hyperparathyroidism responding poorly to PPI ...gastrinoma
34 Elderly man with heartburn for many years with acid reflux....Barrett's oesophagus

Theme: causes of jaundice

- a. cholangitis
- b. sclerosing cholangitis
- c. hepatitis A
- d. hepatitis B
- e. biliary colic
- f. Acute cholecystitis

35 a pt. with pain in RUQ fever, anaemia jaundice..... sclerosing cholangitis

36 Lady with fever chills. abd pain and jaundice... Cholangitis

37 a lady with a temp of 37.1 deg, RUQ pain radiating to interscapular region and jaundice....

38 A px who complains of fever with rigors, abdominal pain and jaundice. He has abdominal tenderness ...

39

)(I 'm not sure about this one

Theme: Treatment of

- a. Sulfasalazine
- b. folic and iron
- c. b12 deficiency
- d. oral replacement of vit b12

39 granulomatous lesion in colon:sulfasalazine

40 villous atrophy/pt with folic and iron

41 .oral replacement of vit b12/intrinsic factor deficiency

42 .hypothyroidism with megaloblastic anemia/b12 deficiency

43

Surgery

Theme on breast Pathology

- a. fat necrosis
- b. fibroadenoma
- c. breast abscess
- d. Breast ca
- e. fibrocystic mass
- f. Paget's disease of nipple

39 After trauma...fat necrosis

40 20 mm smooth mobile mass ...fibroadenoma

41 pregnant woman with fluctuant swelling to breast...breast abscess

42 Breast ca ?

43

44 the lady who has a family history of CA and her other investigations were normal C
Tumour marker would be the answer

45 the lady with ca her CA125 were normal after treatment and now she comes for some kind
recurrence CA 125 Tumour marker

46 lady having undergone colorectal surgery with a BP of 60/40

bloodor IVF

47 There was a Q about a lady with 4 cm fluctuant swelling following colostomy and she
well.....???

48 patient presented for signs and symptoms of abdominal obstruction plain abdominal

49 An elderly woman presented with tiredness, microcytic anaemia and right iliac
mass....ca caecum

Urology

Theme: follow-up Ca prostate

- a. radionuclide bone scan
- b. serum calcium level
- c. PSA
- d.
- e. US scan of abdomen
- f.

50 An elderly man with ca prostate with severe back pain waking him up
nights.....radionuclide bone scan

51 Elderly man with ca prostate with confusion, thirst, abdominal pain and abnormal
ECG.....serum calcium level

52 Man with ca prostate on treatment comes for follow-upPSA

53 Man with ca prostate staht spread outside the capsule he has acute renal failure ..US sc abdomen

54??

Theme Diagnosis of Scrotal Swelling

- a. Hydrocele
- b. Varicocele
- c. Testicular tumour
- d. Strangulated hernia
- e. Inguino-scrotal hernia
- f. Epididymal cyst
- g. torsion of testis
- h. epididymo-orchitis

55 a man with painful swelling with dysuria ,frequency of micturition and tem 38 C...epidi orchitis

56 A young man with painless swelling one testis is 3 times the size of the other an tender...hydrocele or testicular tumour

57 .A man with painless 1 cm swelling to upper pole of right testis...epididymal cyst or cancer

58 Child presented with severe unilateral testicular pain of sudden onset...torsion of testis.

59 ...a testicular swelling..which disappears while lying down....Varicocele

60 a man with scrotal tenderness, no urethral discharge, Urine nitrates +, pus cells + organism?

E. coli

N gonorrhea

chlamydia..

61 SBA: A man was noted post hemicolectomy to have a drop of urine output from 40 ml mls..... check functioning of the catheter






report this post to a moderator (<http://www.rxpgonline.com/report/index.php?p=899343&h=3&u=>)

please rate this post (<http://www.rxpgonline.com/modules.php?name=usertools&file=pvote&vote=up&u=503349&s=70530&n=3&f=138&t=108126&p=899343>)

(<http://www.rxpgonline.com/modules.php?name=usertools&file=pvote&vote=down&u=503349&s=70530&n=3&f=138&t=108126&p=899343>)

Back to top

[Reply](#) (modules.php?name=Forums&file=posting&mode=reply&t=108126) [Quote](#) (modules.php?name=Forums&file=posting&mode=quote&p=899343) [Scrapbook](#) (<http://www.rxpgonline.com/modules.php?name=RxPGites&mode=scrapbook&uid=70530>) [PM](#) (modules.php?name=Private_Messages&file=index&mode=post&u=)

 **Syrian** (<http://www.rxpgonline.com/threads70530.html>)
(<http://www.rxpgonline.com/modules.php?name=Messenger&file=buddy&op=compose&to=Syrian>)
Titan
   
Posts: 124
Credits: 7019 (<http://www.rxpgonline.com/docs/credits>)

Fri May 21, 2010 10:40 pm (4 years ago) #4 (modules.php?name=Forums&file=viewpost&tid=108126)

August 2009

1- A diabetic patient with BP 128/85, presents with micralbuminuria.....what is the treatme

- a- Atenolol
- b- ACE-inhibitors..... (the answer ...)
- c- Ca- channel blockers
- d- Diuretics
- e-

2- Another SBA....a patient develops poor left ventricular function after MI.....what management?

- a- B-Blockers
- b- Ca-channel blockers
- c- ACE-inhibitors..... (the answer ...)
- d- Aspirin
- e- Clopidogrel

3- a man while working in the garden had an episode of syncope. By the time the GP reach patient about half an hour later , he is fine. Investigation?

a- ECG

- b. 24hr tape ECG monitoring (the answer ...)
- c. echocardiography
- d-Blood glucose

4-A patient with Angina pain.....what is next treatment option for his pain?

- a- B-blockers
- b- Morphine
- c- GTN..... (the answer ...)
- d- Statins
- e-

5- A patient with sweating and chest pain of more than 10 hours duration (i think...)..he h depression in leads II, III and aVF.....? What is the best management?

- a- Aspirin and LMWH..... (the answer ...) ..coz it a case of acute coronary syndrome...
- b- Clopidogrel
- c- Aspirin 300mg.tab
- d- Morphine and streptokinase
- e-

A theme on chest pain complicated after MI

- a- Acute pericarditis
- b- Dressler's syndrome (post-MI syndrome)
- c- Rupture of papillary muscle
- d- Left ventricular aneurysm
- e- Left atrial aneurysm
- f- Ventricular tachycardia
- g- Atrial fibrillation
- h- CCF
- i-

6- A patient presents with chest pain after some days of his MI attack...he has upward con of ST-segment on ECG.....(acute pericarditis)

7- A patient presents with chest pain which becomes worse on inspiration, after some days MI attack.....(Dressler's syndrome)....

8- A patient comes with systolic murmur and basal crepitations on auscultation MI.....(papillary muscle rupture...As its the case of post-MI -Mitral regurgitation

9- A patient with s/s ofpulmonary edema with raised JVP and ankle edema....(CCF)

10- Another scenariowas aboutVT or Left ventricular aneurysm.....(i think... don't remember.....)

Theme on some CVS problems

- a- Aortic stenosis
- b- Mitral regurgitation
- c- VSD
- d- Left ventricular aneurysm
- e- Mitral stenosis
- f- Ccf
- g-
- h-

11- A patient with systolic murmur presents with basal crackles (pulmonary edema).....(regrugiation)

12- A patient with Atrial fibrillation on warfarin treatment , has a diastolic murmur.....(stenosis)

13-another answer wasaortic stenosis

14-

Respiratory

15- A lady after hip replacement surgery, presents with sudden breathlessness and chest pain What would be the appropriate investigation?

- a- V/Q scan
- b- ECG
- c- Spiral CT-pulmonary angiogram..... (the answer ...)
- d- Echocardiography
- e-

16- A smoker presents with weight loss, breathlessness and chest pain.....

What is the most appropriate definite investigation?

- a- Pleural aspiration
- b- Bronchoscopy
- c- Pleural biopsy..... (the answer ...)
- d- CT -thorax
- e-

17- A patient with complains of breathlessness while playing football. He is other wise well , other time.....(so its the case of exercise-induced asthma)..

What is the definite investigation?

- a- ABGs
- b- Pulse oximetry
- c- PFTs (Pulmonary function tests)..... (the answer ...)
- d- CXR
- e- Echo

A theme on.....treatment of infections

- a- Metronidazole
- b- Amoxicillin
- c- Clarithromycin
- d- Co-triamoxazole (High-dose)
- e- Tetra-cycline
- f- Cephalosporins
- g- Vancomycin
- h-
- i-

18-HIV patient with pneumonia.....(co-trimoxazole-high dose)

19-pneumonia...with MRSA.....(vancomysin).....I am not sure about scenario...

20-
21-

A theme on diagnosing organisms responsible for pneumonia
a- Pneumococcus
b- Staph. Aureus
c- Mycoplasma pneumoniae
d- Legionella
e- Pseudomonas
f- Pneumocystis jiroveci
g-
h-

22- A patient with fever, chest pain.....he had corysal infection one week ago...
(Staph.aureus)
23-a patient with fever and lobar consolidation on x-rays.....(pneumococcus)
24-(mycoplasma).....
25-

GIT
A theme on GI.Bleeding
a- Barium swallow
b- Oesophagoduodenoscopy (OGD)
c- H-pylori Eradication
d- H-pylori tests
e- Serum gastrin
f- Omeprazole-oral
g- Omeprazole- IV
h- Partial gastrectomy
i- CT abdomen
j-

26- A diagnosed case of adenocarcinoma of stomach..answer was..(CT abdomen)..to check
metastasis ...for its staging
27-A patient with Nsaid induced bleeding ,now stable with IV omeprazole...(OGD)
28-(Gastrin Levels)
29-A patient with H/O burnshas ulcers in esophagus, stomach
duodenum.....(IV omeprazole)
30-

31-a SBAabout the diagnosis of Haemochromatosis.....

32-A patient with severe itching and deranged LFTs.....diagnosis of Primary I
cirrhosis

Heamatology

33- Woman who is anaemic with Hb 6.4. macrocytic anaemia w/ MCV of 103 and cl
constipation and features of hypothyroidism
a) Folate def.
b) Vit.B12 def. (the answer ...)
c) Myelodysplasia
d) Haemolysis
e)
34- A pregnant lady comes with anemia.....with s/s of iron def. Anemia....
What would you advise her?
a- IV. Folate
b- Tab. Folate (2*TDS)..... (the answer ...)
c- Thiamine
d-
e-
35- A patient who has been treated for his leukemia in the hospital, now develops varicella :
rash.....
What you would do next?
a- Treat all the pregnant females in the ward.
b- Treat all the female medical staff in the ward
c- Treat all the pregnant females who have negative antibodies for VZ... (the answer ...)
d-
e- None of the above
36- A patient who is already on warfarin is planned for abdominal surgery.....
What would you do next?
a- Continue warfarin and start heparin
b- Stop warfarin and start heparin..... (the answer ...)..i think,.but i am not sure...
c- Stop warfarin and start aspirin
d- Continue warfarin as such
e-
37- A patient with DVT is taking anticoagulants(e.g. Warfarin).....
what is his cut off INR limit?
a- <1
b- 1-2.....
c- 2-3 (the answer ...)...
d- 3-4
e- >4

A theme on..... investigating..Anemia(pallor).....Haematology
a- Blood film
b- Bone marrow examination
c- Serum B12
d- Serum folate
e- Shilling test
f- Serum iron and serum ferritin
g-
h-
What is the most definite ...next... investigation?

38- A patient with pallor who has blast cells on blood film, you want to confirm anemia.....Ans is(Bone marrow exam....as it is the case of leukemia)
39- A patient with anemia , having MCV 70fL (normal : 76-96fL).....Ans is ...(serum iron and ferritin)....as its the case of iron def. Anemia (a microcytic anemia as mcv is low)
40-
41-
42-

A theme ondiagnosing...bleeding diathesis
a- Warfarin overdosage
b- Waganer's granulomatosis
c- Hypertensive crisis
d- Haemophilia
e- Idiopathic thrombocytopenic purpura
f- Osler -weber Rendau syndrome
g-
h-
i-

43- A patient with atrial fibrillationon warfarin presents with epistaxis....his INR is (warfarin overdosage).
44- A patient presents with bleeding from his nose, breathlessness and haematuria..(Wegener's)
45-
46-
47-

Endocrinology & Acid base -balance

48- A diabetic patient comes to emergency in a state of confusion, hyperventilating,....jerky movements of his limbs....His blood glucose is 2.5mmol/L.
What would you do next?
a- 0.9% saline IV
b- 5% dextrose IV
c- Insulin IV
d- 50% dextrose IV..... (the answer ...)..as its the case of Hypoglycemia
e-
49- A diabetic patient comes with h/o polyuria, polydipsia, hyperventilating,His blood glucose is 30mmol/L.
What is the next step in management?
a- IV insulin
b- 0.9% saline IV. (the answer ...)..as its the case of DKA.
c- Metformin
d-
e-
50- A patient with confusion, weakness and lethargy. He is diagnosed as a case of small cell carcinoma of lung....(i don't remember whether , it was squamous or small cell).....
which electrolyte abnormality seen?
a- Hypercalcemia.....if squamous cell ca...due to secretion of parathyroid hormone like peptides....
(Reference : Davidson's 20th edition: p707)
b- Hyponatremia.....I answered this one ...as in the case of small cell ca of lungs...hypercalcemic alkalosis (due to raised ACTH levels)occurs...so hyponatremia occurs secondarily
c- Hyperglycemia.....it also occurs in small cell ca of lungs (raised ACTH levels)
d- Hyperkalemia
e- Hypermagnesemia
51- A patient with polyuria and polydipsia, lethargy and weakness ,secondary to a malignancy
What is next step in management?
a- Bisphosphonates
b- IV fluid
c- Insulin
d- Fluid restriction
e- Dexamethasone
52-another SBA was about calcium metabolism.....(if anybody knows about this ...do tell me...thanks)
Options were:
a- Calcitonin
b- Calcium resonium
c-
d-
e-
53- A female patient with complaints of diarrhoea ,wt. loss, sweating....she also has lid-lag..

Which investigation preferred?

- a- Endoscopy
- b- Blood glucose levels
- c- Thyroid function tests..... (the answer ...).....as its the case of Grave's disease.
- d- ECG
- e-
- 54-A SBAaboutAcromegaly
- 55-a SBAabout very low sodiumnext investigation?.....Ans...Repeat sample
- 56-A SBAabout hypoglycaemia
- 57-another SBAabout Hyperthyroidism.....

A theme of management of ...Electrolyte imbalances

- a- IV. Insulin
- b- Subcutaneous insulin
- c- I.V. 0.9% saline with steroids
- d- I.V. 0.9% saline with insulin
- e- Oral potassium
- f- IV saline with potassium
- g- Dialysis
- h- IV saline only
- i- IV steroids only

Choose the most appropriate management options from above:

58- . a young man presents with nausea and vomiting weight loss/ or gain.. investigations show:

NA 129
K 5.2
UREA 12
GLUCOSE 4

Ans: IV. n saline plus steroids... as its the case of adrenal insufficiency

59- young man with weight loss, thirst and urinary frequency

NA 148
K 5.2
UREA 12
GLUCOSE 30

Ans: IV 0.9% saline with insulin.....As its the case of hyperglycemia

60- 20 yr old man involved in RTA suffers multiple fractures and crush injuries.4 days later anuric with pulmonary oedema is

NA 150
K 7.7
UREA 60

Ans:dialysis.....b.coz K levels are above 7 in a case of ARF (acute renal failure)

61- 50 year man has had admitted for investigation breathlessness and weight loss.he has taking a thiazide diuretic for raised blood pressure for 2 years.His blood pressure is 150/100

NA 138
K 2.9
UREA 5.8

Ans:potassium orally.... as its the case of Diuretic induced Hypokalemia...

62- an 8 YR OLD boy with gastroenteritis gave a 2 day history of profuse diarrhoea and vomit

NA 148
K 2.2
UREA 20

Ans:I.V.n .saline plus potassium....as its the case of diarrhoea induced hypokalemia.

63- Another SBA about.....galactorea.,amenorrhoea, and infertility.....

Which investigation?

- a- TFTs
- b- Serum cortisol
- c- Serum prolactin... (the answer ...)
- d- ...
- e-

64- Another similar SBA about.....a patient on haloperidol...which investigation?

- a-
- b-
- c- Serum prolactin.... (the answer ...)
- d-
- e-

65- Another SBA ...about metabolic disturbance...i think)..about metabolic alkalosis

What is the interpretation?

- a- High plasma osmolality, low pH and high urine osmolality
- b- High plasma osmolality, high pH and low urine osmolality
- c-
- d-
- e-

Renal medicine
 A theme on.....Haematuria
 Options were
 a- Bladder Ca
 b- Ca of kidneys
 c- Renal TB
 d- Polycystic kidney disease
 e- Ureteric Calculi
 f- Renal Calculi
 g- Prostate Ca

66-
 67-
 68-
 69-
 70-

A theme onGlomerulo-nephritis
 a- Acute glomerulonephritis (Post-streptococcal)
 b- Minimal change disease
 c- Membranous GN
 d-

71-
 72-
 73-

Rheumatology

A theme ondisgnosis of connective tissues disorders & Joint diseases
 Options were:
 a- Anti-mitochondrial antibodies
 b- Anti-centromere antibodies
 c- Anti-thyroid antibodies
 d- Anti-DS-DNA antibodies
 e-
 f-

74-
 75-
 76-
 77-
 78-

79-A SBA on.....SLE disgnosis.....

80-A patient has diplopia when he looks up.....

Which investigation?

a-
 b- ...Tensilon test(the answer).....As its the myasthenia Gravis.....

Neurology

81- A patient who has been treated for meningitis....he is going to be discharged ..
 What investigation , you would do before discharging him?

a- Audiometry..... (the answer).I think
 b- MRI brain
 c- CT brain
 d- Ear drum examination
 e- LP

82- old lady with atrial fibrillation on warfarin falls and hurts her head with haematoma a
 orbit.....

What investigation?.....

a- INR
 b- ct scan of head
 c-
 d-
 e-

83- Which medicine to be given in the treat ment of meningitis?

a- Ampicillin
 b- Cefotaxime..... (the answer)
 c- Tetracycline
 d-
 e-

A theme onHeadaches

a- Migraine
 b- Trigeminal neuralgia
 c- Post-herpetic neuralgia

- d- Cluster headache
- e- Tension headache
- f- Cranial arteritis
- g-
- h-
- i-

84- A patient feels very severe cutting pain on the side of his face.....trigeminal neuralgia
85- An old man feels pain along the course of VII cranial nerve , i.e. around the eyes, forehead...he has also been suffering previously from shingles..(Varicella Z infection).....Post-herpetic neuralgia
86- ..pain in scalp..esp. during combing hairs....high ESR.....Cranial arteritis (Giant arteritis)
87- ...pain in one side of head..esp. during every morning.....eyes drooping.....Cluster headache
88-

89- ...a SBA ...about absence seizure in a child.....which investigation?...Ans...EEG
90- ...a SBA ...about febrile seizures in a child....which investigation?...answer...Just reassure
91- A SBA... about paraplegia, ...in a patient with metastatic cancer....answer...spinal cord compression

Infectious Diseases

92-An african homosexual person had sex with other homosexual.....
What would be next investigation?
a-
b- ..Treponema antigen and treponema antibodies..... (the answer ...)
c- Lyme serology
d- Treponema antigens only

Palliative treatment

93-A patient with chronic malignancy has been on....paracetamol and ibuprofen...his pain is still not gone....what is the next step in management?
a- Morphine
b- Diamorphine
c- Codeine..... (the answer ...)
d- Tramadol
e-

Surgery - 27th august 2009

94- A patient with some malignancy presents with supra-clavicular node palpable ..(Virchow's node).....what's diagnosis?
a- Ca -right main bronchus
b- Ca- left main bronchus
c- Gastric carcinoma..... (the answer ...).....as it is palpable in abdominal malignancy...
d-
e-
95- A patient with cholecystitis and colicky abdominal pain..and jaundice...his USG confirms there is a stone in the duodenum....where is the stone present ?
a- Common bile duct
b- Pancreatic duct
c- Ampulla of Hartmann's....I don't think..it was ampulla of Vater...however ...i answered this incorrectly
d- Gall bladder
e-
96- A patient has indirect inguinal hernia...which is the anatomical landmark...which differentiates the indirect inguinal hernia from the direct one....?
a- Superficial inguinal ring
b- Deep inguinal ring..... (the answer).....
c- Pubic tubercle.....
d- Mid-point of inguinal ligament
e-
97- A patient has a testicular swelling...which only appears during standing....
What is it?
a- Hydrocele
b- Varicocele.... (the answer).....
c- Inguinal hernia
d- Epididymal cysts
e-
[snip]- A patient has undergone hemicolectomy...his BP is gone down to 70/40 and pulse below 60 after 3 hours of the operation....what would be next immediate step?
a- USG abdomen
b- Colonoscopy
c- IV fluids..... (the answer).....i think...
d-
e- Laparotomy
99- A patient with H/O atrial fibrillation...comes with severe abdominal pain with blood in stool and diarrhoea.....

What is the cause?

a-

b-

c- Ischemia of the gut following the embolism in the mesenteric vessels... (the answer).... its the case of ischemic colitis

d-

e-

100- A person jumped from air with parachute and hit the ground...he feels severe pain left side of his chest...On examination, trachea is shifted to the right and breath sound muffled on the left side of his chest...

What is the diagnosis?

a- Hemopneumothorax

b- Tension pneumothorax..... (the answer).....

c- Splenic rupture

d- Pleurisy

e- Lung collapse

101- A elderly man...with weight loss and anemia...HB=6....and abdominal pain

Which investigation?

a- Barium enema

b- Colonoscopy..... (the answer).....As its the case of Colo-rectal carcinoma

c- Sigmoidoscopy

d-

e-

102- An elderly female complains ofh/o chronic constipation...there is fecal impaction rectum on PR examination...what is next step in management?

a- USG abdomen

b- Laxatives

c- Enema..... (the answer).....

d- Colonoscopy

e-

A theme oninguino-scrotal swellings....

Options were:

a- Inguinal hernia

b- Inguino-scrotal hernia

c- Femoral hernia

d- Femoral artery aneurysm

e-

f-

103- A patient with swellinglateral and below the pubic tubercle.....Femoral hernia

104- Swelling.....medial and superior to the pubic tubercle.....inguino-scrotal hernia

105- ..another question ...was about swelling ...felt on lateral and above the inguinal ligament (I could not understand this question)...can any body recall the exact question and..als answer.....

106-

107-

A themeon scrotal swelling

Options were:

a- Hydrocele

b- Varicocele

c- Testicular tumor

d- Strangulated hernia

e- Inguino-scrotal hernia

f- Epididymal cysts

108- ...a testicular swelling..which disappears while lying down...Varicocele

109- A hard testicular swelling in a young patient.....testicular tumour

110-A large unilateral testicular swelling...testis cannot be felt.....(hydrocele think...some ppl say ..it is the epididymal cysts...)....but in epididymal cyst, you can palpate testis separately...but not in hydrocele..so its the hydrocele.

111-

112-

113-

A theme on.....chest pain (related to injuries)

a- Tension pneumothorax

b- Hemopneumothorax

c- Flail chest

d- Splenic rupture

e- Diaphragmatic rupture

f- Traumatic rupture of aorta

114- A patient ...in whom.... bowel sounds can be heard in the auscultation....Diaphragmatic rupture

115-severe left hypochondrial pain after motorbike injury....pt. is in shock....s rupture

116- ...a question.....answer wastension pneumothorax

117-a patient with severe central chest pain ...going to back...CXR shows widening mediastinum.....Aortic rupture

An other themeon treatment options on..surgical patients

a-

b- Needle thoracocentesis

c-

d-

e-

- 118- A patient with...H/O...tension pneumothorax.....ans....(needle thoracocentesis)
 119-
 120-

Anatomy

A theme onskull bones (bone identification related to fractures)

- a- Mandibular bone
- b- Maxillary
- c- Temporal
- d- Sphenoid
- e- Frontal
- f- Occipital
- g- Parietal
- h-
- i-

- 121- A boxer receives a blow on his cheeks ...which get bruises with injury.....(ma bone)
 122- A fracture involving the external auditory canal (temporal bone)
 123- A fracture on the side of scalp behind the coronal suture(parietal bone)
 124- A fracture of bone where pituitary gland is present.....(sphenoid)
 125- A bone on the back of head.....exact question is not remembered...(occipital)

A theme onvenous drainage of the body
 (which specific vein is involved?)

- a- Subclavian vein
- b- Axillary vein
- c- Long saphenous vein
- d- Small saphenous vein
- e- Popliteal vein
- f- Femoral vein
- g- External iliac vein
- h- Superior vena cava
- i- Inferior vena cava

Different scenarios////////.....for example.....

- 126- Swelling in calf.....(popliteal vein)
 127- Edema in lower leg below knee.....
 128-
 129-
 130-

Gynae & Obs .

131- A female comes with intermittent vaginal bleeding. When viewed, her cervix appears and bleeds on touching.... which investigation?

- a- Cervical biopsy (the answer... I think)
- b- Cervical smear
- c- Colposcopy
- d- USg
- e-

132- A female patient comes with s/s of PID (pelvic inflammatory disease). E.g. Vaginal discharge, fever, lower abdominal pain.....

Which is the definite investigation?

- a- High vaginal swab
- b- Endocervical swab (the answer ...)
- c- Hysterosalpingogram
- d- Colposcopy
- e- Blood culture

133- A patient on Depo-provera, she has h/o of 9-months amenorrhea, now she is concerned about her vaginal bleeding?

- a- Give her OCP (the answer ... I think ... but im not sure)
- b- Give her POP
- c- Just Reassure
- d-
- e-

134- Which lymph nodes are to be involved in carcinoma fundus of uterus....?

- a- External iliac
- b- Internal iliac
- c- Inguinal
- d- Para-aortic (the answer ...but not sure...)
- e-

135- A 74 years old lady presents with h/o dysuria.... which treatment would you recommend?

- a- NSAIDs
- b- Vaginal estrogens ... (the answer... as its the post-menopausal symptom)
- c- Antibiotics
- d-
- e-

136- A lady presents with s/s of stress incontinence which treatment you would suggest?

- a-
- b- Pelvic floor exercise ... (the answer ...)

c-
d-
e-

137- A female comes with bulging mass per vagina and cervix, when examined vaginally..... the exact question ... I don't remember ... which could be that viscera which is being felt on manual examination vaginally?

a- Small intestine
b- Rectum (the answer... I think)
c- Bladder
d- Cecum
e-

138- A patient with pre-eclampsia comes with h/o fits...she also has BP 160/90 microalbuminuria...what would you do next?

a- Methyl-dopa
b- Magnesium sulphate (the answer... I think)
c-
d-
e-

139- A male patient with h/o azoospermia ... which investigation?

a- FSH
b- LH
c- MSU
d- ...
e-

140- A new-baby comes with jaundice 4-weeks after birth...

What next management option?

a- Stop breast feeding
b- Continue breast feeding ... (the answer... I think ...as its physiological jaundice)
c- Coombs' test
d- Anti-D immunoglobulins
e- ,.....

141- A pregnant female comes with BP 160/110 with fits. Her abdominal auscultation reveals fetal heart sounds... what next management?

a- Magnesium sulphate
b- Deliver the baby.. (the answer... I think) as the fetus is dead....
c- Labetalol
d- ...
e-

142- Another SBA about pre-eclampsia and Eclampsia....

143- ...another SBS ...about endocrinological problem in a female ..probably was sheehan's syndrome.... which investigation?

a- High FSH: Low LH
b- Low FSH: High LH
c- Low FSH: Low LH
d- High FSH: High LH
e- None of the above

A theme onAnte-partum Haemorrhage

Options were:

a- Placenta accreta
b- Atonic uterus
c-

144-
145-
146-
147-
148-

Paediatrics

149- A baby became suddenly unwell with increased respiratory rate, raised pulse, drool saliva and fever. By the time, mother comes and the baby becomes alright. What next investigation?

a- FBC
b- Blood Culture
c- Urine Drug screen... (the answer... I think)..its a case of poisoning
d- No investigation
e-
150-

a theme on Diarrhoea in infants

a- IV saline
b- ORS (oral rehydrated salt)
c- 0.9% saline 20ml/kg IV bolus
d- continue normal diet and reassure.....
e- IV fluids slow

151- An infant with s/s of mild dehydration only....dry mucous membranes but good skinAns is ORS

152- An infant with dry membranes, drowsiness, decreased skin turgor...(ans. Is IV

bolus.....as its more than 10% dehydration)
 153- A baby girl has got diarrhoea 10 days ago, now presents with his mother who is conc about his status...baby has moist mucous membranes.....(Reassure)
 154-

A theme on.... respiratory infections in babies
 a- Acute bronchitis
 b- Acute laryngo-tracheo-bronchitis
 c- Respiratory syncytial virus infection
 d-Asthma
 e-
 f-
 g-

155-
 156-
 157-
 158-

Psychiatry

159- A female with h/o anxiety, palpitations, and having stable loving relationships wi boyfriend (according to her) and she also takes some times alcohol.
 Which next immediate investigations ?

a- Collateral history
 b- GGT
 c- Urea & Electrolytes
 d- Echo
 e- TFTs (Thyroid function tests) (the Answer)

Ans : I picked TFTs

160- A patient with signs/symptoms of schizophrenia presents to you. Agitated and h/o th block and passivity phenomenon....

Which drug to be chosen ?

a- Amitryptiline
 b- SSRIs
 c- Lorazepam
 d-
 e- Olanzapine..... (the answer ...)...No doubt

161- A female with s/s of severe depression, still presents with no improvement even after anti-depressants. What is the next step in management?

a- Cognitive behaviour therapy
 b- Lorazepam
 c- ECT (the Answer)
 d- Litium
 e-

162- A patient came to A & E after taking 10 tablets of paracetamol. He is refusing to tak treatment.

What you will do next ?

a- Discharge the patient
 b- Treat him (the Answer)
 c- Refer to psychologist
 d- Assess his capacity to refuse the treatment
 e-

163- You are going to start Lithium for a patient.
 Which investigation is important here?

a- TFTs
 b- Urea and Electrolytes.... (the answer)
 c- FBC
 d- ...
 e-

A theme about Anxiety related problems

a- Panic disorder
 b- Agoraphobia
 c- Social phobia
 d- Adjustment disorder
 e- Obsessive Compulsive Disorder
 f- Specific phobia
 g- Post-traumatic stress-Disorder (PTS-D)
 h-

Choose the disgnosis....

164- A lady feels anxiety and uncomfortable whenever she goes out of home. She is comfo while in her home..... (Agoraphobia)

165- A lady complains of lack of appetite and interest after her mother died in a disaster complains of palpitations and anxiety after that. She also fears that this would not happen again (I picked specific phobia ... but i think ... correst answer was adjustment-disord don't know)

166- A patient with cleaning ritual (always cleaning and washing his hands) ..he was a performer in the school (OCD... no doubt)

167- A person don't go outside the home because he thinks that people will look at him and about him (I picked Agoraphobia again but i think correct answer was ...social phob

Delusional disorders

- a- Delusion of doubles
- b- Persecutory delusion
- c- Grandiose delusion
- d- Erotomania
- e- Nihilistic delusion
- f-
- g-

168- A female who claims that she is in love with some celebrity and she also receives letters from that celebrity (Erotomania)

169- A female who claims that she have seen a person who resembles her husband and who in the other room of her home..... (delusion of Doubles ...).. its the Capgras syndrome.

170- Another theme which I don't remember it was probably about Nihilistic delusion

171-another was about Persecutory delusion.

172-

Drugs and Alcoholic Addiction

- a- Chlordiazepoxide
- b- Methadone
- c- Disulfiram
- d- Lorazepam
- e- Naloxone
- f-
- g-
- h-

173- An alcoholic patient who is willing to leave alcohol and wants your help.....(Disulfiram

174- Treatment of withdrawal signs of Alcohol.... Chlordiazepoxide

175- Treating a patient who has signs of opiate addiction..... Methadone

176-

177-

Dermatology

178- A lady comes with scaly lesions on her body. Her aunt also had the same silvery scales on extensor surfaces of her elbows, knees, scalp.....

What is the diagnosis?

- a- Eczema
- b- Impetigo
- c- Lichen planus
- d- Psoriasis..... (the Answer)
- e- Scabies

179- A patient who is already taking doxycycline comes to you and complains of nausea and vomiting....

What you would do next?

- a- Advise him anti-emetic
- b- Advise him Antacid
- c- Advise him to take doxy..after the meal
- d- Advise him to take doxycycline before the meal(the Answer)... i think..
- e-

180- An African man comes with h/o breathlessness. He has some lesions on the front of his legs below his knees ...

What diagnosis?

- a- Erythema multiforme
- b- Erythema Nodosum.... (the Answer)
- c- Acanthosis nigricans
- d- ...
- e-

181- An ulcerated nodule on the side of the nose in a white man.... it has also some (0.1 cm) depression in the nodule.....(i don't remember the exact question..)

What is diagnosis?

- a- Squamous cell carcinoma
- b- Basal cell carcinoma..... (the Answer)
- c- Melanoma
- d-
- e-

Eye

182- Red eye in a patient having ankylosing spondylitis.....

- a- Conjunctivitis
- b- Scleritis
- c- Episcleritis
- d- Iritis..... (the Answer)
- e- Keratitis

183-A patient who has developed gradually deteriorating blindness...He has absent corneal reflex...what's the diagnosis?

- a- Acute angle closure glaucoma
- b- Retinal detachment
- c- Cataract.. (the answer ...)

d- Myopia
e-

..... a theme on eye problems

Options were:

- a- hypertensive retinopathy
- b- macular degeneration
- c- diabetic retinopathy
- d- acute angle closure glaucoma

184-
185-
186-
187-
188-

ENT

189- A patient comes with conductive deafness....he has some wax in his external auditory after....

what next step in management?

- a- Antibiotics
- b- Clear his ear with suction..... (the Answer) ..but im not sure
- c-
- d-
- e-

190- A patient comes with dysphagia due to oesophageal carcinoma.....what i management?

- a- Barium swallow
- b-
- c- Radiotherapy
- d- Chemotherapy
- e- Stent insertion..... (the Answer)

191- A patient with inspiratory and expiratory stridor.....(Laryngeal carcinoma) a theme on ear problems

- a- Adenoidectomy
- b- Myringotomy with grommet insertion
- c- Stapedectomy
- d- Tympanoplasty
- e- Hearing Aid
- f- Cochlear Implant
- g-

192-
193-
194-
195-
196-

Miscellaneous themes



197-A SBA ...about a patient with.burns.....

198-a SBA about Gullian bari syndrome..... Intubation...





1. FIRST QUESTION WITH A WOMEN WITH VAGINAL BLEEDING WHILE EXAMINATION (BIOPSY)
2. WOMEN WITH PALPITATIONS TREMORS AND ANXIETY FEATURES RELIEVED BY ALCOHOL (TH FUNCTION TESTS)
3. A PT. WITH INSPIRATORY AND EXPIRATORY STRIDER (THYROID CANCER)
4. ONE MORE QUESTION ON DIAGNOSIS OF HYPERTHYROIDISM.
5. ABSENT RED REFLUX (CATARACT)
6. DIAGNOSIS DIABETIC RETINOPATHY.
7. MACULAR DEGENERATION WITH DRUSEN
8. AGAROPHOBIA
9. DOUBLE DELUSION
10. ERATOMANIA
11. GRANDEOUS DELUSION
12. DELUSION OF REFERENCE
13. DELUSION OF GUILT.
14. DIAGNOSIS OF CARDIAC TEMPONADE 2 TIMES
15. TENSION PNEUMOTHORAX DIAGNOSIS
16. THEN ONE MORE ON TENSION PNEUMOTHORAX ASKING NEEDLE THORACOTOMY
17. PLEURAL EFFUSION ASKING DEFINITIVE TEST (BIOPSY)
18. ACUTE PERICARDITIS
19. DRESSLERS SYNDROME
20. VENTRICAL ANEURISM
21. PT. ON DEPOVERA, AMENORRHEA FOR 9 MONTHS (GIVE OCP)
22. DIAGNOSIS OF PANCOST TUMOR WITH HORNRES SYNDROME
23. PAINLESS HEMATURIA (BLADDER CANCER)
24. MINIMAL CHANGE DISEASE
25. MEMBRANOUS DISEASE
26. ACUTE GLOMERULONEPHRITIS
27. PUNCH ON FACE (MAXILLA)
28. BLEEDING FROM EAR (TEMPORAL BONE)
29. SPHENOID BONE




30. PT CHANGED RING FROM FROM RING FINGER TO LITTLE FINGER (ACROMAGALY)
31. ADDISON'S DISEASE (ASKING TREAT. FLUIDS WITH HYDROCORTISONE)
32. HYPOKALEMIA
33. METABOLIC ALKOLOSIS INTERPRETATION
34. FEMORAL HERNIA
35. INGUINAL HERNIA
36. INGUINAL HERNIA AGAIN
37. DEEP INGUINAL RING
38. TESTICULAR TUMOR
39. HYDROCELE
40. 0.9 % SALINE IN DKA TREATMENT
41. ABGS IN DKA INVESTIGATION
42. VERY LOW SODIUM (REPEAT SAMPLE)
43. INDIRECT BILIRUBIN FOR HEMOLYSIS
44. CEFOTAXIME
45. DOXYCYCLIN SIDE EFFECTS (I GAVE ANTI EMETIC PROBABLY WRONG...SHOULD BE GIVEN , MEALS I THINK)
46. STOP WARFARIN AND START HEPARIN BEFORE SURGERY
47. ASPIRIN AND DYPYRIDAMOLE FOR TIA PT.
48. INR 2-3
49. EPIXTAXIS WITH WARFARIN OVERDOSE
50. I PICKED CT FOR 2 TIMES BUT COULD NOT REMEMBER THE SCENARIO
51. PARITAL BONE
52. SERUM PROTEIN ELECTROPHORASIS FOR MULTIPLE MYELOMA
53. WEGNER'S GRANULOMATOSIS
54. DIC WITH ABRUPTION
55. MAGNESIUM SULPHATE FOR ECLAMPTIC FIT AFTER DELIVERY
56. MAGNESIUM SULPHATE FOR SEVER PREECLAMPSIA
57. DELIVER OF A DEAD FETUS
58. PARACETAMOL POSINING (TREAT WITHOUT CONSENT)
59. RECTOCELE ASKING RECTUM
60. PELVIC FLOOR EXERCISES FOR STRESS INCONTINENCE
61. ANTI MITROCHONDRIAL ANTIBODIES
62. ANTI CENTROMERE ANTIBODIES
63. ANTI THYROID ANTIBODIES
64. ANTI ENDOMYSIAL ANTIBODIES
65. ANTI DSDNA ANTIBODIES
66. DIAGNOSIS FOR PRIMARY BILIARY CIRRHOSIS IN A PT WITH SEVERE ITCHING AND DEARRA LFTS
67. PT. ON HALOPERIDOL (PROLACTIN LEVEL)
68. UREA AND ELECTROLYTES FOR LITHIUM TO BE STARTED
69. TURNERS WITH PRIMARY AMENORRHEA (HIGH FSH AND LH)
70. TESTICULAR FEMINIZATION SYNDROME (HIGH TESTESTERONE)
71. RAISED FSH/LH RATIO FOR PCO
72. VAGINAL ESTROGEN FOR AN ELDERLY FEMALE WITH DYSURIA
73. TRIGEMINAL NEURALGIA
74. POST HERPITIC NEURALGIA
75. CLUSTER HEADACHE
76. VARICELLA ZOSTER IMMUNIZATION (ALL PREGNANT LADIES WHO HAVE NEGATIVE ANTIBOD VZ)
77. FAECAL IMPACTION (GIVE ENEMA)
78. OSTEOPOROSIS PREVENTION FOR TEMPORAL ARTERITIS PT. ON STEROID (BISPHOSPHONATES)
79. THEN AGAIN A DIAGNOSIS OF CRANIAL ARTERITIS
80. TB NECK
81. RENAL TB
82. MITRAL REGURG WITH PAPILLARY MUSCLE RUPTURE
83. OCD DIAGNOSIS
84. OLANZAPINE FOR A SCHIZOPRENIC PT.
85. ADJUSTMENT DISORDER DIAGNOSIS IN WHICH THE PT IS HAVING ANXIETY AFTER THE DEATH OF HER MOTHER
86. ENDOCERVICAL SAMPLE IN PID
87. LONG SEPHANOUS VEIN
88. SHORT SEPHANOUS VEIN
89. INTENAL ILIAC VEIN
90. PARA AORTIC LYMPH NODES
91. RCV DIAGNOSIS
92. BREAST ABSCESS (STAPH AUREUS)
93. MENINGITIS
94. AUDIOMETRY
95. VIT B 12
96. THEN PERNICIOUS ANEMIA
97. GASTRIN LEVEL
- [snip]. IV OMEPRAZOLE FOR BURNS PT.
99. BARRETT'S ESOPHAGUS
100. STENT FOR DYSPHAGIA IN ESOPHAGUS CANCER
101. GASTRIC CARCINOMA PARTIAL GASTRECTOMY
102. MSU FOR A UTI CASE
103. FEBRILE SEIZURES (NO TEST JUST REASSURE)
104. DIARRHOEA 10 DAYS AGO NOW OK (REASSURE)
105. ERYTHMA NODOSUM WITH SARCOIDOSIS CASE
106. IRITIS WITH ANKYLOSING SPONDYLITIS
107. THIAMINE FOR ALCOHOLIC
108. THEN AGAIN ASKED THIAMINE AS B COMPLEX VITAMIN
109. FLAIL CHEST WITH PARADOXICAL BREATHING

110. BONE MARROW EXAM FOR LEUKEMIA
111. STONE IN AMPULA OF VATER
112. AXILLARY VEIN
113. PRIMARY HYPERTHYROIDISM
114. URETERIC CALCULI
115. TRAMADOL...SOME GIVE CODIEN...OHCM SAYS BOTH...I M CONFUSED.
116. FANTANYL PATCH
117. LYME SEROLOGY
118. TENSOLIN TEST FOR A PT WHO HAS DIPLOPIA WHEN HE LOOK UP...(MYSTHENIA GRAVIS)
119. EEG IN A ABSENSE SEIZERS KID
120. SHEEHANS ASKING LOW FSH AND LH
121. GGT IN ALCOHOLIC
122. ECT IN DEPRESSION
123. ANTIPLATELETS AND HEPARIN IN IHD PT.
124. ECHOCARDIOGRAM IN A PT WHO HAS SYNCOPES IN HIS GARDEN...SOME PICKED ECG THINK THAT'S RITE
125. SWELLING IN CALF MUSCLES (POPLITAL VEIN)
126. SPINAL CORD COMPRESSION IN A METASTATIC CANCER PT.
127. PREVIOUS URTI NOW HAS FACIAL PAIN (SINUSITIS)
128. FEMORAL ARTERY ANEURISM
129. BARRIUM SWALLOW IN DYSPHAGIA PROBABLY ACHALASIA
130. CONTINUE BREAST FEEDING
131. VAGINAL LACERATION IN A PT. WHO DID NOT HAVE EPIOSTOMY
132. LAX UTERUS 2 TIMES
133. UTERINE RUPTURE WITH PREVIOUS LSCS
134. SOCIAL PHOBIA
135. CERVICAL SMEAR
136. CCF ..BREATHLESSNESS NOT RESPONDING TO OXYGEN..(DIURETICS)
137. PT STARTED ON OCP...THEN HAVING MIGRAINE ASKING FOR INVESTIGATION (I P NONE....PROBABLY WRONG)
138. YOUNG FEMALE WITH BLINDNESS (DIABETIC RETINOPATHY)
139. OCCIPITAL BONE
140. HYPOGLYCEMIA (BLOOD SUGAR)
141. ADMIT AND OBSERVE A PREECLAMPSIA CASE
142. WHOOPING COUGH (PERTUSSIS)
143. HEMOPNEUMOTHORAX DIAGNOSIS
144. AZOSPERMIA (FSH)
145. BASAL CELL CARCINOMA
146. INTUBATION IN A GULLIAN BARE PT.
147. ITP DIAGNOSIS
148. PSORIASIS WITH FAMILY HISTORY
149. DILUTIONAL ANEMIA
150. METHADONE IN A HERION ADDICT
151. NELAXONE FOR ALCOHOL RELAPSE WHO IS REFUSING DISULFIRAM
152. TRAUMATIC RUPTURE OF AORTA
153. DIAPHRAGMATIC HERNIA
154. EPIXTAXIS WITH LIVER CIRRHOSIS AS DEFICIENT CLOTTING FACTORS
155. HEMOCROMATOSIS DIAGNOSIS
156. COLONOSCOPY IN A ELDERLY MAN WITH HB 6 SOMETHING
157. MESENTRIC ISCHEMIA
158. ACE INHIBITOR IN A DIABETIC PT.
159. STEPTOCOCCUS B AGALACTIA IN A NEW BORN
160. ORAL POTASSIUM IN SOME PT WITH HYPOKALEMIA AND DYHYDRATION
161. MRSA PROPHYLAXIS (TAKE SAMPLE FROM ALL SURGERY WARD STAFF)
162. HYPERCALCEMIA WITH SQUAMOUS CELL CANCER
163. CO-TRIMAXAZOLE IN A HIV WITH PNEUMONIA
164. OGD IN A PT WITH NSAID INDUCED BLEEDING NOW STABLE WITH IV OMEPRAZOLE
165. 24 HOUR VIDEO EEG MONITERING
166. SPIRAL CT IN PULMONARY EMBOLISM
167. DIALYSIS IN SOME PT.
168. BETA HISTIDINE IN BENIGN POSITIONAL VERTIGO
169. IV BOLUS OF FLUIDS IN DIARRHOEA MANAGEMNET
170. PNEUMOTHORAX...WHO JUMPED WITH A PARACHUTE

report this post to a moderator (<http://www.rxpgonline.com/report/index.php?p=899345&h=4&u=>)
please rate this post  (<http://www.rxpgonline.com/modules.php?name=usertools&file=pvote&vote=up&u=503349&s=70530&n=4&f=138&t=108126&p=899345>) 
(<http://www.rxpgonline.com/modules.php?name=usertools&file=pvote&vote=down&u=503349&s=70530&n=4&f=138&t=108126&p=899345>)

Back to top

 [Reply](#) ([modules.php?name=Forums&file=posting&mode=reply&t=108126](http://www.rxpgonline.com/modules.php?name=Forums&file=posting&mode=reply&t=108126))  [quote](#) ([modules.php?name=Forums&file=posting&mode=quote&p=899345](http://www.rxpgonline.com/modules.php?name=Forums&file=posting&mode=quote&p=899345))  [Scrapbook](#) (<http://www.rxpgonline.com/modules.php?name=RxPGites&mode=scrapbook&uid=70530>)  [PM](#) ([modules.php?name=Private_Messages&file=index&mode=post&u=](http://www.rxpgonline.com/modules.php?name=Private_Messages&file=index&mode=post&u=))

 **Syrian** (<http://www.rxpgonline.com/threads70530.html>) 
(<http://www.rxpgonline.com/modules.php?name=Messenger&file=buddy&op=compose&to=Syrian>)
Titan

Posts: 124
Credits: 7019 (<http://www.rxpgonline.com/docs/credits>)

 Fri May 21, 2010 10:42 pm (4 years ago) **#5** ([modules.php?name=Forums&file=viewpost&](http://www.rxpgonline.com/modules.php?name=Forums&file=viewpost&))

January 2009

THEME : ASTHMA MANAGEMENT
options :
A- budesonide (inhaled)
B- leukotriene
C- oral steroids

D- IV salbutamol
 E- inhaled salbutamol
 F- inhaled salmeterol
 G- reassure
 H- IV aminophylline

what's the next management for these patients ,

- 1- a child is brought to A & E for severe attack asthma , he didn't respond to nebulised agonists at home
- 2- a child present with eczema and wheeze , he didn't respond to inhaled beta2 agonists .

ANS : 1D 2A

THEME: STING BITE

options:

A- topical steroids
 B- oral prednisolone
 C- adrenaline
 D- oral antihistamine
 E- IV antihistamine
 F- flucloxacillin
 G- reassure

3- a child is brought to A& E with swollen red itchy hands after a sting bite by a bee .

4- a child presents with stridor and ,rash and feel unwell after a bite by a bee.

ans : 3 D 4C

THEME : GYNAECOLOGY INFECTIONS

options :

A- gardnerella
 B- chlamydia .T
 C- candidiasis
 D- herpes simplex
 E- treponema pallidum
 F- mycobacterium tuberculosis
 G- actinomyces

1- A woman consults for primary infertility , on ultrasound there's ligne between live diaphragme

2- a woman just after having an IUCD fitted comes for low abdominal pain and vaginal discha

3- a woman consults for white creamy vaginal discharge , on exam vagina red sore inflamed

4- a woman consults for superficial painful ulcers

Ans: 1F 2G 3C 4D

1F 2-G actinomyces , 3C CANDIDIASIS 4D Herpes Simplex

Multiple painful shallow ulcers associated with fever, myalgia and headache are typically seen in Genital Herpes Simplex.

SBA:

options :

A- brain metastases
 B- orbit metastases
 C- GCA

a patient was treated for breast carcinoma few months ago presents with eyelid drop and constrict

ANS : A

SBA

a child attending nursery 3 days a week presents with varicella zoster

next action :

A- isolate the child in a cubicle
 B- isolate child from family members
 C- allow child to return to nursery when temperature has settled
 D- allow child to return to nursery when vesicles have crust over

Answer: D- allow child to return to nursery when vesicles have crust over.

(Infectivity in chickenpox extends from 2 days before the appearance of the rash until pustules crust.)

THEME: OPHTHALMO

options:

A- stain lesion Fluorescent staining
 B- x-ray orbit
 C- intraocular tonometry

1- a man was gardening has blepharospasm + photophobia

blepharospasm during hedge cutting

2- .metal piece in eye

ANS : 1A 2B

SBA:

options :

A- give penicillin
 B- give adrenalin
 C- call resuscitation team
 D- give cefotaxim

a child with sore throat , fever is dribbling saliva

ANS : C

THEME: IMMUNISATION

a woman who is hepatitis B carrier give birth to a baby

management :

A- check baby hp B antibodies

B- check baby hp B antigen

C- do hep B immnuoglobulin

ANS : C??

SBA :

a patient is taking medication developps rigidity , mask face

what cause the symptoms :

A- anticholinergic

B - antipsychotic

ANS : B

SBA:

A patient is having local anesthesia with xylocaine 1% + adrenaline

what's the effects of adrenaline :

A-augmente effect of Anaesthesia

B-reduce effect of Anaesthesia

C-prolonge effect of Anaesthesia

D-reduce efficacite of Anaesthesia

ANS : C

.

SBA:

a patient presents with 4 weeks hoarsseness, exam normal ,

management :

A-reassure

B-refere urgently to ENT

C-refer to outclinic ENT

D-no trt

ANS: B

SBA:

a man brings his wife into A&E after finding her unconscious at home .he says at breakfast she had complained of sudden sever headache .

investigation:

A-MRI

B-X ray skull

C-CT scan brain

D-carotid doppler

ANS: C

SBA :

patient with sensorineural hearing loss and loss of corneal reflex on the left side

most definitive investigation :

A-CT scan of internal auditory meatus

B-nuclear imaging of brain

C- MRI of internal auditory meatus .

ANS : C

SBA :

a town has a population of 500 000 people .during 5 years ,100 patients are reported to GF cancer y .and during the same period the coroner receive 1250 death certificate for cancer , what's the the annual prevalence per million in this population :

A- 800

B- 1000

C- 500

D- 600

E- 1250

ANS : C

SBA :

an 8 year complains of cyclical abdominal pain .exam is normal .no changement in bowel hab investigation :

A-barium follow through

B-sigmoidoscopy

C-none required

D-ct abdomen

E-USG abdomen

ANS : C???

SBA :

a 75 year old femal resident of a nursing home presents with intractable itching in her trunk next action :

A-skin scraping

B-skin biopsy

C-examine hands and feet

ANS : C

SBA :

.ovulation test(21 day progesterone)

.passage of blood clot in urine(ca bladder)

foot drop(common peroneal nerve damage)

THEME : ANAL PATHOLOGY

OPTIONS :

18.anal fissure

19.anal heamatoma

20.ulcer on 10cm from anal verge,diagnosis?

21.proctalga fugax

22.sigmodoscopy shows granulomatous rectal mucosa with anal tags bloody stools ,diag?-----

-----CROHN'S DISEASE

1.septal heamatoma

4.treatment of otitis media

8.facial pain ,no tenderness,discharge from nose(i think it ans was nasal septal deviation)

9.painful red eye with painful eye movement,tense eye oedema with proptosis(it was optic neuritis and ans was bed rest,antibiotics sit in dark room)

)

13.weak femoral pulse with carotid bruit(femoral aneurysm)

15.arthralgia with skin lesion on shin,what will be finding on cxr(i think it was sarcoidosis)

THEME : EPILEPSY

16.child has family history of febrile seizures(give parents rectal diazepam)

17.woman 37 wk preg ,12 hr history of headaches and epigastric pain with protein in urine 140/95,management?

23. appendicitis

24.ectopic

25.sheehan syndrome ,what investigation should be done?

26.mode of transmission of chicken pox

27.child eats ferrous sulfate tab,which blood test should be done?

29.girl takes 5 tab of ocp,investigate?

THEME : SCIENTIFIC BASIS OF DISEASE ,amenorrhea and infertility

causes :

A-ovary

B-hypothalamus

C-pituitary (ant .post)

THEME: prenatal screening :

1- duchenne muscular dystrophy (DMD is due to mutations in the dystrophin gene on chromosome (DNA from a blood sample is tested for mutations in the dystrophin gene)

2-cystic fibrosis , couple want to know about cystic fibrosis , they are planning to have a child mutation in the cystic fibrosis transmembrane conductance regulator gene on chromosome prenatal testing is possible with DNA analysed >

options :

A-caryotype

B-chromosome analysis

C-DNA analysis

D-echo foetale

E-foetale prelevement

F- chorionic villous sampling

ANS : 1 C 2 C

SBA : for woman with headache and found unconscious with temp 37.4

A- sub arachnoid

B-pontine hemorrhage

C- subdural and more

ANS: A

SBA: was about use of doxycycline with nausea and vomiting what suggestion to give

A- take with milk

B- before meal

C- after meal

Ans ; B

ans : It should be taken with a full glass of water and patients should be upright for at least 30 minutes after administration to prevent irritation of the esophagus and stomach. Also, there is a risk of liver damage during prolonged use

THEME : Psychiatry DEMENTIA

a. the commonest dementia -----Alzheimer's dementia

b. dementia with neurofibrillary tangles -----Alzheimer's dementia

c. dementia treated with antidepressants -----pseudodementia

SBA:

There was one question on I think which contraception azithromycin would effect:

a. Combined Pill

b. Progesterone only pill

c. Emergency contraception

d. IUCD

ANS : A

THEME: on investigation/management of epilepsy in children:

- A. Girl who has had first episode of convulsion which lasted for 3 minutes at night
 - B. One about febrile convulsion
- 2-3 more questions were there.

Theme on diagnosis of cause of heart failure:

I think in this all the options had people with a systolic murmur.

- A. One was about a female in whom the apex beat has shifted to the left and had systolic murmur
 - B. Fever with murmur
 - C. An old man with palpitations and murmur is worsened on exercise or something.
- I'm sorry can't remember exactly. Time was so short that I had to rush through so many questions.

SBA:

On was about an obese man who drinks 10-15 units of alcohol per week has hiatus hernia hoarseness of voice for 4 weeks. Who will you refer the patient to

- A. ENT specialist
 - B. Gastroenterologist
 - C. Alcohol dependency unit
- etc

ANS : A /B

There was theme on LOC/TIA

another SBA: about the lady who has infertility for 9 months and her cycle is 32 day investigation, when to measure progesterone? the options were at day: A- 11, B-16, C-21 and D- 24

ANS : 24.

measure progesterone 7 days before the next cycle

theme : jaundice in children

A child three weeks old with vomiting, jaundice not thriving. Parents were immigrants and couldn't take a child to a doctor earlier.

The options

- A- duodenal atresia
- B- spherocytosis
- C- glucose-6-phosphate deficiency

ANS :

THEME: vertigo and investigations.

SBA: One question was how the chickenpox spreads. Option were:

- A- airborne
- B- close contact
- C- fecalo-oral
- D- skin to skin

answer : A , airborne (because it's spreads through droplets.)

All anti emetics are preferably given prior to meals, Anaesthesia , surgery and journeys. bioavailability and efficacy is enhanced when given prophylactically. This effectively prevents dyspepsia, post-anaesthetic and post-op nausea and vomiting. It also prevents anti motion sickness when given before starting a journey.

Antacids (H2 blockers and PPIs) and antitubercular drugs are also ideally given empty stomach before meals.

SBA:

A patient had a hemicolectomy, a few days later present with nausea, vomiting. Abdomen tender no bowel movements. What caused this:

- A- hypochloremia
- B- hyponatremia
- C- hypokalemia
- D- hyperkalemia
- E- hypernatremia

ANS: C (was Paralytic ileus and the answer is hypokalemia.)

SBA:

A young girl took an overdose of Paracetamol after her boyfriend left her. After the examination the measurement of plasma Paracetamol was under the relevant line for administration of NAC. She was discharged so what is the next step:

- A- Cognitive therapy
- B- Antipsychotics
- C- Behavioural therapy
- D- Anxiolytics

ANS : C

SBA:

Another question was about a young woman eight weeks pregnant. Uterus at symphysis pubis, Presents with vomiting, dehydration, tachycardia, ketonuria etc. What is the cause or dg ;

- A- Molar pregnancy
- B- Hyperemesis gravidarum

answer :A was molar pregnancy (they mentioned 8 weeks amenorrhoe and uterus at sym pubis-usually at 12 weeks? so increase size .

THEME : ASTHMA

Q1 - Child brought to A&E for severe attack asthma. He didnt respond to nebulised beta 2 ag

Q2 - Child presents wd eczema and wheeze. He didnt respond to inhaled beta2 agonists

A1 & A2 - Inhaled budesonide

EXPLANATION

(Refer to OHCM 6th edition Pg 186)

British thoracic Society guidelines (for asthma) are as follows:

STEP1. inhaled short acting beta 2 agonists

If used at least twice a day or once during night, then go to step 2

STEP2. Add standard dose inhaled steroid

beclometasone or budesonide 100-400microgram/12h

or

fluticasone 50-200microgram/12h

STEP3. Add long acting beta2 agonists

Salmeterol 50microgram/12h

or

Formoterol 12microgram/12h

If still ineffective , increase dose of beclo or budesonide to 400microgram/12h

STEP4. Beclometasone or budesonide up to 1000microgram/12h;

modified release oral theophylline;

modified release oral beta2 agonist;

or

oral leukotriene receptor antagonist

in conjunction to previous therapy

STEP5. Add oral prednisolone OD

refer to asthma clinic

So as per the guidelines, v hv to go to step2 as the step1 used in the question has ineffective.

SBA :

- Pt. got treated for breast carcinoma few months ago. Eyelid drop and pupil constriction.

A - Brain metastasis

Dont u think navjot this is sympathetic chain involvement.....ipsilateral horner synand i think it was lung carcinoma,as it happens with apical CA of lung-----correct i am wrong.

sympathetic chain involvement

THEME : SCIENTIFIC BASIS OF DISEASE

1 sheehan syndrom bleeding post partum hemorrhage what structure of brain involved

2 depression what structure

3 prolactin increased

4 diabete mellitus

option were

A- Thalamus

B- hypothalamus

C- anterior pituitary



D- posterior pituitary


for sheehans----- ant pituitary,,,reduced fsh ,lh-reduced menses

for increased prolactin- -----hypothalamus ,cz- dec prolactin inhibitory hormone.



, prolactin is released by anterior pituitary.



report this post to a moderator (<http://www.rxpgonline.com/report/index.php?p=899349&h=5&u=>)

please rate this post  (<http://www.rxpgonline.com/modules.php?name=usertools&file=pvote&vote=up&u=503349&s=70530&n=5&f=138&t=108126&p=899349>) 

(<http://www.rxpgonline.com/modules.php?name=usertools&file=pvote&vote=down&u=503349&s=70530&n=5&f=138&t=108126&p=899349>) 

(<http://www.rxpgonline.com/modules.php?name=usertools&file=pvote&vote=down&u=503349&s=70530&n=5&f=138&t=108126&p=899349>) 


 [Reply](http://www.rxpgonline.com/modules.php?name=Forums&file=posting&mode=reply&t=108126) (modules.php?name=Forums&file=posting&mode=reply&t=108126)  [quote](http://www.rxpgonline.com/modules.php?name=Forums&file=posting&mode=quote&p=899349) (mo

name=Forums&file=posting&mode=quote&p=899349)  (<http://www.rxpgonline.com/modules.php?name=RxPGites&mode=scrapbook&uid=70530>)  (mo

name=Private_Messages&file=index&mode=post&u=

Back to top



Syrian (<http://www.rxpgonline.com/threads70530.html>) 

(<http://www.rxpgonline.com/modules.php?name=Messenger&file=buddy&op=compose&to=Syrian>)

name=Messenger&file=buddy&op=compose&to=Syrian)

Titan



Posts: 124

Fri May 21, 2010 10:45 pm (4 years ago) #6 (modules.php?name=Forums&file=viewpost&

October 2008

a patient presents with chest injury and shows paradoxical breathing.

options;
tension pneumothorax
simple pneumothorax
hemothorax
cardiac tamponade
traumatic aortic rupture
diaphragmatic rupture
flail chest
fracture rib

paradoxical breathing is it flail chest

EXPLANATION: A direct blow to the chest may result in a localised disruption in the integrity of the rib cage. Most commonly, double fractures of the ribs result in a section of chest wall that cannot resist the pressure gradient generated during breathing.

The result is "paradoxical respiration":

- * the flail segment is drawn in during inspiration
- * the flail segment is pushed out during expiration

diagnosis of psychiatric symptoms

- 1 . pt has many ideas and jumps from one topic to another
- 2 . pt speaks continuously and does not get distracted from interventions
- 3 . pt knows about his psychiatric problem
- 4 . pt in ward claims that nurse knows what she is thinking
- 5 . pt having difficulty falling asleep, early morning waking and avoiding eye contact

options;
low mood
thought insertion
thought broadcasting
insight
flight of ideas
pressure of speech
concentration

Thought insertion is the delusion that some of their thoughts are not their own but have been implanted by an outside agency.

This condition differs from the experience of the obsessional patient who may be distressed by recurrent unpleasant thoughts but is in no doubt that they originate from their own mind.

This delusion is one of Schneider's first rank symptoms for schizophrenia.

In the delusion of thought broadcasting the patient believes that their thoughts are being known to other agencies. This may be via telepathy, the radio broadcasting his thoughts, the newspaper telling about his thoughts etc.

Some patients believe that other people can hear their thoughts

- 1 . a woman 16 weeks pregnant is worried about abnormal chromosome anomaly in her child what's the definitive investigation at this stage ?
- options :
- a- amniocentesis
 - b- chorionic villous sampling
 - c- parents karyotyping
 - d- coombs test

AMNIOCENTESIS

prenatal diagnosis is one of the important questions asked frequently

Scientific basis of the disease

1. a person got stabbed on the right side of the neck. Later when asked to protrude the tongue, the tongue was deviated to the right.
2. a person was not able to close the eye and some difficulty with mouth movement
3. a person with left sided upper and lower limb weakness and left sided facial weakness.
4. a patient comes after a week after thyroidectomy complains of difficulty with the speech
5. a patient gets up in the morning and finds difficulty in speaking. He has an incoherent speech but comprehension was normal.

Options.

- a. hypoglossal nerve
- b. trigeminal nerve
- c. facial nerve
- d. recurrent laryngeal nerve
- f. internal capsule
- g. cerebellum
- h. cerebral cortex
- i. Broca's area
- j. Wernicke's area

#BROCA'S

- A.
- B. bitemporal heminopia
- B. left homonymous heminopia
- C. tunnel vision
- D. increased size of blind spot
- E. right homonymous heminopia
- F. cortical blindness
- G. hysteria
- H. central scotoma
- I. amaurosis fugax
- J. uniocular visual loss
- K. night glare
- 1. A 70 year old man presents with a sudden onset of mild right sided weakness, and has noticed that he has been bumping into things #
- 2. A 65 year old woman is blind on testing but denies that there is a problem with her eye sight
- 3. A 27 year old woman complains of visual problems and weakness of both legs. She had weakness in her left arm 3 months ago, which resolved. Fundoscopy reveals optic atrophy.
- 4. A 54 year old woman complains of coarsening of her facial features, sweats and headaches. She also has a visual deficit.
- 5. A 75 year old woman presents with deterioration eyesight. She has been on

- 1. left homonymous henianopia/ tunnel visionbitemporal hemianopia
- 2. cortical blindness
- 3. bitemporal hemianopia
- 4. hysteria - am not sure
- 5 .. question is incomplete .. not sure of the ans ..
- 2. 1lt.homonymous hemianopia

2--cortical blindness

3--central scotoma

4--bitemporal hemianopia

diagnosis of psychiatric symptoms

- 1 . pt has many ideas and jumps from one topic to another
- 2 . pt speaks continuously and does not get distracted ffrom interventions
- 3 . pt knows about his psychiatric problem
- 4 .pt in ward claims that nurse knows what she is hinking
- 5 . pt having difficulty falling asleep, early morning waking and avoiding eye contact

options;
low mood
thought insertion
thought broadcasting
insight

flight of ideas
pressure of speech
concentration ans
1.flight of ideas
2.pressure of speech
3.insight
4.
5.low mood
correct me if i am wrong

1 . a woman 16 weeks pregnant is worried about abnormal chromosome anomaly in her child what`s the defintive investigation at this stage ?

- options :
- a- amniocentesis
 - b- chorionic villous sampling
 - c- parents karyotyping
 - d- coomb`s test

ans:
amniocentesis/cvs

ANS- DO AGREE WITH AMNIOCENTASIS, THANKS

amniocentesis[bcoz cvs is conclusive only if it z done b/w 10-12 wks f pregnancy wt invasive aminocentesis is b/w 14-16 wks & non-invasive aminocentesis b/w 16-22 wks...as i in qs z 16 wks pregnant so aminocentesis shud b d rt ans in my opinion...plz through ur lig think it's wrong...as u know discussion z d best way 2 clear confusion ...]

1 . a man presents with knee injury while skiing. On examination there is pain on valgus stre
Diagnosis?

- Options;
- a. medial collateral ligament
 - b. lateral collateral ligament
 - c. ant cruciate ligament

b. post cruciate ligament

Ans:
medial collateral ligament

(ANS)...medial collateral ligament....bcoz as u know in cruciate ligament injury(ant/pos) th vague pain whereas pain z localized over torn ligament (in case of injury 2 coll ligaments...med/lat)...also damage to medial & lateral collateral ligaments can b assessd STRESS TEST.(In this Qs pt z having pain only on vulguss stressing ...there z no mention abt pain n also stress test z positive on vulgus force...means that there z injury f med coll ligament...kindly comment f not satisfied with my ans n explanation ...and if possible supporting explanation for ur ans

Scientific basis of the disease

1. a person got stabbed on the right side of the neck. Later when asked to protrude the ton was deviated to right.
2. a person was not able to close the eye and some difficulty with mouth movement
3. a persin with left sided upper and lower limb weakness and left sided facial weakness.
4. a patient comes after a week after thyroidectomy complains of difficulty with the speech
5. a patient gets up in the morning and finds difficulty in speaking. He has an incoherent s but comprehension was normal.

Options.

- a. hypoglossal nerve
- b. trigeminal nerve
- c. facial nerve
- d. recurrent laryngeal nerve
- f. internal capsule
- g. cerebellum
- h. cerebral cortex
- i. broca's area
- j. wernicke's area

Ans:
1.hypoglossal nerve
2.facial nerve
3.cerebral cortex
4.recurrent laryngeal nerve
5.brocas area

3--- i feel ans is internal capsule lesion which cause pure motoe or pure sensory losspl.corre if i am wrong

*** Diagnosis of Diabetes **

- A Conns Syn
- B Cushings Syn
- C Cystic Fibrosis
- D Diabetes Insipidus
- E Impaired Glucose Tolerance
- F Type 1 Diabetes
- G Type 2 Diabetes
- H Nephrotic Syn

1. A 30 yr old business man has palpitations and urinary frequency. He is sweating. His dipstick is +ve for glucose and ketones. His plasma glucose is 26mmol.
ans) type 1 diabetes

2. A 65 yr old woman has a recurrent vaginal itch. she has BMI of 33. Random BLOOD GLUC 15 mmol.
ans) type 2 diabetes

3#. A 55 yr old man has glycosuria. After a two hr glucose tolerance test, his plasma gluc 9mmol.
ans) impaired glucose tolerance

- A. Acute myocardial infarction
- B. Pulmonary embolus to a lower lobe
- C. Perforated peptic ulcer
- D. Penetrating peptic ulcer
- E. Acute pancreatitis
- F. Mesenteric artery occlusion
- G. Biliary colic
- H. Acute rupture of esophagus
- I. Diabetic ketoacidosis
- J. Pneumonia

Questions:- diagnosis of sudden upper abdominal pain

#76. A 70 year old hypertensive, diabetic man with previous history of myocardial infarctc has sudden onset of abdominal pain, nausea and vomiting. f

#77. A 28 year old diagnosed case of hereditary spherocytosis. Bil.colic

#78. A 43 year old alcoholic male with prolonged retching and vomiting following a alcoholic binge. Oesph rupture

#79. A 40 year old hypertensive, smoker who is also diagnosed to have peptic ulcer diseas

presents with epigastric pain and diaphoresis. The pain is not relieved with antacids. It does radiate to the back. Also mind exam reveals a soft abdomen. ?D

#80. Epigastric pain of sudden onset in a 68 year old dowager hospitalized for a fracture hip pain is aggravated by deep breathing...pulm. embolus to lower lobe

EMQ : Wasting of the small muscles of the hand

Options:

- A. Leprosy
- B. Motor neurone disease
- C. Ulnar nerve damage
- D. Carpal tunnel syndrome
- E. Syringomyelia
- F. Cervical rib
- G. Neurofibroma
- H. Pancoast tumour
- I. Metastatic carcinoma in deep cervical nodes
- J. Peripheral neuropathy

Questions:

#1. A 66 year old woman with pain in the neck radiating into the left upper limb into the arm and down the ulnar border of the arm. Oblique x-rays of the cervical spine demonstrate enlargement of the left C8/T1. Intervertebral foramen.

#2. A 34 year old male with deep aching pain in the right arm and hand. He also develops episodes of blanching and swelling of the fingers especially on turning his head towards the shoulder.

3. A 36 year old woman 5 months pregnant with her third child with history of severe pain in the hands especially in the thumb and index fingers. The pain is relieved on swinging the arm flexing and extending the wrist.

4. A 38 year old male with progressive left foot drop. He has a history of severe cramps in the left leg. Examination reveals wasting of small muscles of the hands, and left leg. Widespread fasciculations, brisk reflexes and left extensor plantar response.

5. A 69 year old heavy cigarette smoker with history of hemoptysis. He has severe pain in the right shoulder especially at night. Examination reveals wasting of the muscles of the right arm and drooping of the right eyelid.

- 1. neurofibroma???
- 2. cervical rib
- 3. carpal tunnel syndrome
- 4. motor neuron disease
- 5. pancoast tumour

- A. Acute myocardial infarction
- B. Pulmonary embolus to a lower lobe
- C. Perforated peptic ulcer
- D. Penetrating peptic ulcer
- E. Acute pancreatitis
- F. Mesenteric artery occlusion
- G. Biliary colic
- H. Acute rupture of esophagus
- I. Diabetic ketoacidosis
- J. Pneumonia

Questions:- diagnosis of sudden upper abdominal pain

76. A 70 year old hypertensive, diabetic man with previous history of myocardial infarction has sudden onset of abdominal pain, nausea and vomiting.

77. A 28 year old diagnosed case of hereditary spherocytosis.

78. A 43 year old alcoholic male with prolonged retching and vomiting following a heavy alcohol binge.

79. A 40 year old hypertensive, smoker who is also diagnosed to have peptic ulcer disease presents with epigastric pain and diaphoresis. The pain is not relieved with antacids. It does radiate to the back. Also mind exam reveals a soft abdomen.

80. Epigastric pain of sudden onset in a 68 year old dowager hospitalized for a fracture hip pain is aggravated by deep breathing.

ANS LIKELY IS

76- F, 77- Biliary colic, 78- H, 79- C, 80- B

diagnosis of psychiatric symptoms

- 1 . pt has many ideas and jumps from one topic to another
- 2 . pt speaks continuously and does not get distracted from interventions
- 3 . pt knows about his psychiatric problem
- 4 .pt in ward claims that nurse knows what she is thinking
- 5 . pt having difficulty falling asleep, early morning waking and avoiding eye contact

options;
low mood
thought insertion
thought broadcasting
insight

flight of ideas

pressure of speech
concentration ans
1.flight of ideas
2.pressure of speech
3.insight
4.
5.low mood
correct me if i am wrong

LIKELY ANS IS
flight of ideas,
pressure o f speech
insight
thought broadcasting
low mood

1 . a man presents with knee injury while skiing. On examination there is pain on valgus stre
Diagnosis?
Options;
a. medial collateral ligament
b. lateral collateral ligament
c. ant cruciate ligament
b. post cruciate ligament

others can add more questions & answers from past question papers & we can discuss our dot

LIKELY ANS IS
MEDIAL COLLATERAL LIG

A. Acute myocardial infarction
B. Pulmonary embolus to a lower lobe
C. Perforated peptic ulcer
D. Penetrating peptic ulcer
E. Acute pancreatitis
F. Mesenteric artery occlusion
G. Biliary colic
H. Acute rupture of esophagus
I. Diabetic ketoacidosis
J. Pneumonia

Questions:- diagnosis of sudden upper abdominal pain
76. A 70 year old hypertensive, diabetic man with previous history of myocardial infarction has sudden onset of abdominal pain, nausea and vomiting.(ans-F)
77. A 28 year old diagnosed case of hereditary spherocytosis.(ans-G)
78. A 43 year old alcoholic male with prolonged retching and vomiting following a heavy alcohol binge.(ans-E)

79. A 40 year old hypertensive, smoker who is also diagnosed to have peptic ulcer disease presents with epigastric pain and diaphoresis. The pain is not relieved with antacids. It does radiate to the back. Also mind exam reveals a soft abdomen.(ans-A)
80. Epigastric pain of sudden onset in a 68 year old dowager hospitalized for a fracture hip pain is aggravated by deep breathing.(ans-B)
76-Explanation...mesenteric ischaemia-abd pain & odr symptoms f ischaemia..
77-gall stones found in H.S.-responsible fr symptoms related 2 cholelithiasis..
78-alcohol is most common culprit fr acute pancreatitis.....produces retching ,vomiting 7 symptomsO f acute pancreatitis..
79-MI can present as epigastric pain,diphoresis.....as pain is nt relieved by antacids & abdomen soft it could nt b perforated or penetrating peptic ulcer(abd'll never soft in it)....it is nt as necessary than pain f MI will radiate

Management of raised blood pressure

1 .. A frail 65-year old man presents with difficulty in starting micturition associated with stream .He has no history of weight loss and denies any dysuria. On examination a Blood pressure of 130/90mmHg is found. ... H
2 .. A 34 year old known diabetic with chronic renal failure is examined and found to have a pressure of 150/100mmHg. ... A
3 .. A 70 year old woman complains of a chronic temporal headache associated with blurred vision .She reports a history of seeing 'rings' of colour around lights especially at night. Her pressure is found to be 135/90mmHg. ... M
#4 (<http://www.rxpgonline.com/tags/4/>) .. A 55-year-old company executive complains of palpitation episodes of feeling dizzy. A 24 hour ECG tracing reveals episodes of Atrial fibrillation which and go at various times, lasting only 2-3 seconds each time. ... K
5 .. A 26-year-old gravida 3 para 1+1 is found to have a Blood pressure of 150/100mmHg weeks gestation on routine antenatal screening. ... IAF
#6 (<http://www.rxpgonline.com/tags/6/>) .. A 45-year-old man has been treated for panic attacks by I for over 6 months without much improvement. He complains of excessive sweating, flushes diarrhoea. On examination he is found to have a blood pressure of 160/110mmHg. I outpatients clinic the following day he is found to have a glycosuria and a blood pressure 130/80mmHg.pheochromocytoma .. P

options:
A.Lisinopril

B.Timetaphan camsilatr
 C.Imipramine followed by propranolol
 D.Verapamil
 E.Nifedipine
 F.Propranolol
 G.methyldopa
 H.Sodium nitroprusside
 I.Terazosin
 J.hydralazine hydrochloride
 K.sotalol
 L.propranolol followed by phenoxybenzamine
 M.Betaxolol
 N.Glibenclamide
 O.Digoxin
 P.phenoxybenzamine followed by propranolol

1--BPH ,SO RX IS ALPHA BLOCKER,TERAZOCIN

2--CRF WITH HT SO,ACE INHIBITORS,,--LISINAPRIL

3--CHRONIC GLAUCOMA--SO BETAXOLOL

4-- PIH--SO, METHYLDOPA

5--PHEOCHROMOCYTOMA--SO FIRST PHENOXYBENZAZINE THEN PORPRANOLON

Theme The diagnosis of acute vomiting in children

Options

A Acute appendicitis
 B Pancreatitis
 C Cyclical vomiting
 D Duodenal atresia
 E Overfeeding
 F Mesenteric adenitis
 G Meningitis
 H Meconium ileus
 I Gastroenteritis
 J Gastro-oesophageal reflux
 K Pyloric stenosis
 L Urinary tract infection
 M Psychogenic vomiting
 N Whooping cough

Instructions

For each description below, choose the SINGLE most likely diagnosis from the above options. Each option may be used once, more than once, or not at all.

- 1.. A two day old breast-fed male infant is vomiting after each feed. Abdominal demonstrated a "double bubble".D
- 2.. A six-week-old beast fed boy has had projectile vomiting after each feed for the past weeks. He is now lethargic, dehydrated and tachypnoeic.K
- 3.. Four-month-old baby who is thriving has persistent vomiting which is occasionally stained and is associated with crying.J
- 4.. An eight-year-old girl shows signs of moderate dehydration. She has vomited all fluids hours and the vomit is not bile stained. Her abdomen is now soft and non-tender. She has similar episodes in the past year.C
- 5.. A 12-week-old thriving baby is vomiting after every feed. He is developmentally normal fed by the bottle at 260 ml/kg/day.E

Theme Differential diagnosis of Ectopic pregnancy

Options

A Renal colic
 B Pelvic inflammatory disease
 C Normal pregnancy
 D Missed abortion
 E Septic abortion
 F Threatened miscarriage
 G Tortion of ovarian mass
 H Irritable bowel syndrome
 I Inevitable miscarriage
 J Endometriosis
 K Ectopic pregnancy
 L Crohn's disease
 M Bacterial vaginosis
 N Ulcerative colitis
 O Appendicitis

Instructions

For each description below, choose the SINGLE most likely diagnosis from the above options. Each option may be used once, more than once, or not at all.

- 1.. A 21-year-old woman presents as an emergency with a four-hour history of a lower abdominal pain and bright red vaginal blood loss. She has not had menstrual period for nine weeks and positive home pregnancy test one week ago. On vaginal examination, the uterus is tender and bulky. The cervical os is open.I ..OS OPEN SO INEVITABLE IF OS CLOSED THREATENED
- 2.. A 16-year-old woman presents with a sudden onset of severe right iliac fossa pain. On vaginal ultrasound examination a 6 cm diameter echogenic cystic mass is seen in the right fornix.G
- 3.. A 18 year old student, due to take her examinations, reports that she missed her last period and that a pregnancy test is negative. She has worsening abdominal pain, which has

troublesome for three months. She is otherwise well.H

4.. A 22 year old lady who has had two terminations of pregnancy, reports that she is pre again. She has noted a small amount of watery brown vaginal discharge and tenderness in the iliac fossa.K

#5.. A 27 year old, who conscientiously uses the oral contraceptive pill, has experi intermittent vaginal bleeding and malodorous discharge for several weeks. When examine has pain over the lower abdomen, worse on the left. Her temperature is 39C and her whit count is elevated.E

ANS FOR Q 5 IS PELVIC INFLAMMATORY DISEASE.THERE IS NO H/O AMENORRHOEA.SO,IT CAN BE SEPTIC ABORTION

SECONDLY SHE IS ON PILLS SO HOW CAN SHE BCOM PREGNANT???

GOT MY POINT

ITS PID COS MALODOROUS DISCHARGR, SEXUALLY ACTIVE ON OCPS AND INREMITTENT BLEI SUGGEST WITHDRAWAL BLEED

hii PLAB fighter .. thank Q for correcting me .. i agree with u, its PID it cannot be septic ab ..

Theme: Causes of headache

Options:

- A Meningitis
- B Migraine headache
- C Cluster headache
- D Tension headache
- E Subarachnoid haemorrhage
- F Sinusitis
- G Benign intracranial hypertension
- H Cervical spondylosis
- I Giant-cell arteritis
- J Otitis media
- K-Transient ischaemic attack

Choose the single most likely cause from the above list of options.

1. A 35-year-old obese female presents with headache and diplopia. On examination, she has papilloedema. She is alert with no focal symptoms and signs.) = benign intracranial hypertension .
2. A 65-year-old female presents with bitemporal headache, unilateral blurry vision, and pain on combing her hair. Her ESR is elevated = giant cell arteritis
3. A 10-year-old boy presents with fever, headache, left eye pain, and swelling. He described his vision as blurry. He has recently recovered from a cold. = sinusitis
4. A 45-year-old man presents with severe pain around his right eye, with eyelid swelling lasting 20 minutes. He has had several attacks during the past weeks. The attacks are worse at night. = cluster head ache
5. A 25-year-old female presents with episodes of unilateral throbbing headache, nausea, and vomiting. She states that it is aggravated by light. The episodes seem to occur prior to her menstruation. = migraine

Options:

- A Ruptured bronchus
- B Ruptured aorta
- C Ruptured oesophagus
- D Tension pneumothorax
- E Cardiac tamponade
- F Blood transfusion
- G Oral analgesia
- H Morphine(IV)
- I Strap chest
- J Ruptured sleep
- K Immobilisation

Choose the most likely diagnosis/management strategy from the list of options above.

1. A 17-year-old boy with multiple fractures is taken for open reduction. His pulse rate = 120 beats/min BP=100/60 mmHg. = blood transfusion
2. A 47-year-old man is involved in a road traffic accident. Chest x-ray shows atransverse fracture of the sternum. He is otherwise well. =analgesics
- #3. A 47-year-old man is involved in a road traffic accident. Chest x-ray shows atransverse fracture of the sternum. He is otherwise well. = immobilisation ?
- #4. A 35-year-old man is brought to the A&E with a haemothorax. Bilateral chest drainage is done, but his condition fails to improve. = ruptured aorta ?
- #5. A 12-year-old boy was involved in a fight in which he received a kick to his chest. He presents the following day with chest pain and is found to have 3 fractured ribs. = oral analgesic
6. A 45-year-old man who has a seat belt is involved in a high-speed car accident. On x-ray, a 'widened' mediastinum is seen = ruptured aorta

usually when there is a transverse fracture of sternum they admit to see any c
arrythmias.ecg is not in the option so it looks like analgesia.

correct me if i am wrong.

i dont think its immobilisation

yes, i agree, it can cause myocardial contusion so ecg is should be done.

i am not sure for rib fracture.it's said 3 rib fracture.so is it enough to give only analgesia
pl.give ur view

1. women whose previous pregnancy was complicated by iso-immunization has vaginal spott
36wks in an otherwise normal pregnancy. What is the single most appropriate next investigat
a.cardiotocography b- maternal ECG C--ultrasound localisation of placenta, d- Kleihauser te
Hb estimation.

#2.A 23 yr old lady with new sexual partnerhas been on OC pills for last 6 yrs. Presents
2months history of breakthrough bleeding. What is the single most relevent next exam?
a- endocervical swab. b- endometrial sampling, c-FBC, d-gonadotropin level, e- hysteroscopy

3.49 yr old with 9 month H/O prolong slightly irregular periods, clinical exam shows a normal
uterus with no adnexal masses. What is the next single most exam?

a-Endocervical swab, b- Endometrial sample, c- BBC, d- gonadotropin level,e- hysteroscopy

The boy with 3 fractured ribs, I was thinking it should be I: STRAP CHEST, dont know how s
is the pain, of note here is that the boy did not come immediately, he came the next day
Strap chest??? ur opinions required.

1. women whose previous pregnancy was complicated by iso-immunization has vaginal spott
36wks in an otherwise normal pregnancy. What is the single most appropriate next investigat
Ans: d- Kleihauser test,

2.A 23 yr old lady with new sexual partnerhas been on OC pills for last 6 yrs. Presents
2months history of breakthrough bleeding. What is the single most relevent next exam?
d-gonadotropin level,

3.49 yr old with 9 month H/O prolong slightly irregular periods, clinical exam shows a normal
uterus with no adnexal masses. What is the next single most exam?

b- Endometrial sample,

What do others say?

1.A 12-year-old boy was involved in a fight in which he
received a kick to his chest. He presents the following day with
chest pain and is found to have 3 fractured ribs.

Ans:observation and pain relief

Theme:

#Psychiatry (<http://www.rxpgonline.com/tags/Psychiatry/>) next step

- 1.A patient after treatment with antipsychotic says he develops hypersalivation
- 2.A patient after treatment with haloperidol,a man develops stiffness of limbs
- 3.A patient stabbed his father in acute psychosis and was treated with anti psychotic
believes himself to have recoverd from the illness
- 4.A patient who has recurrent hiccups due to anti psychotic treatment

options:

- A.Chlorpromazine
- B.clozapine
- C.ECT
- D.Benzhexol
- E.continue the same drug orally
- F.stop the treatment
- G.Hyoscine
- H.Stop the drug
- I.Review medication

- 1.hyoscine ANTICHOLINERGIC
 - 2.stop the drug
 - 3.continue the same drug orally
 - 4.chlorpromazine USED FOR HICCOUGHS
- correct me if i am wrong

- 1.hyoscine
- 2.stop the drug
- 3.continue the same drug orally
- 4.chlorpromazine

for 3 the likely answer is I, agree with others.

Delayed milestones
 A.Fragile x syndrome
 B.Tay Sachs disease
 C.Bacterial meningitis
 D.hypothyroidism
 E.prematurity
 F.Duchennes muscular atrophy
 G.fetus alcohol syndrome

1.A 4yrs old boy can write his name and draw a circle and square he walks with a lordosis a cannot run
 2.3yr old boy has delayed milestones his uncle and brother also have this condition
 #3.girl can sort out cube 4 9 and is 97 percentile for her weight but her head circumference lower than normal
 #4.A six month old child can smile but has head lag
 #5.Child was normal but then delayed milestones after a fever

Ans:

1.F
 2.A
 3.G??
 4.B??
 5.C

#Psychiatric (<http://www.rxpgonline.com/tags/Psychiatric/>) management how can you help these patient

A.Methadone
 B.Propranolol
 C.Diazepam
 D.Acamprosate
 E.Zopiclone
 F.Risperidone
 G.Amitryptiline

#1.A girl has oral numbness and limb paraesthesias after an argument with her friend ?DIAZEPAM
 2.Pt a heroin addict now in ward in withdrawal wants u to help him METHADONE
 #3.An alcoholic now has been detoxified feel that he wants to remain off it but is scared of relapse ACAMPROSATE
 4.Female with pain in chest tightness feeling like dying and sinking feeling wants some medication of her condition DIAZEPAM?
 5.pt has to go for an interview has sweaty palms and palpitations asks for ur help PROPRANOLOL
 6.Pt having restlessness pacing up and down after death of her husband with difficulty in sleeping ZOPICLONE-FOR SLEEP

Ans:

1.B???
 2.A
 3.D
 4.C???
 5.B
 6.C

#DIAGNOSIS (<http://www.rxpgonline.com/tags/DIAGNOSIS/>) OF RECTAL BLEEDING

Options

A .Angiodysplasia
 B .Inflammatory bowel disease
 C .Hemorrhoids
 D .Diverticulosis
 E .Carcinoma rectum
 F .Carcinoma caecum

#1.A pt with myocardial infarction develops sudden severe bleeding per rectum PR normal
 2.A young patient with chronic diarrhea presents with bleeding per rectum B
 3.A 40-year-old man with painful defecation and blood in stool C
 4.A pt with chronic diarrhea and left iliac fossa pain develops with bleeding per rectum anemic ? E CA RECTUM ..FRSH BLEED, CA COLON MALINA

FEEDING

1.A man after ileostomy
 2.A patient with signs of liver failure
 3.A girl with loose stools and biopsy shows villous atrophy
 4.A patient with parkinsonism having dysphagia
 5.A man 5 days after RTA is still found to have regurgitation of food
 options:
 A.Total parenteral nutrition
 B.PEG
 C.Gluten free diet
 D.low protein diet and antibiotics
 E.nasogastric feeding

Ans:

1.A
 2.D
 3.C

4.B
5.E

- A .Angiodysplasia
- B .Inflammatory bowel disease
- C .Hemorrhoids
- D .Diverticulosis
- E .Carcinoma rectum
- F. Carcinoma caecum

- 1.A pt with myocardial infarction develops sudden severe bleeding per rectum PR normal A
- 2.A young patient with chronic diarrhea presents with bleeding per rectum B
- 3.A 40-year-old man with painful defecation and blood in stool C?
- 4.A pt with chronic diarrhea and left iliac fossa pain develops with bleeding per rectum anemic E

janani1234 wrote:

THEME

FEEDING

- 1.A man after ileostomy
 - 2.A patient with signs of liver failure
 - 3.A girl with loose stools and biopsy shows villous atrophy
 - 4.A patient with parkinsonism having dysphagia
 - #5.A man 5 days after RTA is still found to have regurgitation of food
- options: A...TPN...CO STILL REGURGITATION
- A.Total parenteral nutrition
 - B.PEG
 - C.Gluten free diet
 - D.low protein diet and antibiotics
 - E.nasogastric feeding

Ans:

- 1.A
- 2.D
- 3.C
- 4.B
- 5.E

i don't agree with 5 ans.i feel it should be TPNparenteral nutrition if pt.still regurgating food.

- 1. 31yr C/O abdominal pain which seems to increase during periods over the last year. She noticed difficulty to breathe,chest pain associated with occasional haemoptysis following period. Her mother is asthmatic and she has eczema. She has been unable to conceive. O/E to have enlarged tender uterus, BMI is just 20.What is the single most likely diagnosis.
a- Polycystic ovary b- endometriosis. c- Adenomyosis, d- Chronic salpingitis, e- DM

#2.32 Yr with painful shallow ulcer around the vulva and an offensive white discharge, What is the most likely DX?

A-Syphilis, b- chlamydial pelvic infection,c- gonorrhoea d- lymphogranuloma inguinale e-candida

#3, 52 yr of H/O offensive vaginal discharge and intermittent vaginal bleeding over past 3m. Last cervical smear taken 4yr ago. What is the single most relevant next exam?

a- endocervical swab, b- endometrial sampling, c- cervical inspection, d- FBC, E-endocervical smear.

1-- endometriosis

2--lymphogranuloma

3-- cervical inspection

1. man presented with ca bladder and has been working in factories.he wants to know what has caused it

aniline

latex

asbestos

2. women with 32 days periods what day progesterone should be measured to determine ovulation day

16day

21day

25day

#3 (<http://www.rxpgonline.com/tags/3/>) man with wound due to sharp object in garden

immunoglobulin +antibiotic

vaccine + immunoglobulin

vaccine+immunoglobulin+antibiotic ANS

vaccine+antibiotic

#4 (<http://www.rxpgonline.com/tags/4/>) prevalence rate of Y cancer hit 125 people.and they die 125 so ,ans was 200 closest

100

500

1000
1250

5 commonest ca due to high ferritin level
adrenal
liver
pancrease
testis

6 carpel tunnel due to never compression at
wrist
elbow

7 foot drop due to
common peroneal nerve
tibial nerve

8 fetus born to hep B +ve nother

give immunoglob

9 anuria in surgical ward due to

catheter obstruction

10 child with projectile vommittin feeding and eating well

met acidosis
met alkalosis
no acid base disturbance

aniline dye

21 days ...no, 32-7 wud be 25/24 days

Tetanus immunoglobulin and antibiotics
i think the ans. should be progesterone level on day 25 b,cos the cycle was of 32 days. and
about tetanus one tetanus+tet.immunoglobulin+antibiotic.i,m not sure.please comment on this
projectile voniting is it metabolic alkalosis
stat qs is it 500

patient came to A and E with a gcs 10 and after a while it came to 3
management
i wrote
i.v.mannitol

high ferritin level is it liver

i also think the stat qs was 500.and the vomiting one was metabolic alkosis

causes of abdominal pain
pneumonia
seizure
stroke/TIA
shock in children
jaundice in children
there was a psychistry ques like flight of ideas
one who doesnt stop talking
everyone knows what he is thinking wife thinks her husband has alzeimers bcos he forge
blames her which of the following confirms he has dementia
#diagnostic (<http://www.rxpgonline.com/tags/diagnostic/>) tests of breast
management of hearing
muscle like he cant abduct which muscle
he is trying to pull a rope
lymphatic drainage
ECG ques
i think the ans were MI,pulmonary embolism,pleural effusion

young man brought by friends from night club after taking some drug,he sits quietly and whe
arrives he is seen occupied in doc's seat with his tie and telling that he can hear the sou
color's of the tie.. whats ans???

patient with testicular swellin which disappears on lying down and testis is palpable. diagno:
varicocele

more quest regaring headache or migraine. dont rember exactly.. CT was normal and \
next???

antiphospholipid syndrome-which antibody

24 yr old female with 8 weeks preg c/o lower abd pain and vaginal bleeding?? what inv?

a child with in school is anarousable with tachycardia and dilated pupils following a se morning he was normal when he met his grandmother?? Diagnosis. is it POISONING

I think the answer for the young man brought to a nightclub is LSD as sensations 'cross over' i This gives the user the feeling of hearing colors and seeing sounds.

LSD

LSD ? the patient didn't had temperature ! i guess thats required for LSD aka as acid

whst abt new born baby wid cyanosis over sacral region.what to do next?

Baby with cyanosis: check clotting screen

baby with black spot on back was mongolian spot so reassurance was answer

wat about the person with difficulty in abduction and bulge on front of arm

There was one qs, a child dehydrated, deep breathing, cold peripheries, blood glucose mmol, what wud be the foremost action:

options:

-give insulin i/v

-give N/S 0.9 %

-reassure the parents

-give s/c insulin

I wrote N/s 0.9 % (1st of all to correct dehydration)

Qs: lady with 32 days cycle, she wants to check if she is ovulating, on which day wud she c progesterone test:

-16 day

-21 day

-25 day

-18 day

the correct ans was 25 day (32-7=25)

there was question about pt with bipolar three attack and about to start lithium .wat investig: thyroid?

pt with bipolar attack, he wa about to start Lithium, which investigation?

For ans I looked up for TFTs, but wasn't there in the options , so i chose ECG

abt the lithium q...i cant remember seeing tfts....i thi i went for urea n electrolytes...th that lithium pre-requisites are to check rfts n tfts..as it causes thyroid dysfunction n DI

what was other options for lithium cos it has other side effects like renal diabetes insipidi granulocytosis so it sometime used for agranulocytosis induced by chemotherapy.

so could be FBC or even electrolyte tests cos it cuase renal diabetes I which means elec disturbance, somebody mentioned U and E

the man with discomfort in his upper arm, he felt like something has given up...

ans : ruptured brachialis

its biceps muscle tear

a person playing fotball then come with rash all over the body what was the treatment

another one in which vitals were given and ECG finding OF T wave inversion in v1

another with q wave in v1 to v3

a person playing fotball then come with rash all over the body what was the treatment___I CHLORPHENERMINE

_another one in which vitals were given and ECG finding OF T wave inversion in v1___I

REMEBER MUCH ABT THIS BUT i THINK I CHOSE PULMON EMBOLISM (CXR was normal in this pt

_another with q wave in v1 to v3 ____MI

for uti quetion a girl with uti and grown proteus in culture .wat antibiotic

another in which pt .after perforated cholicystitis develop mrsa infection treatd well rafamicin

for MRSA qs: take swabs from the hospital staff (i think)

the one with the child with chocking it was abdominal thrust with the child standing.just ch the nhs site for pediatric basic life support

Hemlich manuevre, its the officially recommended thing for choking, but its very similar t thrusting and back slapping...

2 question were on cervical ectop and asn was cautry and cryocautry

well, in the question about tetanus toxoid, I think that the question said that the man complete course of vaccination, 8 years before, so is the answer, Tetanus immunoglobulin antibiotic
tetanus he needs vaccine+ig+abs...
i got the ulnar nerve q wrong... i don't know what i was thinking, i was thinking about median nerve

1. pt keeps on talking to you non stop and jumps from 1 topic to another. FLIGHT OF IDEAS

2. a pt in ward admits that staffs of the hospital knows what he is thinking. THOUGHT BROADCASTING

3. man says that he is having some psychiatric problem and he knows that he needs treatment for that. INSIGHT

o Clubbing cause

2- ECG signs
T wave inversion on D3
Twave inversion on v1-3
Q wave!

3- Statin side effect
CPK elevation

4- Cardio drug side effect:
Diuretic : Gout crisis
ACEi : cough

5- Pneumonia :
Specific types - responsible germs / ATB choice

6- Lung tumour
ADH like secretion syndrome: hyponatremia / management

7- Asthma treatment

8- Pulmonary embolism

9- Pneumothorax

10- Extrinsic allergic alveolitis

11- Haemoptysis : TB

12- Diabetes: retinopathy types

13- Pheochromocytoma
Periodic tachycardia.....

14- Hyperprolactinaemia
Amenorrhea / investigation

15- Dysphagia

16- Dyspepsia

17- Jaundice etiology

18- UGI Bleeding
Investigation/etiology

19- Haemochromatosis complication
First organ to present cancer

20- Alcohol withdrawal and relapse prevention drug choice

21- GN/nephrotic syndrome/chronic renal failure/ HUS

22- Myeloma

23- HIV infection complication and treatment

24- Vaginal discharge

Type /responsible germe
Choice of ATB

25- MRSA prevention measures

26- Tetanus prevention
Indication of Ig/vaccine/ATB

27- Multiple sclerosis diagnosis investigation

28- SLE renal complication

29- DVT

30- Aortic aneurysm and dissection

31- Gallstone complication/ post cholecystectomy complication

32- Testicular pain and lump

33- Prostate carcinoma and adenoma/ complication: retention/ renal

34- Bladder cancer risk factor: exposure agent

35- Breast lump investigation hierarchy

36- Enema cause/ diagnosis/ investigation

37- Post surgical complication:
normal diuresis--->complete anuria+++ catheter check
hemicolectomy with massive hypotension and shock 6h postop--> immediate surgical explo
or IV fluids?

38- Tension pneumothorax

39- Meningitis prevention

40- Epilepsy differential diagnosis/ types

41- Loss of conscious/ drop GCS and 1st management

42- Poisoning and withdrawal signs

43- Allergic reaction after sport: antihistaminic....!

44- Prenatal diagnosis test time

45- Antiepileptic and anaemia type

46- Pregnancy- HBV and neonate investigation/management

47- Eclampsia/ treatment

48- Antiphospholipid syndrome: multiple miscarriages....

49- Antepartum haemorrhage

50- Neonate jaundice!!

51- Epiglottitis management

52- Childhood UTI
Complication
Investigation ladder

53- Behavioural problem in child

54- Chocking management

55- Acidobasic disorder in pyloric hypertrophic

56- DKA first management: iv infusion

57- Baby with blue spot in the sacral area since birth: reassurance

58- Menorrhagia management

59- Miscarriage diagnosis/ management

60- Ectopic pregnancy

61- Infertility investigation
Progesterone sampling date in 32 days period woman

62- Metrorrhagia management

- 63- Contraception best indication
- 64- Anxiety type
- 65- Eating disorder
- 66- Bipolar disorder and start lithium/ pre-treatment investigation
- 67- Psychosis signs: thought withdrawal/broadcasting- pressure of speech/flight of idea
- 68- Psychosis drugs side effect/ investigation
- 69- Autism
- 70- Abnormality in eye examination and diagnosis: cataract, diabetic retinopathy...
- 71- Red eye diagnosis
- 72- Retinopathy read all possible aspects on the fundoscopy exam
- 73- Hearing loss or disorder: management (cochlear implant device indication or each ear,..
- 74- Tonsillectomy complication/ management
- 75- Epistaxia
- 76- Ulcerative lesion on the helix: SCC
- 77- ECZEMA topical treatment: choice of drug names++
- 78- Dermatic lesion with scratching sign where to start swabs: lesion/hand and foot/...
- 79- HIV and skin lesion!
- 80- Neck injury: radio level
- 81- Shoulder limitation/ luxity/pain etiology : which structure/ muscle responsible
- 82- Volkman syndrome of the hand: which muscle most painful
- 83- Nerve entrapment
Frequent site of entrapment of each nerve
- 84- Prevalence
- 85- Anatomy : lymph node drainage : abd wall near umbilicus/ langue cancer/ scrotal cancer/ infection/...!

- 1- high feritin liver
- 2- hoptension(60/40) after colectomy init mx blood transfusion then move to the theatre
- 3- theme pulmorary embolism , mi , pneumonia , pneumothorax
- 4- bladder benzene
- 5- theme nephrotic synd , nephritis , hus , crf
- 6- theme chylamida tetracyclin , erthromycin ligonella ,
- 8- check the folly catheter drainage for blockage
- 9- hepatitis b carerier nothing u do
- 10- meningitis nothing you do
- 11- subarchinod
- 12- posioning for child went to his grand mother
- 13- beclomethazone 0.0062%
- 14- flight of idea , thought broadcasting , pressure of speech , insight
- 15- progesterone 21
- 16- abd and add of the fingers
- 17- median nerve in the wrist
- 18- difficult to initiate the abduction of the shoulder suprascapularis
limitation in movement is deltoid
- 19- lithum is ECG as no TFT in the options
- 20- no intrinsic factor in b12 deficiency
- 21- non accidental injury for p lived with is daughter
- 22- folate defienci not pernicious aneima
- 23- for DKA start with normal saline 0.9%
- 24- acmprostate , clorodizopoxide , not remember the rest
- 25- transimic acid to 14 y old not mefnamic acid as usual as she didnt have pain just menorr:
mierna coil , occp ,
- 26- us for ectopic prganancy , misopristol for abortion

child with behavioral probs could have been ADD

old pt on GTN warfarn and frusimide...
he is hypertensive but other wise well.

wat to add new drug..
 1thiazides?
 2diaoxide?
 3ace inhibitors
 4angiotensin converting enzym inhibtors?

old lady had CIN chk up 3months ago all negative..
 now presents wid bleeding per vagina after intercourse..
 management... sorry dnt rem option...

lady used to b on cocps nw pregnant came wid vaginal bleeding speculum xzamination done..
 management..
 i answered crytherapy... well not sure in pregneny is it ok? cuz therew s no other proper a
 according to me

A patient with a 20% perforated tympanic membrane
 Another one with a mobile t. membrane
 Chronic otitis media with discharge.....can't remember very well.....Do we have to know
 surgery to be an SHO????

if clarithromycin was present in the choices for the Pneumonia question,for legionella the
 ATB is clarithromycin.
 that should have been the ATB for legionella

#1.a pt smoker with cough who is having lung cancer and the biopsy shows polygonal cell
 large neucleas etc ans.....large cell ca....small cell.....squama cell etc

2. a pt with irregular large ulcer in cervix with glandular cell...etc
 3. a child was diagnosed with uti and treated with some antibiotic now free from
 abnormality.....what to do.....one of the opt was vit C ... dont know if this is the right ans
 it !!!

#4.a pt who has a F/H of colonic cancer ...what is the investigation as screening....
 #6. another pt who had surgical rx for colonic ca and now
 f/up...opts...colonoscopy..sigmoidoscopy...ocult blood/rme....cea
 7.a pt with small rounded non tender lump in ant neck (i think l.node) with other sys
 feature.....inv..biopsy etc

a pp who lived in elderly home now present with itching and some scratch mark..wt
 do.....i thik opt was chk hand,feet..other

a pt who had burn few days ago now present with dyspepsis and endoscopy shpows many ul
 duodm,stomach....what is management..
 (i think this is cusling ulcer)

a child who stated her pre school and got meningococcal meningitis...now qes was who t
 for prophylaxis..parents...all who attend pre school....etc
 one question about child with epiglottitis.....what to do.....give anti.....immediate c
 anesthetist....o2....etc

another pt who was trested with triple therapy for h pylori gastritis few years back now pr
 with epigast pain and dyspepsisa.....wht inv u do.....gastroscopy....breath test.....h
 serology etc (pt was young)

a child who took 12 paracetamol tab now blood pc level done after 4 hour and level is abov
 A....what to do....opts acetylcystine....etc....

it was swelling in front of knee joint,options were
 prepatellar injry,patellar,tibial etc
 I think it was mentioned in the qs that the swelling was just above tibia or below knee, so I
 INFRAPATELLAR BURSA (it was among the options)
 i guess the answer 4 this question was prepatellar

old pt on GTN warfarn and frusimide...
 he is hypertensive but other wise well.
 wat to add new drug..
 1thiazides?
 2diaoxide?
 3ace inhibitors
 4angiotensin converting enzym inhibtors?

old lady had CIN chk up 3months ago all negative..
 now presents wid bleeding per vagina after intercourse..
 management... sorry dnt rem option...

lady used to b on cocps nw pregnant came wid vaginal bleeding speculum xzamination done..
 management..
 i answered crytherapy... well not sure in pregneny is it ok? cuz therew s no other proper a
 according to me

#old (<http://www.rxpgonline.com/tags/old/>) pt on GTN warfarn and frusimide...
 he is hypertensive but other wise well.
 wat to add new drug..
 1thiazides?
 2diaoxide?
 3ace inhibitors
 4angiotensin converting enzym inhibtors? (3 and 4 both same)
 4 B blockers

the ans should be B blocker, but I wrote ace inhibitors, most prob I'll have this wrong.

-lady used to b on cocps nw pregnant came wid vaginal bleeding speculum xzamition done...
 management... I THINK NO TREATMENT OR CERVICAL ECTROPION (i guess it was in the optic
 pills and preg both predispose to bleeding)

-
 old lady had CIN chk up 3months ago all negative..
 now presents wid bleeding per vagina after intercourse.. I THINK VAGIBAL ATROPHY (this
 weird qs, asking for management when diagnosis and management both were mixed i
 options)

in the lady with CIN ,was there biopsy in options
 was there biopsy in options

beside about pregnant woman ocp bleeding ,i guess crycautry ,i don't remember somehow
 i remember ,was there amylothrophy

in the question of the drug to be addeed
 was digoxin among the drugs given to the patient
 coz i don't remember

was it antiphosphilipid antibody or factor v leiden ?

was SBA with talking about bacteria
 answer coagulase positive

There was a Q regarding a premature delivery at home (21 weeks),2 weeks later now pres
 in ER with Bp 160/100, gen tonic clonic seizures, (i think proteinuria was not in the c
 features).. treatment.
 A: Phenytoin
 B : MgSO4
 C:Exp Laparotomy

A 50 yr old male presented with an ulcer on the lateral aspect of tongue for 2 months..Lym
 drainage??? Submental or Submandibular ..

Q: 45 yr old with an ulcerated leision on the upper outer border of pinna plus ipsilateral
 cervival node enlargemnet ,, Diagnosis: Basal Cell or Squamous Cell Carcinoma... (this
 without any wordings like pearl y like leision with rolled edges etc)

Q : I think there was a Q regarding a pt prevoiusly treated(with tripple therapy)now pres
 again with signs n symptoms of epigastric pain relieve by eating.. Inverstigation of choice: o
 C urea breath, endoscopy etc..

Q: i dont remember abt prostate but there was a Q of post operative pt presented with
 retention of urine (may be after prostate surgery) with absolute NIL urine output.. An
 catheter obstruction(due to a clot)

Can anybody tell me the Ans of the MRSA question(pt presented with MRSA inf in a ward
 theater) next step:

A : stop all the elective surgeries in the hospital.
 B: Move/evacuate all pts to other wards.
 C: Start prophlactic Abx Rx to all pts.

take swab from staff

think it was abt an old lady:

It was vit B 12 def, or lack of intrinsic factor, this was what I think was the ans.

-lady with high bp, post op: MgSO4
 -ulcer on the ear: SCC
 -lymph drainage of side of the tongue: Submandibular

- A qs abt some diagnostic test for prostate: Treansrectal U/S
 -pt with repeated symptoms of abd discomfort after treat with triple therapy: Urea breath t
 madhia i guess the pt with triple therapy was above 55 and had triple thereapy so we :
 check endoscopy which was oseophageogastroscopy in the themw

#urea (<http://www.rxpgonline.com/tags/urea/>) breath test for the pt treated with ppi and come
 dyspepsia
 FOR THE PATIENT TAKING PPI WITH DYSPEPSIAH BREATH TEST

WOMEN 16 WEEK PREHNANT WORRIED ABOUT CHROMOSOMAL ABNORMALITY WHAT INVESTIG
 YOU OFFER
 AMNIOCENTISIS
 MATERNAL ALPHA FETO PROTEIN
 16wks u do amnio
 BUT AMNIO IS INVASIVE TEST BUT UR RIT IN OHCS 16 WEEK AMNIO AND 17 WEEK AFT
 at 16wks u will be safe with amnio as the answer

#IF (<http://www.rxpgonline.com/tags/IF/>) YOUNG FEMALE IS CUTTING SOMETHING IN KITCHEN WITI
 MOTHER AND SHE CUTS HER FINGER ,SHE BECOME UNCONSCIOUS WHAT INVESTIGATION WIL
 GO FOR
 she probably lost conciousness from seeing blood. i ont think a finger cut can cause hypovc
 shock. so. wat inv do u do 4 such a person? i guess none or just do FBC since she was blec
 not sure though

child with excessive itching,parents used emolients but still no relief,
 ans;1% hydrocortisone cream,

lady in old home wth scratch marks over her abdomen nd excessive itching,
 ans check web spaces(she prob has scabies)

first aid in child with epistaxis
 ans;pinch soft pat of nose(or cartilagonous part of nose)

35 yr old lady with progressive conductive deafness
 ans;otosclerosis

child with progressive conductive deafness,trt?
 ans;myringotomy with grommet insertion(he prob has glue ear,whch is da leading cal
 conductive deafness in children)

acute otitis media,trt
 ans;amoxicillin

child continuously vomiting for 2 days,electrolyte imbalance?
 metabolic alkalosis

#till (<http://www.rxpgonline.com/tags/till/>) which level cervical spine xray should b taken
 ans;c7-t1

trachea pushed 2 da left nd no lung markings on da x-ray,on da right side,
 pneumothorax

twave inversion in v1-v3
 pulm embolism

gastric ulcer after burns,trt
 ans;l/v PPI

alcoholism
 for delirium tremens;trt
 diazepam

for trt;chlordiazepoxide

to prevent relapse;acamprosate

Previous Next

#Theme: Vaginal Discharge

#A. Vaginoscopy

B. Vaginal swabs including chlamydia culture

C. High vaginal swab for culture and sensitivity

D. Blood sugar

E. Examination under anaesthetic, hysteroscopy, D&C

F. No investigations, just observe

For each patient below select the SINGLE most appropriate management from the list of o
 above.

#1. 5 year old girl brought in by her mother with a 2 day history of a sore vagina



#2. 52 year old postmenopausal woman with dark red mixed purulent discharge

3. 19 year old woman with a history of pelvic pain and offensive vaginal discharge.





4. 35 year old woman with urinary incontinence and watery vaginal discharge 2 weeks a
 rotational forceps delivery.








5. A 105 kg woman in her first pregnancy with recurrent itchy vaginal discharge confirmed
 of candidal origin

ANS: A,c,b ,c, d

report this post to a moderator (<http://www.rxpgonline.com/report/index.php?p=899353&h=6&u=>)
 please rate this post  (<http://www.rxpgonline.com/modules.php?name=usertools&file=pvote&vote=up&u=503349&s=70530&n=6&f=138&t=108126&p=899353>) 
<http://www.rxpgonline.com/modules.php?name=usertools&file=pvote&vote=down&u=503349&s=70530&n=6&f=138&t=108126&p=899353>)

Back to top

 [Reply](#) ([modules.php?name=Forums&file=posting&mode=reply&t=108126](http://www.rxpgonline.com/modules.php?name=Forums&file=posting&mode=reply&t=108126))  [quote](#) ([modules.php?name=Forums&file=posting&mode=quote&p=899353](http://www.rxpgonline.com/modules.php?name=Forums&file=posting&mode=quote&p=899353))  [Scrapbook](#) (<http://www.rxpgonline.com/modules.php?name=RxPGites&mode=scrapbook&uid=70530>)  [PM](#) ([modules.php?name=Private_Messages&file=index&mode=post&u=](http://www.rxpgonline.com/modules.php?name=Private_Messages&file=index&mode=post&u=))

 **Syrian** (<http://www.rxpgonline.com/threads70530.html>) 
<http://www.rxpgonline.com/modules.php?name=Messenger&file=buddy&op=compose&to=Syrian>
 Titan
    
 Posts: 124
 Credits: 7019 (<http://www.rxpgonline.com/docs/credits>)

Fri May 21, 2010 10:47 pm (4 years ago) #7 ([modules.php?name=Forums&file=viewpost&](http://www.rxpgonline.com/modules.php?name=Forums&file=viewpost&))

july 16th2008 plab1 exam

1-man presents with knee injury while skiing. On examination there is pain on valgus stre
 Diagnosis?

- Options;
 A. medial collateral ligament
 B. lateral collateral ligament
 C. ant cruciate ligament
 D. post cruciate ligament

theme : vaginal discharge :
 2-an old lady 75 years has red and sore vagina , and she also noticed pink coloured discha
 her underwear

3-pregnant female with vaginal itching,husband treated for balanitis

- options :
 A-bacterial vaginosis
 B-vaginal atrophitis
 C-candidiasis -
 D-trichomonas vaginalis -
 E- chlamydia trachomatis -
 F-herpes-
 G-gonococque -
 H- cervical ectropion
 I- endometrial carcinoma

ANS : 2B 3C

#4- an old man COPD has purulent sputum and breathlessness , he has influenza , he has re
 air entry in both chest and bilateral crepitations
 what is the organism involved :

- options :
 A- hemophilus influenzae
 B - staphylococcus aureus
 C- streptococcus pneumoniae
 D- klebsiella pneumoniae
 E-mycoplasma

5- a young men underwent surgery , in postop he has a red wound discharging , a swab
 shows MRSA

what`s is the appropriate management by hospital
 A-transfer all patients from surgical to other wards
 B- stop all surgery in hospital
 C- take swab from hands of all staff in surgical ward
 sorry can`t remember the other options

#6- an old woman has ulcer in labia 3cm with 1.5cm deep , Which lymph node will be invol

- Options :
 A- superficial inguinal lymph node
 B- deep inguinal lymph node
 C- iliac
 D- ilioinguinal
 E-para aortic

#7- a COPD patient presents with breathlessness and purulent sputum with oxymetry 85%

- pa O2 - 8kpa
 pa CO2- 7 kpa
 what`s the appropriate management :
 A-corticosteroids
 B - 24% O2
 C - 60% O2.
 D - invasive ventilation
 E - non invasive ventilationetc

ANS : 7B

8-a 60yr old man with a long standing COPD is complaining of blurry eye vision,he is on multiple medications of COPD.

Which of his medication is responsible for his visual disturbance?

- a) theophylline
- b)corticosteroid
- c)oxygen
- d)B agonist
- e)ipratropium bromide

ANS: B (CORTICOSTEROID long time use may cause cataracts)

9- a man has undergone anterior resection of rectum , at five days postoperative , he has general abdominal tenderness with abdominal pain

what`s the most likely diagnosis :

- A- anastomose leakage
- B- paralytic ileus
- C - abdominal abscess....etc

ANS : 9A

10- a man has fit , there is history of weight loss , hemoptysis , breathlessness

what`s the investigation

CT scan (cerebral metastasis)

11-treatment of schizophrenia :

- A - olanzapine
- B - disulfiram
- C - diazepam
- D - lithium

ANS : A

#12-a woman has been stung by bee , has no symptoms , this time she was stung and has swelling in arm

what`s the treatment

- A- adrenaline (epinephrine)
- B-hydrocortisone IV
- C- antihistamine oral
- D- corticoid oral -
- E- antihistamine cream

13- a child has a clean wound , has never been immunised as his parents were worried about it, there are no contraindications to immunisation , what`s the best management :

- A- full course Diphtheria, tetanus , polio
- B- 1 single injection DT
- C - 1 Single injection DTP
- D - only immunoglobulin

ANS : A

14- a pregnant lady 39 weeks has a fit of eclampsia at home , she was brought to A&E how can you prevent further fits :

- A- sulfate magnesium
- B- diazepam
- C- hydralazine
- D- methyl dopa

ANS : A

15-a woman 16 weeks pregnant is worried about abnormal chromosome anomaly in her child what`s the definitive investigation at this stage ;

options :

- A- amniocentesis
- B- chorionic villous sampling
- C- parents karyotyping
- D- coombs` test ...

ANS : A

16-a 4 weeks breast milk infant has jaundice , what`s the management ;

- A- continue breast feeding -
- B- phototherapy

ANS : A

17- CPR paediatrics in 3 months child

Options :

- A- put 2 thumbs
- B- index & middle finger
- C- heel of 1 hand
- D- heel of 2 hands
- E- all fingers

ANS : B

18- a man after travel was brought unconscious to A&E in his bag there's syringe and trt what's the initial management :

- A- dextrose 50%
- B- dextrose 5%

ANS : A

19- a 1 yr old boy brought in emergency, 5 day history of diarrhoea and vomiting, not tolerate oral fluids, in the last one hour he has become drowsy, his skin turgor is reduced and skin mottled and sunken, heart rate 180 b/min and capillary refill is prolonged. (this is severe dehydration)

what is the most appropriate treatment;

- a) iv fluid bolus 20ml/kg over 20min
- b) rehydrate over 48hrs
- c) rehydrate over 4hrs
- d) oral rehydration
- E- rehydration on nasogastric tube

ANS; A (iv fluids bolus over 20mins first to keep the child alive)

THEME : on feeding

#20- A pt with parkinsonism having dysphagia

OPTIONS

- A- Total parenteral nutrition
- B- PEG (gastrostomy)
- C- gluten free diet
- D- low protein diet + antibiotics
- E- nasogastric feeding

ANS : B

21- a man with jaundice , cirrhosis hypoalbuminemia

22- a man with pearly nodule on face , diagnosis

Options :

- A- squamous cell carcinoma
- B- basal cell carcinoma
- C- melanoma
- D- Lentigo maligna

ANS : B

- theme : origin cells of diseases

- 23- Multiple myeloma ----- plasma cells
- 24- Glioblastoma ----- astrocytes
- 25- Rhabdomyosarcoma ----- skeletal muscle
- 26- AML ----- neutrophil precursors

#- theme : electrolyte imbalance

#Options:

- a. 5% Dextrose water
- b. Insulin with normal saline
- c. Potassium supplements with normal saline
- d. Oral potassium supplements
- e. Plasma expanders

27- question with patient on thiazide diuretics and there was hypokalemia -----
- oral potassium

28- patient with hypotension , hypoglycaemia , with hyperkalemia -----
-- serum saline + hydrocortisone

29- diabetics with glycemia , 30mmol/l ----- insulin only

Insulin with saline

Na : 148

30- A child with severe gastroenteritis

Na and k both decreased ----- ANS : C

SBA :

31- A man after prostatectomy, requires D.V.T prophylaxis, what would be the range on I.I be maintained?

Options:

- a. INR 1
- b. INR 2-3
- c. INR 3-4
- d. INR 4-5

ANS : B

#32- 27 yr male recently can hear his dead uncle's voice telling him that they are spied ,

depressed started alcohol ingestion , and goes to police thinking of someone trying to kill what's diagnosis??
a.alcoholic psychosis
b.depression
c.bipolar disorder

33-lady with hodgkin/ having temp.40 degree centigrade,left side abd pain lymphadenop ,blood was taken for test.
option-
a- await for blood report
b- startbroad spectrum IV antibiotics
c-oral antibiotics
d-full blood count
e-monitor pyrexia

ANS : B

#34- man with diabetes and hypertension presented with proteinuria can't exactly rememb the question
which drug for trt
a-diuretics
b-thiazide
c-gilbenclamide
d-ACE inhibitor

ANS : D

#35woman (<http://www.rxpgonline.com/tags/35woman/>) with rash on cheeks , arthralgia , proteinuria
which investigation :
A- anti mitochondrial
B- Anti DNA
C- Anti nucleolus
D- Anti centromere
ANS : B

36- a woman with lump in the upper outer quadrant of breast. she had a lump previously. th family history of breast cancer (i think mother) . lump is firm mobile..
options:
A- breast carcinoma
B-fibroadenoma
C- pagets
two more options were there

THEME : about child development

options were
A- refer to development paediatrics
B- reassure and review
C- hearing test
D- urgent referral to ophthamologist
E- hearing aids
F- tricyclic anti depressant
G- refer to paediatrician
H- refer to child psychologist
I- refer to GP
some more options.. sorry don't remember

37-. 14 month child not able to walk without support, mother is worried

38-. 3 month child not paying attention to mother while feeding.. on examination can't fi follow an object

39- child plays well with other children but seems to neglect mother when she calls him

40- child not interacting with other children , not playing with other in the ground and avoi contact

41- boy with slap on face, afterthat he could not hear, presents with deafness ,blood fron investigation is...

skull xray?

CORRECT ANSWER= otoscopy
CT scan ...etc

SBA :

#42- about a lady with 2 small children, febrile ,,maculopapular rash, arthritis of joints,cervical lymphadenopathy...
options were
A- viral arthritis
B-SLE
C-psoriatic arthritis

what was the answer? ANS : A ,is Viral

44- a woman in nursing hostel, faecal impaction
 what is the most immediate management
 options
 A- laxatives
 B- phosphate enema
 ANS : B

THEME : about STAB injuries
 options;
 A- tension pneumothorax
 B- simple pneumothorax
 C- haemopneumothorax
 D- haemothorax
 E- cardiac tamponade
 F- traumatic aortic rupture
 G- diaphragmatic rupture
 H- fracture rib
 I- flail chest
 some options don't remember

44- . pt got stabbed in right chest.. came with BP of 70/30 and PR around 130. on exami
 trachea is deviated and hyperresonant in right side

45- pt with stab injury in the left 4th intercostal space in mid clavicular line presents
 increase in PR and distended neck veins. on examination lung sounds clear

46- some injury with bowel sounds heard in the chest

47- one with patient injury in the chest presents with decrease in BP and widened mediastin
 a patient presents with chest injury and shows paradoxical breathing.

ANS : 44A 45 46G 47F

THEME : ENT

.48- a lady undergone syringing for ear wax now complains of ear pain and discharge -----
 WAX IMPACTION

49- a lady has mild ear pain, her husband says that she grinds her teeth in the night while sle
 -----TEMPOROMANDIBULAR JOINT

50- a man went for holidays 6 week back... did swimming etc... now complaints of ir
 bilateral earpain, with redness and discharge

51-. a child had pharyngeal infection now has fever and crying with ear pain

52- an old man came for a mini surgical procedure now in the ward disoriented and bel
 aggressively. which of the following in the patients history should be given attention?
 A- History of trauma
 B-history of medications
 C- alcohol

ANS : C

53- a person with thinning of hair, feeling cold , obese
 options were.
 A- thyroid function tests ,
 B-TSH
 there where more i wrote TFT
 ans-in hypothyroidism ask for tsh and t4

54- a 2 yr old boy is brought to A&E department by his mother. he has been unable to bear w
 since a fall from chair last night. He is tender over the mid tibia but there is no obviou
 deformity.

A angulated #
 B compound #
 C epiphyseal #
 D no fracture likely
 E spiral fracture

ans: spiral #

#55- a lady with depoprogesteron for 9months and worried she has no bleeding- during that t
 advice
 A-Do FSH levels
 B-Give COC
 C- Give POP
 D- reassure

#Theme (<http://www.rxpgonline.com/tags/Theme/>) : prostate

Options

- A- PSA
- B-Acid phosphatase alkaline
- C-Ultrasound pelvis
- D-Placental alkaline phosphatase
- E-Radionucleotide scan

56 bone pain-back ache----- bone scan?

57- prostate ca-on chemo----- follow up: PSA

58- prostate extra cap spread-----ultrasound pelvis

59- parathyroid tumor with acidity----- gastrinoma

THEME : ophtalmo

#60- in a 75 yr old man who complaints of declining vision, cornea n pupil normal, but 1 shows obscured margins???

THEME : investigation

61-.GSC in woman with head injury 15.at night falls to 12-----CT SCAN

62- .slap on this during fight.bld.tinnitus deafness-----SKULL X ray

63-.child -subconjunctival haemorrhage with redness,tenderness cheek -----

64-sudden headache, stiffness of neck , -----CT SCAN

THEME : BLEEDING IN PREGNANCY

pregnancy with bleeding

65-.bld-heavy with uterine cavity empty- rx

66- h/o suggestive-----ectopic -lap

67- . 8wks spontaneous bld- uterine size corresponds to dates

68- .post coital bld-12wks preg

a theme: on complications of MI

69- .dressler's syndrome

70- .acute pericarditis

71- cardiac tamponade

72- a boy with swelling from ear to jaw...mumps

#73- a man with swelling below jaw,occurs during big meals

submandibular stone?

parotid stone?

is it sub-mandibular stone?

74- history of chest pain .no relief on GTN

pesistent ST elevation

TRT

A-lmw +antipalletelet

B-warfarin+aniplatelet

C-statin+antiplatelet

D-Aspirin + antiplatelet

E- Antiplatelet + clopidogrel

75- man thinks he leaves tap running and keeps coming home to check every time

ANS : obsessive compulsive disorder

76- advice to a lady with ca cervix

A- stop smoking

B- stop ocps

C- stop alcohol

A

77- .a 64 year old lady on HRT,now has brown vaginal discharge, what investigation?

ANS : Endometrial sampling

78- . a lady with vaginal bleeding ,10 weeks pregnant, on u/s minimal uterine contents.....

ANS : remove retained products of conception

theme: on gastritis etiology

78- .child wiht bleed nasal bleds

79- .umblical cord with jaundice

80- .alterd bld in stomach

#81- 19 yr old after playing football had asthma attack, he` s already taking inhaled salbutar required, what will u give?

options:

- A- inhaled cromoglycate
- B- inhaled steroids
- C- inhaled salmeterol
- D- oral theophylline

THEME : SCIENTIFIC BASIS

- 82- varicosities along the lateral side of the leg was -----short saphenous
- 83- the one with calf swelling and redness after surgery -----was popliteal
- 84- the one involving the whole upper extremity -----was axillary
- 85- the one with lower abdominal wall varicosities and testicular tumour -----was IVC
- 86- the woman with a uterine tumour, -----internal iliac

there was a Psychiatry ques

i just remember the ans
agorophobia
post traumatic stress disorder
social phobia

87- there was a ques about a lady who already had 2 operations for the lump in the brea worries as her grand mother died of breast cancer when she was 72

choices were

- A- breast carcinoma
 - B- cyst
 - C- fibroadenoma
- i wrote the ans as fibroadenoma
not sure

88- .how is syncope investigated in a man who has exertional syncope

- A- 24 hour ECG
- B- 24 hour BP
- C- echo.....,etc

89- mother brings a child with pain in the arm and the boy is not allowing to exam and crying pain. he is staying with his mother`s new boyfriend while mother goes to work on examination fracture humerus..

options;

- A- admit in the paediatrics ward
- B- discharge with advice
- C- routine referral to gp
- D- routine referral to follow up fracture clinic

ans : follow up in fracture clinic not sure

90- .man with testicular torsion,
- hydrocele (swelling 3 times larger than the other testis),
epididymal cyst (soft swelling at upper pole of testis)
epididymorchitis

91- a man on thiazide, has knee swelling after surgery.....gout

92- man who took 10 paracetamols, doesnt need treatment

what is his followup?

- A- discharge with advice?
 - B- send to psychologist?
 - C- send to medical opd.
- I wrote send to psychologist

#93- depression with psychotic symptoms,

- A- generalized anxiety disorder
- B- ,adjustment disorder
- C- ,major depression
- D- Bipolar affective disorder

#94- . inv of child whose ultrasound shows bilateral hydronephrosis.....

- A- .renal scan?
- B- nephrostomy
- C- ultrasound
- D- IVU

#95- Mother brings child to hospital TWO hours after taking paracetamol overdose .when w check the blood level .

options

- A- immediately
- B- after 2hrs
- C- after 4hrs

ANS : B

THEME: diagnosis of psychiatric symptoms
options;
A- low mood
B- thought insertion
C- thought broadcasting
D- insight
E- flight of ideas
F- pressure of speech
G- concentration
H- illusion

96- pt has many ideas and jumps from one topic to another

97- pt speaks continuously and does not get distracted from interventions

98- pt knows about his psychiatric problem

99- pt in ward claims that nurse knows what she is thinking

100- pt having difficulty falling asleep, early morning waking and avoiding eye contact

ANS : 96E 97F 98D 99C 100A

101- SBA :

CHILD WHO IS ASTHMATIC HAS SEVERE PAIN in knee after an injury with sprain, the knee is swollen. WE HAVE TO GIVE HIM SOME PAIN KILLERS...

OPTIONS

A-Aspirin
B-PARACETAMOL
C-IBUPROFEN
D-MORPHINE
E-CODEINE

ANS : B paracetamol

102- SBA

14 year old develops an itchy scaly patch on her scalp. she had a similar episode on her scalp spontaneously 2 yrs ago, her aunt has a similar undiagnosed rash on the extensor aspects of her knees and elbows.

what is the single most diagnosis.

a)eczma
b)fungal infection
c)impetigo
d)lichen planus
e)psoriasis

answer is PSORIASIS

103- a woman with a diagnosis of mild ulcerative colitis is not on any treatment. she develops diarrhoea and mucus in stool in the last 3 months. all other examinations are normal. her haemoglobin is 9.8g/dl

.what is the single best treatment

A-ferrous gluconate
B-mesalazine
C-corticosteroids
cant remember other options

SBA

104- a patient with hyperventilation because he had panic attacks sweating, palpitation etc. he is having a heart attack, perioral tingling etc.

most appropriate or initial management

a)re breathe into a bag
b)diazepam or lorazepam
c)salbutamol

ANS: rebreathe into a bag

105- a young woman with history of diarrhoea and opening bowels and rectal examination shows inflammation and granulomata----- (crohns)
i think here they asked for treatment which is sulfasalazine

106- woman or man with iron and folate deficiency anaemia with pale stool----- (coeliac dx)

What's the investigation :
the answer endomysial antibodies

107- 6 year old with weekly abdominal pain with headache not associated with vomiting, diarrhoea and no abnormal findings on examination..

what investigation (abdominal migraine)..

answer is none

108- question on young girl 12 years old with dysmenorrhoea

Has to skip school
 ans-----mefenamic acid
 109- question lady 30yrs with heavy bleeding and passage of clots
 etc ans-----_tranexamic acid

THEME : investigation on palpitations
 choose the most appropriate diagnostic test
 Options :
 A- chest X ray
 B- thyroid function
 C- ECG
 D- 24H ECG
 E- ECHO

110- 25 year old develops lassitude, breathlessness, purulent sputum, palpitations over 24hr pulse rate 88.
 ECG shows sinus rhythm.
 answer her is chest xray....patient not likely has pneumonia. and there was no sputum mcs option

111- house wife has a history of weight loss 12months. she also Family members noticed that she loses her temper easily and has regular pulse rate of 90. ecg shows sinus rhythm.....
 Ans: thyroid function test

112- old man with frequent episodes of breathlessness and chest pain associated with irregular heartbeat. pulse is regular and he is in sinus rhythm
 ans.....24hr ambulatory ECG

113- 35yr old woman woken up 5 times in a previous month with feeling of thumping in the chest on sitting up for about two minutes and taking a few deep breaths and sensation subsides after further minutes,
 ECG shows sinus rhythm.....ECHO .

THEME: etiology factor of Peptic ulcer
 options
 A- H- PYLORI
 B- NSAIDS
 C- Corticosteroids
 D- gastrinoma
 E- Barret's oesophagus
 F- achalasia

114- 20 year old with 3month hx of epigastric pain at night who smokes 20 packs of cigarettes per day answer is -----H.pylori

115- 55yr old with longstanding severe back pain presents with hematemesis answer is-----
 ---- NSAIDS

116- woman with rheumatoid arthritis who is intolerant to NSAID presents with anaemia and abdominal pain... answer is -----CORTICOSTEROIDS

117- woman with parathyroid hormone and a family history of peptic ulceration and has epigastric pain not responding to PPI answer is -----GASTRINOMA

118- 75 yr old man with a 40 yr hx of heartburn and acid regurgitation presents with a 3 month history of increasing dysphagia for solids
 answer is----- BARRETS OESOPHAGUS

119- they gave a history of sarcoidosis and asked of chest xray findings.....
 ans bilateral hilar lymphadenopathy

120- man gone fishing and develops jaundicei put blood and urine culture here i was thinking of Weil disease...leptosporosis....they have jaundice and it has to do with pools, sewage, etc
 .i may be wrong but with the options given that was the closest.

121- a tricky one about a man going to Italy 5 months earlier and now presents with blistering on his trunk
 options were:
 A- varicella zoster
 B- lymes,
 C- acute pemphigoid.
 D- shingles
 since they gave a 5months history it ruled out varicella zoster and the last option i have for now.
 what is acute pemphigoid and what is the link with Italy.

122- there was a question on 76 yr old woman who presents with symptoms of feeling generally unwell, anorexia and weight loss. and i think she was complaining about sudden loss of

vision.....the appropriate initial test

Options :

A- temporal biopsy

B- ESR

ANS; ESR

THEME : diagnosis of childhood disease

Options;

a. croup

b. acute epiglottitis

c. bronchiolitis

d. recurrent aspiration

e. cystic fibrosis

123- child with barking cough ----- croup

124- child not thriving with recurrent resp infection ----- cystic fibrosis

125- child drooling saliva, _ ----- epiglottitis

a child presents with fever cough and breathless and mother says this followed a choking during playing

126- woman with breast cancer with abdominal pain ,confusion...she wasn't jaundiced.....

i think the question wanted the cause

ans i chose was hypercalcaemia

#127- child with asthma not responding to inhaled B agonist and low dose steroid , symptoms worse during exercise .

Options

A- Steroids

B-Salmeterol

C- Salbutamol

D- cromoglycate disodique

ans...CROMOGLYCAT

#128- bilateral iliac fossa pain comes with fever and vaginal discharge.....endocervical swab

Options :

A- high vaginal swab

B- endocervical swab

C- ultrasound

129-CHILD PLAYING WITH TOY AND SUDDENLY has onset of breathlessness and wheezing:

answer is----- foreign body

130- patient with previous breast lump and now has another lump which is firm and mobile..

ANSWER IS Fibroadenoma

THEME : PSYCHIATRY

131- pt jumps from topic to topic ----- flights of idea

132- pt speaks continuously none stop ----- pressured speech

133- pt knows he has a problem ----- insight

134- pt says people know what she is thinking ----- thought broadcasting

135- pt having difficulty sleeping,avoid eye contact ----- low mood

136- pt has unshakable belief about something - -----delusion of grandeur

SBA :

#137- patient post prostatectomy and has heart problem and depression

i think answer is fluoxetine

THEME : OPHTHALMO

138- there was an old woman with drusen.....macular degeneration

139- there was a Diabetic with exudates.....proliferative retinopathy

other options were

tobacco amblyopia

non proliferative retinopathy,

#THEME:

options :

A- broca's area

B- wernickes area
C- internal capsule etc
cant remember all options sorry

#140 (<http://www.rxpgonline.com/tags/140/>) - an old man wake up in the morning with slurrig speec examination , nothing special

141-the one where there is aphasia and hemiparalysis,
Int capsule

there was a Psychiatry ques
i just remember the ans

142- agorophobia
143- post traumatic stress disorder
144- social phobia

145- man with jaundice ,ascitis , signs of encephalopathy -----low protein diet + ATB

146- epididymal cyst(soft swelling at upper pole of testis)
147- epididymorchitis
148- - hydrocele(swelling 3 times larger than the other testis)

149- patient due for some colon surgery having PE and DVT i think already on warfarin what before surgery

Options :

A- continue warfarin
B- cont warfarin and start heparin
C- stop warfarin and start heparin
D- stop warfarin start aspirin
other 2 options i dont remember

ANS : C STOP WARFARINE AND START HEPARINE

150-old nulliparous lady with bleeding-----endorn
ca

151- a woman presents after delivery with painful and tender , red breast
what is the causative organism?

a. staphylococcus aureus
b. streptococcus
c. E.coli
c. staphylococcus albus

ANS : A

152- a woman presents with bilateral iliac fossa pain and comes with fever and vaginal discl
What is the initial investigation?

a. C reactive protein
b. full blood count
c. endocervical swab
d. high vaginal swab

#153-a man while working in the garden had an episode of syncope. By the time the GP re the patient about half an hour later , he is fine. Investigation?

options;-

a. 24 hrs ECG
b. 24hr video ECG monitoring
c. echocardiography
D- CT scan

#THEME (<http://www.rxpgonline.com/tags/THEME/>) : scientific basis of disease

Options.

a. hypoglossal nerve
b. trigeminal nerve
c. facial nerve
d. recurrent laryngeal nerve
f. internal capsule
g. cerebellum
h. cerebral cortex
i. broca's area
j. wernicke's area(receptive aphasia)lesion temporal domin

#154-. a person got stabbed on the right side of the neck. Later when asked to protrud tongue it was deviated to right. -ANS -HYPOGLOSSAL N. MOTOR N TO TOUNGE DEVIATES TO SIDE OF LESION WHEN DENERVATED

155-a person was not able to close the eye and some difficulty with mouth movement -Trige
n

156- a person with left sided upper and lower limb weakness and left sided facial weakness. capsule?

157- a patient comes after a week after thyroidectomy complains of difficulty with the sp
RECURRENT LARYNGEAL

#158-a patient gets up in the morning and finds difficulty in speaking. He has an incoherent speech but comprehension was normal.

-BROCA'S APHASIA aka as expressive aphasia...Lesion in sup frontal lobe dominant side. here ..comprehension intact.

159- a person presents with some raised lesions on the shin. He comes with cough a examination hilar lymphadenopathy is present.
diagnosis?

- options;
a. erythema nodosum
b. lupus vulgaris
c. pyoderma gangrenosum
d. malignant melanoma

ANS : A

160- a person presents with painful red eye and blurring of vision. He has a history of back pain. diagnosis?

- a. episcleritis
b. scleritis
c. iritis
d. conjunctivitis

THEME : Management of electrolyte imbalance

- options;
a)fluid restriction
b)insulin only
c)iv glucose 5% / dextrose
d)iv normal saline and hydrocortisone
e)iv normal saline and potassium supplement
g)oral potassium supplement
h)oral potassium chloride
i)refer for immediate renal dialysis
j) IV normal saline and insulin

choose most appropriate management

161-. a young man presents with nausea and vomiting. investigation show

NA 129
K 5.2
UREA 12
GLUCOSE 4

162. young man with weight loss, thirst and urinary frequency.

NA 148
K 5.2
UREA 12
GLUCOSE 30

163. 20 yr old man involved in RTA suffers multiple fractures and crush injuries. 4 days later anuric with pulmonary oedema.



NA 150
K 7.7
UREA 60

164-. 50 year man has had admitted for investigation breathlessness and weight loss. he has taking a thiazide diuretic for raised blood pressure for 2 years. His blood pressure is 150/100

NA 138
K 2.9
UREA 5.8

165-. an 8 YR OLD boy with gastroenteritis gave a 2 day history of profuse diarrhoea vomiting.

NA 148
K 2.2
UREA 20

report this post to a moderator (<http://www.rxpgonline.com/report/index.php?p=899357&h=7&u=>)
please rate this post  (<http://www.rxpgonline.com/modules.php?name=usertools&file=pvote&vote=up&u=503349&s=70530&n=7&f=138&t=108126&p=899357>) 
(<http://www.rxpgonline.com/modules.php?name=usertools&file=pvote&vote=down&u=503349&s=70530&n=7&f=138&t=108126&p=899357>)

[Back to top](#)

[Reply](#) (modules.php?name=Forums&file=posting&mode=reply&t=108126) [quote](#) (modules.php?name=Forums&file=posting&mode=quote&p=899357) [Scrapbook](#) (http://www.rxpgonline.com/modules.php?name=RxPGites&mode=scrapbook&uid=70530) [PM](#) (modules.php?name=Private_Messages&file=index&mode=post&u=)

Fri May 21, 2010 10:50 pm (4 years ago) #8 (modules.php?name=Forums&file=viewpost&tid=108126)

**Syrian** (<http://www.rxpgonline.com/threads70530.html>)(<http://www.rxpgonline.com/modules.php?name=Messenger&file=buddy&op=compose&to=Syrian>)

Titan



Posts: 124

Credits: 7019 (<http://www.rxpgonline.com/docs/credits>)**Jan 2007 Plab1****Theme on terminal care:**

- 1.pt with SVC Obs
2. Pateint with intractable hiccups
- 3.pateint with fugatinating breat ca
- 4.pateint with unable to cough up secretions.
- 5.A pateint of ca breat with pathological fracture

Options:

- a) dexacmetasone tab
- b) bisphosphates.
- c) haloperidol
- d) metronidozole get
- e) hyoscine

Theme on x-ray features of diff. diseases:

6. a person with htn, different bp in both arms and chest pain
7. a pateint with diverticulosis long standing,came with abdominal pain incearing , bowel s not heard.
8. A person undergoes espophageal dilataion and the presents with pain in chest but abdomen was soft.
- 9.a person with post MI

Options:

- a) normal cxr
- b) gas under diaphragm
- c) widening mediastinum
- d) free medisatinal gas

Theme on cells of origin**Options -**

- A. Adipocyte
- B. Neuroglial cells
- C. Plasma cells
- D. Megakaryoblast
- E. Skeletal muscle
- F. Lymphocytes
- G. Erythroblast
- H. Monocytes
- I. Schwann cells
- J. Neutrophil precursors
- K. Astrocytes

10. Lipoma

11. Glioblastoma multiforme

12. Myeloma

13. AML

14. Rhabdomyosarcoma

Theme on Psychiatry

15) A young girl complaints of sudden onset visual loss after witnesing an RTA the last day.

- 1.conversion disorder
- 2.somatization disorder.

16) A man thinks he has rash due to HIV...has been tested thrice...not convincd.

- 1.hypochondriasis
- 2.malingering

THEME on feeding

17) A pt with signs of liver failure

18) A pt with parkinsonism having dysphagia

OPTIONS

- 1-Total parenteral nutrition
- 2-PEG
- 3-gluten free diet
- 4--low protein diet +antibiotics
- 5--nasogastric feeding

Theme Mechanism of Disease

Options

- A. Infection
- B. Allergy
- C. Genetic
- D. Immune process
- E. Chloride channel defect
- F. Alpha-1 antitrypsin def.

- 19. Asthma
- 20. Cystic fibrosis
- 21. Bronchiolitis

Theme on Treatment Of Post MI

Options:

- A-Atropine
- B-Pacemaker
- C-Streptokinase
- D-Alteplase
- E-Valve replacement
- F-Nitrates
- G-Angiography
- H- Pacemaker replacement
- I- Naproxen
- J-Steroids
- 22. Myocardial infarction but no chest pain
- 23. Myocardial infarction with Heart block
- 24. Myocardial infarction with murmur
- 25. A pt. with chest pain, ECG showed T wave depression in L III, aVF & L II has pain & nausea 2 hrs & it subsides completely. Now he presents in the A & E after one hour. What do you next.
- 26. A pt. develops chest pain, which subsides. He has an ejection systolic murmur, BP 110 mmHg, low volume pulse. The Next step.
- 27. A pt. recovering from MI, collapses & O/E has a pulse of 36 / min. Next step.
- 28. A pt. develops pyrexia & pleural effusion one week after inferior Myocardial infarction.

Theme on diagnosis of Upper GI diseases

Options:

- A. Barrett's esophagus
- B. Achalasia cardia
- C. Plummer Vinson syndrome
- D. Scleroderma
- E. Hiatus Hernia
- F. Peptic ulcer
- G. Parkinsonism
- H. GORD

- 29. Transformation of squamous epithelium to columnar epithelium
- 30. A 50-year-old female presents with pallor and fatigue, blood smear shows microcytic hypochromasia. She has post cricoid webs and has difficulty in swallowing.
- 31. A boy with dysphagia, an organ protrusion into the thoracic cavity
- 32. A layer of submucosal hyaloid fibrosis
- 33. Absent Aurbex myenteric plexuses in lower part of oesophagus

SBA

- 34. A patient presents with pain in epigastrium, weight loss and on examination left clavicular lymph nodes.

Options:

- Gastric Ca
- Others

Theme on GYN Management

Options:

- A- Cervical smear
- B- Cervical biopsy
- C- Laporoscopy
- D- Per speculum exam
- E- Colposcopy

- 35- Lady with diagnosed CIN-1. CA cervix 6 months back now comes for follow up
- 36- Lady with CIN-2 diagnosed 6 month back now comes for follow up
- 37- Post menopausal women with bleeding & dyspareunia
- 38- Pre menopausal women with ectropion & bleeding

- 39- A 60 year old man with sudden onset calf pain on upper medial side..no swelling...h dorsiflex and planter flex his foot easily.

Options

- a) Ruptured popliteal cyst
- b) Gout
- c) Psudogout
- d) other options which I don't remember

40- A patient with oral ulcer and onantion there are white striae on it.

Options:

lichen planus
aphthous ulcer

41- 63 years old man with 20 years h/o smoking just retired from minery profesion, now p with s/s of bladder cancer and on biopsy its transitional cell carcinoma

options:

a) smoking
b) minery

44- themes on unconsciousness in elderly...not very difficult...but very tricky!!!

Theme on Diagnosis of cervical cancer

Options

A.Abdominal x-ray
B.Cervical brush smear
C.Cervical spatula smear
D.Colposcopy and biopsy
E.Cone biopsy
F.Cystoscopy
G.Examination under Anaesthesia
H.Intravenous (IV) urogram
I.Magnetic resonance imaging (MRI)
J.Outpatient hysteroscopy
K.Sigmoidoscopy
L.Transvaginal ultrasound scan

45. A 54 year old woman is referred with irregular vaginal bleeding. Vaginal examinatic proved impossible as she has never had a sexual relationship. She has diabetes and a body index (BMI) of 34 kg/m2

46. A 62 year old woman reports episodes of post menopausal bleeding and discharge. Two ago, she had a negative smear but there is an obvious ulcer on her cervix.

47. A 44 year old healthy woman is referred with intermenstrual bleeding and discharge. / age of 32 she was successfully treated for carcinoma in situ. She has had regular follow-up w recurrence. A recent smear was negative.

48. A 38 year old woman had a severely dyskaryotic cervical smear but visually and colposcop her cervix appears normal. The repeat smear shows the same result.

49.A 58 year old woman has a carcinoma of the cervix confined to the ectocervix. The ut mobile, no masses are palpable and her chest is clear.

50. A 26 year old woman has been promoted at work to a job that requires regular speaking. she is worried and anxious about it and feels she will faint.

single MOST USEFUL intervention

a.CBT
b.diazepam
c.flouxetine
d.pschoanalytic psychotherapy
e.relaxation.

Theme on reasons for heamaturia.

51.Old man on warfarin latest standard I.N.R about 1 or 2 presented with painless haematuria mention of somkinf history also Diagnosis?

52. Old man on warfarin, I.N.R markedly deranged about 5 prsents with painless haem diagnosis?

53. Old man with history of renal colic and raised serum urate Diagnosis?

54. Young child with recurrent heamaturia, think some some mention of throat Infection Diagnosis?

Options

a .warfarin overdose
b. transitional cell CA
c. Acute glomerulonephritis
c. oxaliosis
d. renal stones

Theme on basis of diseases

55. Childhood asthma
56. Bronchiolitis
57. Emphysema in person who has had neonatal jaundice
58. Cystic fibrosis

Options

a. infection
b. allergy
c. alpha 1 anti trypsin deficiency
d. Chlorine ion excess or something?

Theme on lumps in neck

59. multiple discharging sinuses ,associated with night sweats, diagnosis?
60. A person with symmetrical unilateral swelling behind angle of jaw, mumps had been rule diagnosis?
61. A supraclavicular swelling(very much suggesting virchow's node)in old man with weight and abdominal pain ,diagnosis?
62. A supra clavicular lump with ipsilateral associated pleural effusion in a ship worker,diagnosis?
63. A lump in midline between sternocleidomastoids invading the muscles ,moves swallowing.,diagnosis?

Options:

- a. thyroid ca
- b. gastric ca
- b. pleomorphic adenoma of salivary gland
- c. mesothelioma
- d. tuberculous adenitis

theme on electrolyte imbalance

64. A girl presented with vomiting drowsy some other symptoms????
Na decrease by 2 points
K by one point or so
Glucose 5 mmol
65. A girl presented dehydrated, rapid breathing glycosuria
Na and K increased
Glucose 30mmol
66. A child with severe gastroenteritis
Na and k both decreased
67. An old man on thiazides,
K was decreased
68. A girl presented with multiple fractures and trauma after Rta is hypotensive???? forget res

Options:

- a. 5% Dextrose water
- b. Insulin with normal saline
- c. Potassium supplements with normal saline
- d. Oral potassium supplements
- e. Plasma expanders

Theme on I.V access

69. 2 year old undergoes repeated attempts of IV cannulization? Next step?
70. A 12 year old require resuscitation , hypotensive, failed IV cannulation.

Options:

- a. Interosseous line.
- b. Cvp line
- c. Endotracheal intubation

71. A girl with recurrent UTI, her urine is negative for culture and she is diagnosed as bilateral vesicourethral reflux? What would be management?

- a. Prophylactic antibiotics
- b. reassurance
- c. surgery to correct

72. A man after prostatectomy, requires D.V.T prophylaxis, what would be the range on I.I be maintained?

Options:

- a. INR 1
- b. INR 2-3
- c. INR 3-4
- d. INR 4-5

73. A young woman having H.I.V, patchy bilateral lung shadows, what treatment to give?

Options:

- a. Cotrimoxazole
- Theme on nerve injury

74. A patient on crutches...having difficulty in dorsiflexion and loss of sensation over index middle finger....most likely nerve injured.

Options:

- a) Median Nerve
- b) Radial Nerve
- c) Ulnar Nerve

Theme on Trauma Organ

- a) urethra
- b) bladder
- c) spleen
- d) pancreas
- e) kidney
- f) diaphragm
- g) aorta
- h) liver

74. A person who met with a accident and is in A & E with pain in RUQ and hypotension.

73) A person after an accident when NGT was tried, not successful. And X rays were taken on tube coiled in side chest.

Theme on burns...slightly twisted repeat theme....

74. A child with 10% scald.

75. A child with dehydration with low BP

Options:

- a) Intubation
- b) I/V fluids

SBA

75. A child having diarrhoea for 24 hrs. drowsy, sunken eyes. and capillary refill decreased.

- a. bolus 20ml/kg.
- b. rehydrate over 24 hr.
- c. oral fluid.

Theme on investigation of breast lump (little bit twisted)

- A. FNAC.
- B. MRI
- C. USG.
- D. Mammography.
- E. Stereotactic Biopsy.
- F. Stereotactic Fine needle biopsy.
- G. Excisional biopsy.
- H. Lumpectomy.

76. A pt. With fibrocystic disease with symptoms related with menses.

77. A pt. With breast lump but has morbid fear of needles.

78. A pt with no obvious palpable lump but with axillary lymph nodes.

79. A pt with retraction of nipple.

SBA

80. A child with orbital tumor, as understood from the history, or proptosis, what is the investigation to be done

Options:

- a) CT Scan

SBA

81.

A patient presenting with sudden onset of pain swelling in lid, proptosis and they were immediate management?

options:

- a. iv morphine
- b. morphine plus antibiotics
- c. morphine plus emergency referral to ophthalmology team
- d. morphine plus referral to opd ophthalmology.

Sba

82. A person present with pain in eye associated with backache i think

- a.conjunctivitis
- b.scleritis
- c.iritis

theme on dyspepsia investigations:

83. A patient 61 yrs old come with dyspepsia, weight loss and abdominal pain, what investigation will u do?

85. A person who has undergone fundoplication and endoscopy was normal what to do now?

86. A person 38 yrs old been self treating with antacids but nothing better, which test would

87. A patient with Rheumatoid Arthritis on NSAIDs, already taking PPI but still have dyspepsia, investigation would you do?

88. A patient with Barrett's esophagus, what investigation would you like to do now?

options:
 a.endoscopy.
 b.ambulatory oesophageal ph monitoring
 c.oesophageal manometry
 d.test for h pylori
 c gastrin levels

theme on dementia: (repeated theme)

89. A women who had history of low mood ,sleep disturbance and presented this time agitation and irritability

90. A lady aged 61yrs years who was depressed and to doctors questions was answering "i know"

91. A person who is being asked for his age and he replied 80, but after that whatever qu was asked about his life, etc. he replied same 80.

options included:
 a. dspression with psychotic symptoms
 b. shizo effective
 c. major depression
 d. pseudo dementia

SBA

92) A man who is HIV positive and has been seperated from other patients alone in a room doctor needs to see him.

options
 a) put on the apron and mask, wash hands and open door then wear gloves.
 b)wash hands, wear gloves, wear mask and apron then open the door.
 c)wear mask and apron, open door, wash hands and wear gloves
 d)open door, wear gloves, then apron then mask and gloves.

93.
 pH-7.25 and Pco2 also reduced.
 options
 a)metabolic acidosis
 b)metabolic alkalosis
 c)normal
 d)resp acidosis
 e)resp alkalosis.

SBA on epistaxis

94. A young boy presents with acute nose bleed and is brought to the A and E, he is stable talking.

a) pinch the bridge of the nose
 b) reassure
 c) cotton in the nose
 d) pinch the soft part of the nose
 e) ice packs.

95. A patient with hydronephrosis due to stones....asking for management

96. A two year old kid who had a bead in his ear which was found out by otoscopy and he irritated.

A) remove under GA
 B) reassure
 C) syringing
 D) suction

97. A woman after delivery becomes very fearful and sleepless and avoids going out. / eating something like that

options
 1postpartum psychoses

2.postpartum blues

3.postpartum depression

4.acute stress reaction

[snip]. A lady presents with Floating stools n Lethargy diagnosis

1FBC
 2TFTs
 3Endomysial Antibodies
 4stool examination

99. A young man presents with sudden onset of chest pain n breathlessness. There is reduced entry on 1 side n trachea is deviated to the left..next step in management

a chest drain on rt side

b chest drain on lt side

c chest xray

d needle thoracocentesis on rt side

e needle thoracocentesis on lt side

100. A girl who was breast fed and became sick, probably jaundice, what should next be done
options
continue breast feeding
discontinue it

101. A person suffering from some pneumonia like s/s
and was allergic to penicillin.
options
amoxicillin
ceftazidime
clithromycin

102. A young girl who was suffering from itchy and scaly rash on the extensor surfaces of limbs, her aunt was also suffering from some skin problem.
options
eczema
psoriasis

103. An old lady who is in a old house with other mates and had some rash on her back, and not in the condition to give you history. What next should be done?
Options:
a) check her hands (Scabies)

104. A lady who said that she is being controlled by some outside force who tells her to do things
options
delusion
thought insertion
thought broadcasting
acute anxiety

105. A person with epigastric pain radiating to back and on ct enhanced lesion in abdomen.

106. A lady who did not improve after cholecystectomy and her O2 level was dropping despite ICU care.

107. A patient in recovery unit after laparotomy, 10 days back, now presents with pain in shoulder and right epigastric pain, not improving with antibiotics, having high fever.

108. A patient with varicella zoster infection, now presenting with super added infection, black lesions in the vesicular area.

109. A patient with chronic pancreatitis now presents with pain in epigastric region radiating back, on CT abdomen fluid around tail of pancreas found (pseudopancreatic cyst).

options
a) laparotomy and excision of dead tissue
b) percutaneous drainage
c) excision of dead tissue

110. A young boy who swallowed some tablets (sorry don't remember the dose) paracetamol. He was stable when after 4 hours his blood conc. showed the upper limit of paracetamol. How to manage
options
methionine
N-acetylcysteine
charcoal

theme regarding ECG changes

111. A patient with chest pain for 1 hour with ST elevation on ECG in I, II, III, v1, v2
112. A person with ECG changes in v1 to v3.

Options:
a) anterior MI
b) inferior MI
c) Others

113. An old man who was a chronic case of COPD and had pneumonia in every winter and for advice for the coming winter
options
flu vaccine
ipratropium nebuliser
salbutamol inhaler

114. A young guy having purulent discharge, itching in the eyes with congested conjunctiva.
Options:
a) topical antibiotic

- b) topical antibiotic and steroids
- c) steroids
- d) I/V antibiotic

Theme on management of weight loss

Options:

- A. PEG
- B. NG tube feeding
- C. Total Parenteral nutrition
- D. Oral sips
- E. Gluten free diet
- F. Low protein diet with salt restriction
- G. Low protein diet with antibiotics
- H. High caloric diet
- I. Lactose free diet

115. A 5-year-old girl comes with a history of abdominal pain, steatorrhoea, vomiting, growth and aphthous ulcers. Jejunal Biopsy shows villous atrophy

116. A 70-year-old heavy alcoholic presents with hepatic encephalopathy, he has jaundic ascites

117. A 60-year-old patient with long standing Parkinson's disease presents with intradysphagia

118. A 68-year-old male patient suffered a hemorrhagic stroke. After 5 days he is offered but is found to be still aspirating fluids.

119. A 74-year-old patient who underwent resection of the colon and ileostomy for carcinoma now in the ITU as he develops septicemia. He has not been eating anything since the past 2 days

120. A person with perioral rash, vesicular and in groups, yellow secretions, crust formation.. options:

cluster impetigo

varicella or shingles

others

but there was no option of Herpes Simplex

121. 19 years old boy lives in hostel, presents with cough, on examination lymphadenopathy and on chest X ray bilateral consolidations

options:

legionella

mycoplasma pneumoniae

122. 12 years old boy, present with testicular pain without history of trauma, he is afebrile, lower abdominal pain, painful when touch but on examination Rt testis slightly higher than Lt. one. and was no abdominal tenderness on examination.

options:

testicular torsion

epididymorchitis

Theme on choice of antibiotic treatment

123. Trichomonas vaginalis

124. Diplococci

125. Penicillin resistant case

options:

metronidazole

ciprofloxacin

ceftriaxone

clindamycin

Theme on non-accidental injuries

same from previous papers

126. (retinal haemorrhage on fundoscopy --- do skull xray)

127. (bruises on body different sizes and shapes)

(others)

128. there was a question in which patient with signs of liver disease and liver biopsy : pleomorphic nuclei and alpha 1 antitrypsin secreting cells.

options:

Secondary CA

hepatocellular carcinoma

cholangiocarcinoma

Hepatoma

hepatitis C or B

Theme on Breast Cancer investigations repeat one.

129. An old lady with family history of anemia with MCV 120.....

investigations (sorry I don't remember options)

Theme on burns, it's been discussed earlier but there was another Q. in that theme.

130. multiple ulcers in the stomach after burn

131. Patient with multiple ulcers in stomach and duodenum, and was being treated with antacid drugs.

Investigation...

132. Nerve supply of lateral lower half of leg and dorsiflexion of ankle joint

options:

L4-L5

L5-S1

133. Pt. with abnormal insertion of uteter in urinary bladder.
I could not get the answer if anybody know it please let me know.

134. Pt. with palpitations, agitation and atrial fibrilations....S/S of hyperthyroidism, Treatme
Options:
carbimazole and propranolol (written together)

135. A shipyard Pt with unilateral plural effusion.....mesothelioma

136. Pt. with anemia, thyriod.....Pernacious anemia.....invetigation.....antibodies a
intrinsic factor.

137. Increase serum Ca+renal caculi.....

138. Backache, bone marrow findings.....

options:

Gout

Myloma

Theme on bleeding disorders

139. von Willibrand disease

140. prifollicular patichiae/bleeding.....Vit. C deficiency

Theme on vertigo

141. Cerebellar

142. vestibulobassilar ischemia

143. post cerebral artery

Theme on alcohol abuse and withdrawl treatment

144. pt wants to alcohol treatment, has been taken all medical treatments and already j
alcohol withdrawl groups, now came to you but not want anything with unpleasant reactions.
options:

Disulpham

Acomprosate

naltrexone

Vitamins

theme on midline neck swellings

145. A patient presents with swelling in front of neck, on protusion of neck it moves.

146. A patient presents with swelling at the angle of mouth, unilateral, no h/o mumps,
growing, become prominent while chewing food.

147. A patient present with swelling on upper and anterior triangle, which is fast growing.

148. A patient present with hard anterior midline swelling.

149. A pulsatile swelling on upper end of sternoclidomastiod muscle.

Options:

a) parotid gland adenoma

b) thyroglossal cyst

c) cystic hygroma

d) parapharangeal carcinoma

e) thyroid nodule/ca

f) carotid cyst/swelling

150. Child brought with 8 hr Hx of sorethroat, saliva dribbling, what to do next?

a- Call anesthetist


b- Give penicillin

C- do a mouth examination

151. The steps to be followed before entering the room of an immunocompromised patient
is quarantined?

wear mask, enter the room,wash hands and wear the gloves

report this post to a moderator (<http://www.rxpgonline.com/report/index.php?p=899359&h=8&u=>)

please rate this post  ([http://www.rxpgonline.com/modules.php?](http://www.rxpgonline.com/modules.php?name=usertools&file=pvote&vote=up&u=503349&s=70530&n=8&f=138&t=108126&p=899359)

[http://www.rxpgonline.com/modules.php?](http://www.rxpgonline.com/modules.php?name=usertools&file=pvote&vote=up&u=503349&s=70530&n=8&f=138&t=108126&p=899359)

([http://www.rxpgonline.com/modules.php?](http://www.rxpgonline.com/modules.php?name=usertools&file=pvote&vote=down&u=503349&s=70530&n=8&f=138&t=108126&p=899359)

[http://www.rxpgonline.com/modules.php?](http://www.rxpgonline.com/modules.php?name=usertools&file=pvote&vote=down&u=503349&s=70530&n=8&f=138&t=108126&p=899359)

Back to top



([modules.php?name=Forums&file=posting&mode=reply&t=108126](http://www.rxpgonline.com/modules.php?name=Forums&file=posting&mode=reply&t=108126))



(mo

[name=Forums&file=posting&mode=quote&p=899359](http://www.rxpgonline.com/modules.php?name=Forums&file=posting&mode=quote&p=899359))



(<http://www.rxpgonline.com/modules.php?name=RxPGites&mode=scrapbook&uid=70530>)



(mo

[name=Private_Messages&file=index&mode=post&u=](http://www.rxpgonline.com/modules.php?name=Private_Messages&file=index&mode=post&u=)



Syrian (<http://www.rxpgonline.com/threads70530.html>)

([http://www.rxpgonline.com/modules.php?](http://www.rxpgonline.com/modules.php?name=Messenger&file=buddy&op=compose&to=Syrian)

[name=Messenger&file=buddy&op=compose&to=Syrian](http://www.rxpgonline.com/modules.php?name=Messenger&file=buddy&op=compose&to=Syrian))

Titan



Posts: 124

Credits: 7019 (<http://www.rxpgonline.com/docs/credits>)



Fri May 21, 2010 10:52 pm (4 years ago) #9 ([modules.php?name=Forums&file=viewpost&](http://www.rxpgonline.com/modules.php?name=Forums&file=viewpost&)

November. 2006

FROM ALL NOVEMBER PLABBERS

1. A man's foot has been pierced by a metal spike, right through his foot. He has had 4 tetanus vaccinations, with the last being 8 years ago. Since injury has passed 10 hours. Which is the appropriate management: D

- A. Tetanus toxoid
- B. Tetanus toxoid + immunoglobulin
- C. Tetanus immunoglobulin
- D. Tetanus toxoid + Immunoglobulin + Antibiotics
- E. Tetanus Immunoglobulin + Antibiotics

2. A woman gives vaginal birth at term to a baby boy. She has Hepatitis B and is concerned about the risk of transmitting it to her baby. What do you do? C

- A. Give Hep B vaccine
- B. Do Hep B antibody test
- C. Give Hep B vaccine + Hep B immunoglobulin.
- D. Give Hep B immunoglobulin only
- E. do nothing

DX of dyspnea

- A. Asthma
- B. Hyperventilation
- C. Tension Pneumothorax
- D. Simple Pneumothorax
- E. DKA
- F. Laryngeal oedema
- G. LVF
- H. Pneumonia
- I. Pleural effusion??

3. A 19y/o woman comes to A&E unconscious. She has deep sighing resp at 28/min. Temp is 38.5°C

- 4. A woman was in a fire. She has singed eyebrows, stidor and soot in mouth and nose
- 5. A woman has right sided Chest pain and SOB. He has a temp of 39°C and pleural rub in right lower zone
- 6. An elderly woman is short of breath. She has an apex beat displaced to the left and an systolic murmur

7. A town has a population of 500,000. In five year period 1250 people present with cancer (that it was bronchial carcinoma). During the same period the coroner diagnosed additional 1000 people with the same cancer.

What is the annual prevalence of that cancer per million in this population.

- A. 500
- B. 350
- C. 700
- D. 450
- E. 800

8. A mother who gave birth a couple of weeks ago feels as though she doesn't like the baby and doesn't want to feed it. Those thoughts keep coming back to her very often and she does not want to have these thoughts. How will the doctor explain her symptoms to her? C

- A. Delusions
- B. Hallucinations
- C. Obsessions
- D. Illusions
- E. Psychosis

9. A man has been stabbed in the back with a knife. He presents to accident and emergency with an increased JVP, blood pressure of 90/60, pulse rate of 120 per minute and very distressed. SaO₂ saturation is 85% and the trachea is not displaced. What is the most likely diagnosis?

- A. Tension pneumothorax
- B. Laceration of the aorta
- C. Cardiac tamponade
- D. Surgical pneumothorax

10. A 38 yr old 18 wk pregnant woman wants to know about her fetal malformations if none are found.

- 1. chronic villous sampling
- 2. amniocentesis
- 3. nuchal thickness
- 4. anomaly scan

11. A child on a low dose of steroid and B-mimetics still has symptoms during the night (and during exercise). He is using the correct technique to take his medication. What will be your next step in managing his asthma symptoms?

- A. Low dose steroid
- B. double dose of steroid
- C. Theophylline
- D. Long acting B-mimetics

12. During the past three to four years a middle aged man has had two episodes of manic depression with several hospital admissions. What is the best management in this case?

- A. Flupentixol
- B. Chlorpromazine.
- C. Lithium
- D. ECT
- E. Haloperidol

MANAGEMENT OF DYSPEPSIA

- A. Fundoplication
- B. H2 antagonist drugs
- C. simple antacid
- D. triple therapy for Helicobacter Pylori
- E. Proton pump inhibitors
- F. refer for endoscopy
- G. Barium swallow
- H. Oesophageal pH monitoring
- I. Oesophageal manometry
- J. Serology for Helicobacter Pylori

Choose the single most appropriate management.

13. A 56 year old man presents with a persistent complaint of dyspeptic symptoms. 18 months ago he underwent triple therapy for Helicobacter pylori after a positive serology.

14. A man of 32 years old with a long history of chronic arthritis on long term Non-steroidal anti-inflammatory drugs. He has symptoms of light headedness and dizziness.

15. A 40 year old man with sporadic symptoms of dyspepsia. Has been taking PPI for a long time and still symptomatic

16. I am not sure but I think that it was something about Barrett's oesophagus. I am sure that I can remember a bit more about all the options and stems. Please feel free to add or remove anything.

17. a man keeps bees, bee stung him several times, has not had any problem before, 10 days after bee stung on his face, and face was swollen for 10 days options

- 1: carry adrenaline
- 2: antihistamine tablets
- 3: steroids
- 4: ibuprofen
- 5: antihistamine cream

18. white man had lump on his nose from which had a gradual increase in size progressively it is a pearly nodule with 8 mm central depression what's most likely diagnosis?

- 1: basal cell carcinoma
- 2: squamous cell carcinoma
- 3: malignant melanoma
- 4: Moluscum contagiosum

19. A woman 5 days after either hemicolectomy or hysterectomy (I am not sure) presents with difficulty breathing and temperature of 38.5 C and yellow sputum. I think that the question mentioned that the wound was cleared.

What is the most appropriate investigation?

- A. FBC
- B. Blood culture
- C. Sputum culture
- D. MRI
- E. Wound swab

Investigation of hormones

20. old lady with constipation and polyuria --- parathormone

21. woman with galactorrhea, amenorrhea and infertility --- prolactin

22. hyponatremia and hypokalemia, plasma renin low --- aldosterone (Conn's syndrome)

23. hyponatremia, hyperkalemia, hyperpigmentation --- cortisol (Addison's disease)

24. smoker with polycythemia --- erythropoietin

25. treatment of trichomoniasis --- metronidazole

- A. doxycycline
- B. erythromycin
- C. metronidazole
- D. tetracycline

26. man with cervical spondylosis, has a painful eye, intraocular pressure is 16 mm/hg --- iridocyclitis

- A. episcleritis
- B. conjunctivitis
- C. glaucoma
- D. iridocyclitis

27. boy with laryngotracheobronchitis, if left untreated, what is the outcome? ----

- A. resolution
- B. bronchiectasis

28. A young man three days after intercourse complaining of testicular pain. I think that the question mentioned something about nausea and vomiting.

What is the most appropriate management?

- A. USG
- B. Laparotomy
- C. Urethral swab
- D. Biopsy

E. Antibiotics

29. middle age man presents with splenomegaly and hepatomegaly, bleeding, infection, a very high leukocyte counts (mainly neutrophils).

What is the most likely diagnosis?

- A. AML
- B. ALL
- C. Aplastic anaemia
- D. CML

30. A man was diagnosed post partum that he died of postoperative paralytic ileus what is the cause for it -- is it due to

- A. hyponatremia,
- B. hypokalemia,
- C. hypomagnesemia
- D. hypocalcemia

31. A man has standing BP 140/90 and lying down BP 100/70 what is the cause reason for it

- A. hyponatremia,
- B. hypokalemia,
- C. hypomagnesemia
- D. hypocalcemia

32. middle aged woman presents with some weakness in her left arm following an injury. Which vertebrae should be the lowest to be included on the cervical xray to diagnose the level of injury?

- A. C2/C3
- B. C3/C4
- C. C5/C6
- D. C6/C7
- E. C7/Th1

THEME: MANAGEMENT OF DEVELOPMENTAL DELAY

- A. Hearing test.
 - B. Refer to ENT
 - C. Developmental assessment
 - D. Refer to social services
 - E. Psychiatric assessment
 - F. Reassure
 - G. Refer for genetic assessment
 - H. Dietary assessment
- Choose the most appropriate management

33. An 18 month old boy still is not able to walk unaided. His milestone developments seen. The mother is worried.

34. A 3 month old baby seems to be developing normally, is gaining weight but shows no interest in the mother when she is feeding him. The mother is concerned about the situation.

35. A 2 year old boy has reached his developmental milestones, he interacts with his siblings, others. When the mother calls him he seems to ignore her.

36. baby of 10 kg, having sum syrup 50ml/5mg, dose should be 4ml/kg, what would be the dose?

- 1. 0.8ml twice daily
- 2. 4ml twice daily
- 3. 4ml once daily

cause of subdural haemorrhages

- 1. subdural haemorrhage
- 2. extra dural
- 3. chronic subdural
- 4. depressed fracture of skull
- 5. temporal bone fracture

37. a man was hit by a hammer in the head

38. an alcoholic brought by his wife unconscious was fine when came home then deteriorated

39. a man wearing a helmet had rta, hit in the head, gcs was 3 but other vitals are normal

Causes of rash in children

- a. ebv
- b. parvovirus
- c. measles
- d. meningitis
- e. herpes simplex 1
- f. herpes zoster

40. a child having rash around the mouth and gingivostomatitis.

41. a child having rash on neck and face and pyrexial.

42. a child having purpuric rash and fever

43. man involved in rta, his gcs at scene was 11, walked home and his gcs after 2/3 hours was most likely diagnosis, no neurological finding.

a:extra dural haematoma
 b:sdh
 c.fracture base of skull
 d.cerebral haematoma

44. a man was depressed and is taking medications develops rigidity, mask face and rolling tremors. what causes the symptoms
 A. antipsychotic
 B. Antidepressant
 C. Anticholinergics

theme on dementia
 45-alzheimers dementia
 46-man with HTN---vascular dementia
 47-man with dementia and preservation of visuospatial ability---frontal dementia

49.pregnant women with paraesthesia and numbness in both hands (carpal tunnel syndrome) asking for treatment
 a. no action
 b. wrist splint
 c. local anaesthesia
 d. paracetamol

50.-A 30 yr old lady who was some athlete playing tennis game now presents with Floating spots and lethargy..what Definitive tests u do to reach a diagnosis.?
 1--FBC
 2--TFTs
 3--Endomysial Antibodies

51.The pt after some URTI respiratory infection got hematuria i think it is features suggestive of HUS and asking for the investigations and options were
 a.FBC
 b.CLOTTING PROFILE
 c.RENAL FUNCTION TEST
 d.RENAL BIOPSY LIKE THAT .

52.pt with sensorineural hearing loss and loss of corneal reflex on the left side what is the definitive investigation?
 a.CT SCAN OF INTERNAL AUDITORY MEATUS
 b.MRI OF INTERNAL AUDITORY MEATUS
 c.NUCLEAR IMAGING OF BRAIN

53. A 3 month old baby needs to be resuscitated CPR.
 a. 2 fingers on lower sternum
 b. whole wrist
 c. three fingers
 d. palm of hand

54.2. A child with several knee and foot articulation swelling alternately over time needs definitive investigation
 a. aspiration of joint
 b. esr
 c. RF

55.An older woman fell at home and cannot bear weight on her left leg how can you prevent from this happening again
 a. dexamethasone
 b. alendronate
 c. serum calcium

56.Another woman after a period of treatment for breast cancer presents with a fracture on treatment with tamoxifen with a pathological fracture.
 a. serum calcium
 b. steroids
 c. alendronate

57.A past breast cancer patient with metastasis comes with a persistent pain in her back
 a, dimorphone
 b, aspirin
 c. radiotherapy

58.A woman with kidney symptoms rash on her face and photophobia
 a. antihistamine
 b. anti-dsDNA
 c. rheumatoid factor
 d. esr

59. A young man presents with seizure only when other people are present. (SBA)
 Ans. 24 hr video EEG monitoring

60.A patient presents with Horner's syndrome symptoms has ptosis and the problem is
 a. destruction of the sympathetic trunk
 b. oculomotor palsy
 c. Horner's

61. A boy presents at dentist with bleeding and long APTT

- a. hemophilia
- b. liver disease
- c. von willberg

Complication of breast cancer malignancies

- 62. a woman after breast cancer comes with edema of arm lymphedema
- 63. also after BC with weakness of both legs spinal compression
- 64 comes with pathological fracture bone metastases
- 65. comes with head ache and blurring vision cerebral metastases

66. A woman with symptoms of polydipsia, constipation and confusion after the diagnosis of carcinoma of the breast

- a. hypocalcemia
- b. hypercalcemia

67. An alcoholic who has been kicked in the perineum area has got acute urinary retention smells of ammonia and is very distressed but per rectum examination was unremarkable.

68. Theme: Management of cardiac arrhythmias

69. There was a SBA:

pt with some trauma with bleeding from his ear and having conductive deafness and asked the bone which is fractured and options were

- parietal bone
- temporal bone
- petrous temporal bone
- occipital bone

not sure of the exact options and

i gave the answers as petrous temporal bone

70- there was a theme with pt having diminished vision and funduscopy is not done properly - i gave the answers as cataract

another 3 questions related to diabetic retinopathy

proliferative, non proliferative like that not able to remember exact questions

it was a theme with 4-5 questions

71-SBA

The pt after some URTI respiratory infection got hematuria i think it is features suggestive of and asking for the investigations and options were

FBC

CLOTTING PROFILE

RENAL FUNCTION TEST

RENAL BIOPSY LIKE THAT .

i chose renal biopsy but the answer is clotting profile i think

72-1. A 3 month old baby needs to be resuscitated CPR. (SBA)

Answer with 2 fingers

73- A child with several knee and foot articulation swelling alternately over time no definitive investigation. (SBA)

Ans. Aspiration of articulation for crystal microscopy

74- An older woman fell at home and cannot bear weight on her left leg. ??? (SBA)

75- Another woman after a period of treatment for breast cancer presents with a pathological fracture. (SBA)

76- A past breast cancer patient with metastasis comes with a persistent pain in her back. (SBA)
Ans. Radiotherapy

77- A woman with kidney symptoms rash on her face and photophobia (SBA)

Ans. Anti-ds antibody

78- A young man presents with seizure only when other people are present. (SBA)

Ans. 24 hr video ecg monitoring

79- A patient presents with Pancoast tumor symptoms. (SBA)

Ans. destruction of the sympathetic trunk

80- Diagnosis of varicose vein

(MCQ) about varicose vein with pregnant women, about 5 or 6 different questions.

81- (MCQ) Theme : Poisoning and self harm diagnosis. Repetition/modified question poisoning with six different stems.

82- A 3 months pregnant woman presents with bleeding after intercourse. She was stable with additional other symptoms. (MCQ)

83- Theme : Anti partum haemorrhage investigation. About 4 or 5 questions. (MCQ)

84- A boy presents at dentist with bleeding and long APTT. (SBA)

Ans. Haemophilia

85- Complication of breast cancer malignancies:

(MCQ) about breast cancer with lymphoedema. About 5 4 stems with options as lymphoedema, chronic lymphoedema and ect.

86- A woman with symptoms of polydipsia, constipation and confusion after the diagnosis of carcinoma of the breast. (SBA)

Answer: Hypercalcaemia

87- Theme: Diagnosis of epistaxis (MCQ)

Was a repeated theme with a couple of modifications with 5 stems

88- Theme : Migraine Investigation with 5 or 6 stems. (MCQ)

89- (SBA) A pregnant woman with anaemia symptoms and high MCV.

90- A woman or a man with hearing impairment and no corneal reflex.

Answer: acoustic neuroma

91- Theme: Management of cardiac arrhythmias with 5 stems.

92- (SBA) a woman after 1 or two years post or premenopausal with a positive family history of osteoporosis asking for advice.

93- (SBA) A woman (perhaps after an operation) with a pain on deep inspiration but chest clear after C-xray ???

94- (MCQ) Theme: Side effect of antiepileptic medication.
Repetition about side effects of antiepileptic drugs with 3 stems

95- (MCQ) THEME: Diagnosis of Hernias with 5 stems.

96- A woman with rib fracture with complications, bleeding. I think the answer was Ultrasound of a bleeding spleen. I don't remember if this question was an SBA or an MCQ

97- An alcoholic who has been kicked in the perineum area has got acute urinary retention and smells of ammonia and is very distressed but per rectum examination was unremarkable.

I think answer was Urethral Catheterisation.

[snip]- There was a question of anaemia during pregnancy with hb=10.6gms asking for treatment and the options were ferrous sulfate oral, iron folic acid oral etc. Ans- No action

99- pregnant women with paraesthesia and numbness in both hands (carpal tunnel syndrome feature) asking for treatment. I don't remember the options. Ans- wrist splint

100-sba 1-A 30 yr old lady who was some athlete playing tennis game now presents with Flaccid paralysis and Lethargy..what Definitive tests u do to reach a diagnosis..?

1--FBC

2--TFTs

3--Endomysial Antibodies- Answer

101- An young man three days after intercourse complaining of testicular pain. I think that he mentioned something about nausea and vomiting.

What is the most appropriate management?

A. USG

B. Laparotomy

C. Urethral swab

D. Biopsy

E. Antibiotics

102-A middle age man presents with splenomegaly and hepatomegaly, bleeding, infection and a very high leukocyte counts (mainly neutrophils).

What is the most likely diagnosis?

A. AML

B. ALL

C. Aplastic anaemia

D. CML - Answer?

E. NHL

(<http://www.rxpgonline.com/modules.php?name=usertools&file=pvot&vote=down&u=503349&s=70530&n=9&f=138&t=108126&p=899361>)

name=usertools&file=pvot&vote=down&u=503349&s=70530&n=9&f=138&t=108126&p=899361)



(modules.php?name=Forums&file=posting&mode=reply&t=108126) (mo

name=Forums&file=posting&mode=quote&p=899361) (<http://www.rxpgonline.com/mo>



name=RxPGites&mode=scrapbook&uid=70530) (mo



name=Private_Messages&file=index&mode=post&u=

Back to top



Syrian (<http://www.rxpgonline.com/threads70530.html>)

(<http://www.rxpgonline.com/modules.php?name=Messenger&file=buddy&op=compose&to=Syrian>)

name=Messenger&file=buddy&op=compose&to=Syrian)

Titan



Posts: 124

Credits: 7019 (<http://www.rxpgonline.com/docs/credits>)

Fri May 21, 2010 10:55 pm (4 years ago) #10 (modules.php?name=Forums&file=viewpost&

July 2006 PLAB 1

-THEME--MULTIPLE TRAUMA

1--27 yr lady had car accident b hitting head on to a car in front.she hit the front windscreen complains of epigastric pain.most likely injured organ.

(2 more of these were there but were more obvious)

- 1.diaphragm
- 2.spleen
- 3.liver
- 4.pancreas
- 5.ub
- 6.small intestine
- 7.large intestine -----

2-Prevalance population in one area is 500000.no.of pts reporting to gp with cancer y in tha in 5yrs is 50.but in the same period no. of deaths reported due to y=1250?.the 1yr survi y=0.what is the prevalance of y in a yr.

- 1.800
- 2.1000
- 3.200
- 4.1250?
- 5.600
- 6-500 -----

2theme Psychiatry drug side effects:

1==A pt receiving treatment for bipolar affective disorder his tsh level is increased and t3 levels are reduced. Ans: lithium. -

2== Pt: having extrapyramidal effects complains of reduced sexual libido and erectile impo his prolactin is raised. Ans: chlorpromazine.

3==A pt on treatment for depression complains of dry mouth, blurred vision, constipatio tremors. Ans: Amitriptyline. -

4== Pt: with h/o of schizophrenia receiving an antipsychotic agent becomes physically unwe is found to have an elevated body temp: unstable blood pressure excessive sweating and a white blood cell count and raised cpk. Ans: chlorpromazine. haloperidol wasnt a option... --

3 THEME -Cell of origin

1. Multiple myeloma -
2. AML -
3. Rhabdomyosarcoma -
- 4-glioblastoma multiforme-- options
- 1-astrocytes
- 2-schwann cells
- 3-plasma cells
- 4-skeletal muscle cell
- 4-neutrophil precursor
- 5-smooth muscle cells -----

4--theme -Prenatal screening

- a-chorionic villus sampling
- b-fetal heart monitoring
- c-fetal blood sampling
- d-no investigation
- e-kleihauer's test
- f-rheuses
- d- status
- 1-previous child with cystic fibrosis.pregnant mother is concious for this child.
- 2-previous child with congenital hypothyroidism.again pregnant want about risk for next chil
- 3-previous child has suffered from anaemia and jaundice.on ultrasound foetus is doing well?
- 4-pregnant lady in early trimeter with some fresh red vaginal bleeding? -----

5 Theme--Treatment of varicella infections

- 1--Varicella in pregnancy
- 2--old lady with only discolouration n no complaints she is well now---
- 3--young boy with Leukaemia ---
- 4--one pt with ophthalmic involvement in shingles
- 5--post herpetic neuralgia options
- A-oral aciclovir n seek expert opinion
- B-IV aciclovir
- C-Varicella immunoglobulins
- D-Topical aciclovir
- E--Oral [email address in profile] 2 days

F-Oral [email address in profile] 7days
 G-Reassurance
 H--Carbamazepine
 I--Steroids -----

6 theme sba

woman after pregnancy becomes very fearful and sleepless and avoids going out.has fre
 emotional outbursts,sleeplessness and clings to her child claiming inadequate bonding
 1postpartum psychoses

2.normal reaction

3.depression

4.acute stress reaction -----

7 theme sba-

Diagnosis A 64 yr old lady presents with Floating stools n Lethargy..wht Definitive tests whi
 to reach a diagnosis..?

1--FBC

2--TFTs

3--Endomysial Antibodies -----

8--theme sba

A lady presents within 36hrs of unprotected intercourse she wants sum contraception.She h
 attack of Migraine sum days back..She had a history of ectopic pregnancy...whts is the best
 offer her?

1--emergency contraception {levonorgesrtol}

2--IUCD

3-- COCPS

4--IUS -----

9-theme-sba

A Lady presents within 96hrs of unprotected intercourse...she is on the 12th day of her mer
 cycle,,,how can u help her with contraception...

1--emergency contraception {levonorgesrtol}

2--IUCD

3-- COCPS

4--IUS -----

10-theme-

management Ayoung man presents with sudden onset of chest pain n breathlessness.thi
 reduced aientry on 1 side n trachea is deviated to the left..next step in management

1--chest drain on rt side

2--chest drain on lt side

3-chest xray

4-needle thoracocentesis on rt side

5-needle thoracocentesis on lt side -----

11--theme :

Aortic dissection..

1--A man presents with sudden onset of abdominal pain radiating to the back...An emergenc
 showed dissecting AA..next step in management

1--abd ct scan

2--immediate surgery

3--abd usg

4-ercp -----

12-theme

A lab report showing foll..comment pH--7.25 pco2--reduced on comparing with pH n pCO2
 given on the back of question booklet it looked both ph n pco2 were reduced the options w

1-met acidosis

2-met alkalosis

3-normal

4-resp acidosis

5-resp alkalosis -----

13 theme

A pt with many years of monoarticular attacks of joint pain presents with swelling in th
 pinna...the diagnosis

1-Gout -----

14 theme-

epistaxis

A young boy presents with bleeding frm the nose ...wht will u do?

1--pinch the bridge of the nose

2-reassure

3--cotton in the nose

4--pinch the soft part of the nose
5--ice packs -----

15--theme

A child presents with a foreign body in the ear. HE is agitated. on examination u see a bead next will u do

1-removal under GA

2-reassurance

3-syringing

4-refer to ENT -----

16 THEME

A child presents with sudden onset of breathlessness while playing..the mother then notices bead from the toy is missing..wht will be ur next step in management?

1--chest xray

2-pefr -----

17 THEME -- :

feeding

1--A man after ileostomy

2--a pt with signs of liver failure

3---a girl with loose stools n biopsy shows villous atrophy

4--A pt with parkinsonism having dysphagia OPTIONS

1-Total parenteral nutrition

2-PEG

3-gluten free diet

4--low protein diet +antibiotics

5--nasogastric feeding -----

18 theme-

urinary incontinence-

1-A woman 3 days after abd hysterectomy presents with wetting her pants without her know

2-A35yr lady with 3 children all born vaginally n weighing ard 4kg..presents with wetting sneezing...

3--A 60 yr old lady presenting with dysuria n dyspareunia.A msu cultured no organisms

options

1--fistula

2--vag estrogens

3--urge incontinence

4--pelvic floor weakness -----

19 theme CVS

1---pt with fever n a new murmur--

2--pt with breathlessness n bicuspid aortic valve-

3-Alcoholic -pt with a ht n large heart--

4--pt with prosthetic heart valve n sum value of INR..which was raised..--

5--pt with swelling in leg n hoarse voice--

options -

A-hormonal -

B infective -

C -congenital -

D degeneration -

E acquired -

F warfarin overdose -----

20--THEME

Post thyroidectomy, pt presents with hoarseness of voice and on laryngoscopy showing U/L cord palsy.

1: Recurrent laryngeal.N

2-superior laryngeal.NP

3-vagus nerve -----

21 theme uti

A young pt complaining of frequency of micturition...urine examination shows presence of ni

1-klebsiella uti

2-proteus uti

3 DM 4 DI -----

22 theme--

A/ Allow out of bed to go to Toilet.

B/ Dopamine @ 3 mcg/kg/minute iv

C/ Fluid Challenge

D/ Echocardiogram
 E/ Furosemide IV
 F/ Intra Aortic Balloon Pump
 G/ Mannitol 20% 500 ML IV
 H/ O neg Blood
 I/ Suprapubic catheter
 J/ Swan-Ganz Catheter
 K/ Urethral catheter

1/ A 45 year old man with multiple injuries including a fractured pelvis has a little blood in urethral meatus. He has passed no urine three hours after his admission.

2/ A 66 year old man undergoes abdominal aneurysm repair. Over the next four hours hourly volumes from a bladder catheter were 30 ml, 20 ml, 10 ml, and 15 ml. His BP is 105/70 mmHg heart rate is 110 beats/minute and CVP 2mmHg.

3/ Eight hours after blunt chest trauma and multiple injuries a 24 yr old man's hourly urine volume fallen to less than 20ml in two consecutive hours. His BP is 90/60 mmHg, pulse rate 110 beats/minute and CVP 18 mmHg.

4/ A 32 year old miner is rescued after being trapped under a fallen rock for four hours. After bladder catheterisation he is passing 15-20 ml of reddish brown urine each hour. He has tachycardia of 120 beats/minute and a systolic BP of 100 mmHg.

5/ A 62 year old man feels the need to urinate eight hours after a hernia repair but cannot urinate in the bottle provided by the nurse. -----

23 theme-
 vaccination a child 2 yrs who never had any immunisations cause parents were worried about side-effects. now he presents with a wound...

option
 1=tetanus immunoglobulin
 2-dtp 3-tt -----

24 theme :UTI

A child 2 yrs old presents with UTI which is treated with Trimethoprim now culture shows sterile urine...A Micturating cystourethrogram {MCUG} been done now it shows reflux..how to treat this pt..

1--surgery for the reflux
 2--prophylactic antibiotics..

report this post to a moderator (<http://www.rxpgonline.com/report/index.php?p=899362&h=10&u=>)

please rate this post (thumbs up) (<http://www.rxpgonline.com/modules.php?name=usertools&file=pvote&vote=up&u=503349&s=70530&n=10&f=138&t=108126&p=899362>)

(<http://www.rxpgonline.com/modules.php?name=usertools&file=pvote&vote=down&u=503349&s=70530&n=10&f=138&t=108126&p=899362>)

(<http://www.rxpgonline.com/modules.php?name=usertools&file=pvote&vote=down&u=503349&s=70530&n=10&f=138&t=108126&p=899362>)

[Reply](#) (modules.php?name=Forums&file=posting&mode=reply&t=108126) [Quote](#) (modules.php?name=Forums&file=posting&mode=quote&p=899362)

[Scrapbook](#) (<http://www.rxpgonline.com/modules.php?name=RxPGites&mode=scrapbook&uid=70530>)

[PM](#) (modules.php?name=Private_Messages&file=index&mode=post&u=)

[Back to top](#)



Syrian (<http://www.rxpgonline.com/threads70530.html>)

(<http://www.rxpgonline.com/modules.php?name=Messenger&file=buddy&op=compose&to=Syrian>)

name=Messenger&file=buddy&op=compose&to=Syrian)

Titan



Posts: 124

Credits: 7019 (<http://www.rxpgonline.com/docs/credits>)

Fri May 21, 2010 10:57 pm (4 years ago) #11 (modules.php?name=Forums&file=viewpost&tid=108126)

March 2006

management of anxiety.

1** a lawyer getting fearful and anxious to talk in public which was affecting her career.

2** a female getting increasingly anxious, tearful and unable to cope with anything., early morning waking and hardly any sleep at night

3** mother had to fly to attend daughter's wedding in 2 weeks but is fearful of getting into plane.

4** man admitted in the ward is delirious.....

5** A young boy (sorry forgotten the age) has a painless soft swelling in the rt. scrotum, it is in colour and compressible.

what is the best management?

1. surgical exploration

2. ct abd.

3. herniotomy

4. reassurance

5. antibiotics

theme: X ray picture for the following clinical pictures

6** driver in a car accident hit the steering wheel, B.p and pulse in both arms were different.

options
widened mediastinum
globular heart shadow.

theme : palliative management.

this is a repeat theme.

7*** man having untractable hiccough
8*** terminal stage breast CA women having malodorous discharge causing trouble.
9*** Lung Ca treated with radiotherapy leads to superior vena cava syndrome.
10** bleeding per rectum following Rx for IBD/ or some such condition with radiotherapy.
11** don't remember.

options:
haloperidol
hyoscine
dexamethazone tablets
prednisolone suppository
metronidazole topical

there were Qs on abd. pain in a female

12***. about a typical presentation of acute appendicitis.
13***. typical presentation of ruptured ectopic
14***. about ruptured peptic ulcer-typical Q.
15***. pancreatitis

theme on urinary retention.

16***. 85yr old bedridden man with palpable distended bladder, stroke pt., with a soft indurated mass felt on the LIF. no loss of wt or bldg p/r.

ans was fecal impaction.

another theme on hematuria.

17***. 55y man with macroscopic hematuria..... i think ans was bladder ca
18***. man has hematuria and mass felt in lt. loin.....i think ans was renal cell ca.
19***. one Q on ureteric colic

theme: Chest X ray findings:

20***- Male with anterior septal infarction---Normal Chest xray
21***- 2- Women undergoing oesophageal dilatation, now unwell -----free mediastinal gas
22***- Patient with Hx of diverticulitis, now present with rigid abdomen-----Gas under diaphragm
23***- Women stabbed in chest---now breathless---Pneumothorax
24***- Patient, fever 39 C, mid zone consolidation---pneumonia

Theme: Oncological Emergencies:

25*** - Fungating odour from breast---metronidazole gel
26***- Haloperidol----intractable hiccups
27*** Man presents with signs of superior vena cava syndrome, has Hx of bronchial Ca--- dexamethazone tablets
28***- Man underwent radiotherapy for prostate CA, now comes with P/R bleeding----Prednisolone
29***- Increased thirst, polyuria, with Hx of some CA-----Bisphosphonates

Theme: Burns:

30***- 2 yr child, can't get I/V line---interosseous line
31***- Child aged 12...can't get IV line---Central venous line
32***- Child with burns on chest, upper limbs 10 %----20 ml /? Bolus
33***- Burns patient with soot, singed nasal hairs, noisy breathing-----Endotracheal intubation
34***- Burns child, low BP-----Dobutamine

Theme: Toxicity:

35***- arrhythmias dry mouth---amyltriptyline
36***- pin point pupils, hypotension-----Morphine
37***- Ataxia, slurred speech ----alcohol
38***- Visual disturbances, bradycardia-----Digoxin
39***- Hypotension only, no dec R/R-----atenolol

Theme: Antibody:

39***- telangiectasias, Raynaud's phenomenon-----Anti centromere Antibody (got this one wrong)
40***- female, pruritis, increased gamma GT-----Antimitochondrial antibody
41***- rash on cheeks, photophobia-----Anti dsDNA
42***- Something about thyroid Sx----anti thyroid peroxidase
43***- Male patient, pale looking, with some paresthesia...?? in lowerlimbs---antibody to intrinsic factor

Theme: orthopaedics:

44***- Achilles tendon rupture-----surgical repair
45***- Child, pain in knee while playing football, next day walking normal, only pain, no swelling

pain not relieved by paracetamol----Ibuprofen

46***- Child, pain in knee, already getting 50% NO and O2, patella found to be laterally shift manipulation???

47***- Female, 14 weeks pregnant, falls, with swelling on ankle-----crutches weight b support

Theme: Inguinal swelling:

48***- female with swelling in inguinal region, abdominal pain and distension---hernia re urgent)

49***- ship yard worker, with discomfort swelling in inguinal region -----Hernai repair (plann

50***- child 9 month old, on crying, swelling appears----Herniotomy

51***- Female with Hx of MI, had hysterectomy done, lower abd scar, swelling protruding be it, reducible-----abdominal support

52***- Male 9 yr old, swelling inguinal region-----Hernia repair (planned

53*** one typical Q about ruptured aortic anuerysm: pulsatile abd. mass with low bp and incr pulse. young man thin and tall.

Qs on imaging of spinal cord lesions like :

54*** .back pain, weakness in knees and ankles.

55*** .some Q about optic neuritis few yrs back and now some lesion.....i m sorry abt this of Qs, i really cannot recall much.

options were

ct brain

mri brain

mri spinal cord.

mri cervical spine

mri lumbar spime

mri lumbosacral spine

xray lumbar spine. WAS THE ANSWER FOR THE YOUNG MAN WITH ANKYLOSING SPONDYLITIS CAN TELL FROM HISTORY)

A repeat theme abt electrolyte imbalance

56*** villous adenoma- hypokalemia

57*** pyloric stenosis , vomitting, dehydration- metabolis alkalosis

58*** post radiation confusion, constipation, thirst in a female rx for breast ca- hypercalcemi

59*** after operation breathlessness and jvp raised.....fluid overload

60*** Child sits at back of class, cant read the black board----spectacles with concave lens

61*** Patient, headache, pain in eye since 2-3 days, dilated and fixed pupil-----Glaucoma si

62*** Patient with SLE on steroids, presents with bilateral opacities-----cataract operatio

63*** Man, can see distant vision well, but cant read newspaperin artificial light----**i thi astigmatism *** cylindrical lens

another repeat theme abt vaginal infections/discharge.

64*** clue cells in the smear of the discharge- bacterial vaginosis.

65*** white discharge in a female which shows mycelia on microscopy- candida

66*** vulval shallow painful ulcers- herpes

67*** last one was iwth h/o PID and on investigation no gonococcus foundans chlam

1

68*** Man with increasing abdominal distention, general condition well, spider nevi present, ' Rx would u like to start-

a-cephalosporin

b-spiroinolactone (is this right)

c-vitamin K

69***

Child brought with 8 hr Hx of sorethroat, saliva dribbling, what to do next?

a- Call anesthetist (right ans) **EPIGLOTTITIS

b- Give penicillin

C- do a mouth examination

70***

Child 18 months old episode of sweet getting stuck up In the throat, has been cleared parents are worried and ask if it happens again, what do we do?

a- hemilich meneuvre

b- back blows with chest compression with patient on laps (right ans)

typical Qs on asthma

71*** pt symptomatic despite using 2-3 times inhaled bronchodilator , also wheeze at night

72*** women with chronic asthma comes with severe wheeze and cough.-nebulised blocker.

73*** pt develpos oral candidiasis while being stable using 1000microg of steroid

74***

Female 68 yrs old, has had a low level Right forearm FRACTURE , what will u do to prevent

fractures in future:?

A calcitonin

B Ca + suppl

C Bisphosphonates (I think this is right b/c acc to OHCS...they reduce risk of hip and wrist #)

D HRT *** IS THIS ALSO AN ANSWER?????

Theme about ENT :

79*** - teacher, presents with hoarseness-----vocalcord nodules

80*** - smoker, 8 weeks Hx of hoarseness-----laryngeal CA

81*** - Hoarseness following thyroidectomy----recurrent laryngeal nerve palsy

82*** - 1 week Hx of resp tract infection, coryza-----acute laryngitis

83*** - Female, husband died 5 weeks agom whispers on and off, can cough normally-----func dysphonia

organisms responsible for:

84*** swollen leg hot, painful and indurated. STREP PYOGENES

85*** axillary abcess STAPH AUREUS

86*** i think there was one on candida ???

87*** pt previously healthy with dry cough, increasing breathlessness, x-ray shows p consolidation all over the lung feild.....(MYCOPLASMA)))

88*** PT ON ANTIBIOTIC develops diarrhoea -> clost. difficile

89*** there was a Q in the hematuria theme:

Asian male with cough and loss of wt shows microscopic hematuria.

ans: kidney TB

There was an SBA:

90*** A man brings his wife into A&E after finding her unconscious at home. He says ti breakfast time, she had complained of a sudden headache and had vomitted. She paracetamol and aspirin for the pain. She is now in A&E with a low GCS.

What is the single most appropriate lnx:

A. ECG

B. Drug levels

C. FBC

D. CT head (right ans)

91*** there was a question regarding a young child with non blanching erythematous papu the lower extremities with facial erythema. what investigation will u do for him????

92*** child with 5 % burns what is the treatment of choice?

93*** child with ??? orbital tumor, as understood from the history, or proptosis, what is th investigation to be done --> CT scan i believe.

94*** and a child whos short for his age with some other features--> not typical of cystic fit but i believe that was the closest answer.

95 *** psychiatry.

the pt whos anorexic. --> compulsory detention was my answer. b/c in ohcs it mentions, if is any danger to one owns life we must detain.

96*** and other psychi question regarding the pt in the medical ward had an operati something done for him. and hes worried or in panic. what method of treatment will u use.

Theme: Toxicity:

97*** - arrythmiasm dry mouth---amyltriptiline

98*** - pin point pupils, hypotension-----Morphine

99*** - Ataxia, slurred speech ----alcohol

100** - Visual disturbances, bradycardia-----Digoxin

101** - Hypotension only, no dec R/R-----atenolol

102** - liver failure after 4 days....paracetamol

Theme: Antibody:

103** - telengectisias, raynaud's phenomena-----Anti centromere Antibody (got this one wro

104** - female, pruritis, increased gamma GT-----Antimitochondrial antibody

105** - rash on cheeks, photophobia-----Anti dsDNA

106** - Something about thyroid Sx----anti thyroid peroxidase

107** - Male patient, pale looking, with some paresthesia.?? in lowerlimbs---antibody to in factor

DEMENTIA THEME (REPEAT)

108** . Most common form of dementia in UK Alzheimer's Dementia

109** . Characterized by neurofibrillary tangles and senile plaques..... Alzheimer's

110** . Hypertensive patient multi infarct
 111** . Respond to anti depressant..... pseudodementia
 112** . Increased disinhibition and preservation of intellect..... frontal

113** one was the SBA for the child who plays football, then developed itchiness - somethir that

114** BEST TIME TO MEASURE SERUM PROGESTERONE FOR MARKING OVULATION

Answer... 21 day Progesterone

115** QUESTION ON HOW TO MONITOR A PATIENT (MOLAR PREGNANCY AS DEDUCED FROM HISTORY)

A) SERUM HCG
 B) URINARY HCG

116** something about a gardener who got a thorn prick...in A&E initial resusc done...getting his finger dressed....and suddenly develops perioral itching ,hunger and colic. He was given anti tetanus and penicillin oral

Answer is anaphylaxis other close option was staphylococcus sepsis but anaphylaxis is da right an options....anaphylaxis...cant remember all of them

117** girl complaining of primary dysmenorrhea

118** women aged 30 complaining of menorrhagia

Options

a. mefenamic acid
 b. TRANEXAMIC ACID
 c. norethisterone releasing IUCD
 D. coep

119** - 123** ANAEMIA THEME

Options

a. iron deficiency due to malabsorption
 b. iron def due to diet
 c. B12 def due to diet
 d. B12 def due to malabsorption
 e. intrinsic factor deficient
 1. person on vegan diet with macrocytosis and anemia b12 diet def.
 2. Pernicious anemia one..... b12 malabsorption
 3. .patient complaining of weight loss, loss stools with microcytic hypochromic anemia with endomysial antibodies positive! iron malabsorption

124** - 127** THEME on Myocardial complications came with choices such as -Ventricular rupture
 -dressers syndrome
 -etc

128** occupational asthma, where the patients symptoms are resolved after he goes on holiday

129** There was also a cardiology theme..... I remember only 1 question something about SV carotid sinus massage and Valsalva man. unsuccessful.....next step.....ADEN (no doubt about that)

130** Pt, 20s, female, with weight loss and loose bowel motion with mucus for 3 months. I abdominal pain also.
 My answer::: Inflammatory bowel DISEASE...

131** Pt, asthmatic, on inhalers of steroids and beta agonists, still symptomatic
 My answer::: Oral theophylline (agree with yasir)

132** elderly pt, after stroke, in some kind of a hostel or elderly care house, developed itching and erythema on her body, lines on her hand and feet.
 My answer::: ***chlorpheniramine*****..

Other questions in asthma theme

133** . pt symptomatic despite using 2-3 times inhaled bronchodilator, also wheeze at night inhaled corticosteroids
 134** . women with chronic asthma comes with severe wheeze and cough....nebulised blocker.
 135** . pt develops oral candidiasis while being stable using 1000 microg of steroid---decreased inhaled steroids

136** A man brings his wife into A&E after finding her unconscious at home. He says that at breakfast time, she had complained of a sudden headache and had vomited. HER MOTHER AT THE AGE 40 SUDDEN DEATH She took paracetamol and aspirin for the pain. She is now in hospital with a low GCS.

IT COULD BE A Ruptured Berry aneurysm --> Subarachnoid haemorrhage.

137** ADULT POLYCYSTIC kidney DISEASE (U make it out from history)

138**- 141** investigation of neck masses

1. branchial cyst
2. cystic hygroma
3. thyroglossal cyst
4. hard thyroid mass

options were

- a. biopsy
- b. fine needle aspiration cytology
- c. ultrasound
- d. aspiration with cytology and microscopy

142** diagnostic x ray finding of a patient with signs and symptoms of tuberculosis. remember the exact scenario

options

- a. apical granuloma on CXR
- b. pleural effusion
- c. bilateral hilar lymphadenopathy --> S A R C O I D O S I S

143** patient with excessive bronchial secretions....not able to expectorate....the answer is hyoscine

144**

A young woman fainted in the street and was brought into A&E. She weighs 33kg. She is also well in A&E and states she is on a diet and admits to not eating or drinking anything for 48 hr. She says she wants to reach her target weight of 30kg. She is annoyed she has been brought to hospital and adamantly states she wants to leave. What is the most appropriate step?

- A. Detain her under the mental Health Act. (CORRECT ANSWER I THINK)
- B. Refer to dietician
- C. Refer to her GP
- D. Allow her to be discharged
- E. I can't remember

145**-147** Diagnosis of Diabetes

- A. Conn's Syndrome
- B. Cushing's Syndrome
- C. Cystic Fibrosis
- D. Diabetes Insipidus
- E. Impaired Glucose Tolerance
- F. Type 1 Diabetes
- G. Type 2 Diabetes
- H. Nephrotic Syndrome

1. A 30 yr old business man has palpitations and urinary frequency. He is sweating. His dipstick is +ve for glucose and ketones. His plasma glucose is 26mmol/L.
ans) type 1 diabetes

2. A 65 yr old woman has a recurrent vaginal itch. she has BMI of 33. Random BLOOD GLUCOSE is 15 mmol/L.
ans) type 2 diabetes

3. A 55 yr old man has glycosuria. After a two hr glucose tolerance test, his plasma glucose is 9mmol/L.
ans) impaired glucose tolerance

148** about salicylate poisoning
determine the acid base abnormality

Options



- a. metabolic acidosis
- b. metabolic alkalosis
- c. respiratory acidosis
- d. respiratory alkalosis

I don't remember, exact stem of the question, but I also chose metabolic acidosis as my answer





149** SBA abt the man with the panic attack?
Rebreath into an airbag IS THE TREATMENT




150** a young child with 5% (I DONT REMEMBER 10%) burns --> CAN ANY1 PLEASE TELL US
THE ANSWER FOR THIS WAS??
WAS ADMISSION ONE OF THE CHOICES?????

151** a man in fire accident with soot particles-anaes help?.

report this post to a moderator (<http://www.rxpgonline.com/report/index.php?p=899364&h=11&u=>)
please rate this post  (<http://www.rxpgonline.com/modules.php?name=usertools&file=pvote&vote=up&u=503349&s=70530&n=11&f=138&t=108126&p=899364>) 
(<http://www.rxpgonline.com/modules.php?name=usertools&file=pvote&vote=down&u=503349&s=70530&n=11&f=138&t=108126&p=899364>)

Back to top

 [Reply](#) ([modules.php?name=Forums&file=posting&mode=reply&t=108126](http://www.rxpgonline.com/modules.php?name=Forums&file=posting&mode=reply&t=108126))  [quote](#) ([modules.php?name=Forums&file=posting&mode=quote&p=899364](http://www.rxpgonline.com/modules.php?name=Forums&file=posting&mode=quote&p=899364))  [Scrapbook](#) (<http://www.rxpgonline.com/module.php?name=RxPGites&mode=scrapbook&uid=70530>)  [PM](#) ([modules.php?name=Private_Messages&file=index&mode=post&u=](http://www.rxpgonline.com/modules.php?name=Private_Messages&file=index&mode=post&u=)

 **Syrian** (<http://www.rxpgonline.com/threads70530.html>) 
(<http://www.rxpgonline.com/modules.php?name=Messenger&file=buddy&op=compose&to=Syrian>)
Titan

Posts: 124
Credits: 7019 (<http://www.rxpgonline.com/docs/credits>)

Fri May 21, 2010 11:00 pm (4 years ago) #12 ([modules.php?name=Forums&file=viewpost&](http://www.rxpgonline.com/modules.php?name=Forums&file=viewpost&)

JANUARY 2006

- 1,question describing skin lesion in one pt who went for a holiday and remember some tick lyme disease
- 2,skin lesion in a man which is there for a long period and now bleeds on touching ---mal melonama ,basal cell carcinama ,squamous cell ca ,pyoderma gangrenosum were the option
- 3-treatment for the newborn with weeping eczema --i think hydrocortisone 1% is the answer
- 4-treatment for broad complex tachycardia with hypotension palpitation chest pain ---(' answer dc cardio version)
- 5,treatment for atrial fibrillation with some pulse rate ---(digoxin is the answer)
- 6-treatment for supraventricular tachycardia with pulse rate 240-(adenosine i have written)
- 7-question abt pt taking antibiotic for pneumonia and developing diarrhoe and mucu (pseudomembraneous colitis)
- 1 child with pertussis - appropriate drug, there was erythromycin and others
- 2 child with exercise-induced asthma well controlled initially with B2 bronchodilator but several doses of same drug with no good effect, what next to give - Na cromoglycate, ir salmetrol, and others
- 3 Pre-op management of some conditions - healthy Afrocaribbean for inguinal hernia investigation required, sickling test etc
4. preop for a prosthetic cardiac valve patient (i think for cystoscopy)
5. RTA head-on collision with hypotension and widened mediastinum - ruptured oesoph ruptured aorta etc
- 6.Those questions on head injury diagnosis - extradural hematoma, SAH, chronic sub hematoma, brainstem injury, this wasnt difficult.
7. man with mild led oedema, papulovesicular rash all over the body non blanching with necrotic ones - diagnosis; herpes zoster, systemic vasculitis, meningococcal septicemia etc (crazy question)
8. many questions on Psychiatry - unfamiliar and familiar ones like the female lawyer confidence in self and believes shes a failure - appropriate management
- 9 postnatal woman with some delusional problems - believes husband is planning harming her and baby - appr mgt
- 10 Those popular stab injuries on the chest and abdomen with hypotension - most management
11. question on testicular torsion - immediate mgt, there was our usual option of surgical exploration and others
12. question on testicular tumor - diagnosis from a histological description
- a man has atrial fib and mitral stenosis also found to have finger clubbing and splenic haemorrhages. i answered - infective.

2- A homeless man has cardiac failure also has spider naevi on his chest cxr shows very large his bp is normal.

3- Man with several episodes of fainting echo demonstrated aortic valves has two cups. congenital.

4- Woman has recently had mitral valve prosthesis inserted develops high temp severe cardiac failure and a new cardiac murmur. I did infective

- A woman has pallor and abdominal pain and floating stools. She previously was a tennis player but now she can not finish the full game her diet is ok. Thyroid function test and endo antibodies were the options.

1-a brain tumour with some histology which says some psammoma bodies in it

2-a question abt the lesion between internal carotid and middle cerebral artery ...is it aneurysm

-the following question abt the antenatal diagnosis ,

3-hypothyroidism

4-e previous baby with jaundice and anaemia and now mother worried abt the present fetus is the investigation

5-cystic fibrosis
Retention of urine.

1- man living on his own who has been constipated for the last 3 years developed urinary incontinence his bladder is painlessly enlarged to the level of umbilicus and the sigmoid colon easily palpable.

I did - Faecal impaction

1- brain showing multiple areas of demyelination.

Ans: multiple sclerosis.

2- circumscribed lesion composed of a gland like structures lined by columnar cells pleomorphic nuclei.

Ans: secondary carcinoma.

3- a mass indenting the surface of the brain and on microscopy exam: composed of elongated cells with regular nuclei. Psammoma bodies are seen.

Ans: meningioma.

4- a wedge shaped area of discoloration occupying both grey and white matter.

Ans: infarct.

5- a lesion at the junction of internal carotid and middle cerebral arteries.

Ans: berry aneurysm

Child of 5 years of age: picks up objects in his palm, but not between finger and thumb, resists to parents, but is afraid of strangers, sits assisted, but not unassisted, he coos but has no words

Your dx:

- a. motor delay
- b. global delay
- c. social delay
- d. language delay
- e. normal

I chose normal

Lower GI bleedz.

1- woman in the hospital being treated for persisting pneumonia with prolonged course antibiotics the fever recurs and she develops bloody diarrhoea with mucus.

Ans: pseudomembranous colitis.

2- woman with bright red rectal bleeding the blood is on the surface of the stool and also spatters in the toilet she has a long h/o constipation with passage of hard faeces.

Ans: Haemorrhoids.

3- a man age more than 70 with 4 months h/o increasing frequency of defecation also complains of urgency and sensation of incomplete evacuation.

Ans: rectal ca.

4- woman with recurrent bloody diarrhoea 2 minor but similar episodes 2 years previously.

Ans: ulcerative colitis.

5- woman returns from overseas holiday develops fever and diarrhoea. After returning to UK she noticed fresh blood mixed with stools.

Ans: Campylobacter infection.

Upper GI conditions.

1. A disease characterised by metaplasia from squamous epithelium to columnar epithelium.
- Barrett's

2. Abnormal oesophageal motility bc of a loss of ganglion cells in Auerbach's plexus
- Achalasia.

3. a disease characterised by post cricoid web arising with iron deficiency anaemia.
- Plummer-vinson synd.

4- a disease char: by displacement of part of the stomach in to the thorax.
- Hiatus hernia.

5- a disease char: by accumulation of hyalins fibrous tissue in the submucosa of the viscus.
- Scleroderma

a man 80 years old smoked heavily for many years is waiting to be admitted to the hospit
resection of bladder tumour he suddenly unable to pass urine and has lower abd: pain.
- Ans: clot retention.

- a man smoked since child hood has had haemoptysis has lost weight and has a shadow
chest x-ray following a fall he has developed sensory loss in both legs and has difficulty in w
he also is unable to pass urine.

- Ans: spinal cord compression.

- A man with h/o haematuria marked nocturia and urine diffculty his PSA is elevated ar
ultrasound shows residual urine of 400 ml.

- Ans: BPH

HERNIA MANAGEMENT.

- Man 3 months h/o right groin swelling he is otherwise fit takes regular exercises has no
medical history. Exam: confirms rt: inguinal hernia.
Ans: no investigation.

- an African Caribbean has bilat: inguinal hernias his hb is 11 g/lit.
ans: sickle cell testing.

- man is admitted for the repair of left inguinal hernia he regularly uses recreational
administered intravenously.
- Ans: hepatitis screen.

- woman is to undergo right femoral hernia. Previously had severe bleeding after a
extraction.
Ans: coagulation screen
Adverse drug effects.

- A man with longstanding h/o schiophrenia treated with an antipsychotic agent. He compla
a sore throat and fever and have a low blood count wbc and reduced neutrophils.

Ans: clozapine.

- A pt receiving treatment for bipolar affective disorder his tsh level is increased and t3
levels are reduced.

Ans: lithium.

- Pt: having extrapyramidal effects complains of reduced sexual libido and erectile impoten
prolactin is raised.

Ans: chlorpromazine.

A pt on treatment for depression complains of dry mouth, blurred vision, constipatio
tremors.

Ans: Amitriptyline.

- Pt: with h/o of schizophrenia receiving an antipsychotic agent becomes physically unwell
found to have an elevated body temp: unstable blood pressure excessive sweating and a
white blood cell count and raised cpk.

Ans: chlorpromazine

a cyclist had an rta. he had an injury. he was wearing a helmet... the choices were.. fractu
the base of the skull. sub dural haemorrhage, intra cerebral haemorrhage, occipital etc..
remember much..

there was another.. a patient had her bp checked a few days back. she was normal.. a cou
days later her bp rose up..

Diagnosis of emergencies.

- an 17 year old boy collapsed in the street and was brought by ambulance to A&E on arrival
unconscious his pulse is 50 and regular. His bp: 90/60 he has constricted pupils are non react
light his R/R is 4 beats/min.

- ans: Opiate overdose.

- 17 years old girl attends the A&E she is abusive and tearful. She states that she has lo
regular medicine. Se complains of severe aches and pins all over and she cannot sleep
demands immediate pain relief.

- Ans: Opiate withdrawal

A girl in A&E complaining of difficulty in breathing her pulse is 86 and regular. Her R/R is 20 and peak flow rate is 450. she is frightened and describes pins and needles in her hands and face.

ans: panic attack

:-1) management of labour:

a:- patient at term,has passed meconium, cervix is 3 cm dilated.

b:- patient at term,head had been delivered, but baby has shoulder distocia.

c) patient at term,membranes ruptured,meconium passed. cervix 3 cm dilated.

4) patient with previous h/o of HT,membrane ruptures,meconium passed. cervix is 3cm dilated

Theme 5 Investigation of Unconsciousness

Options

- a. CT scan
- b. MRI scan
- c. Blood Glucose
- d. Toxicology Screen
- e. Xray Skull
- f. U&E
- g. Blood Alcohol

Questions

19. 21 year old Female found unconscious next to her 22 year old husband, who was dead. Her ECG shows evidence of Acute MI

20. 42 year old Female, previously normal, was suddenly found unconscious. Brought to the hospital shows respiratory depression, dilated fixed pupils and extensor plantar response

21. 21 year old rugby player, had suffered from an episode of brief unconsciousness. Comes to A&E the next day with paresthesias of the left arm.

my answers

- 19. toxicology screen
- 20. toxicology screen
- 21. CT scan

Pt: with h/o of schizophrenia receiving an antipsychotic agent becomes physically unwell found to have an elevated body temp: unstable blood pressure excessive sweating and a white blood cell count and raised cpk.

Ans: chlorpromazine.

young man in his early twenties comes to see you, he is in good health, but his girlfriend reports that he looks jaundiced from time to time. I don't believe you find anything on exam. investigation do you choose.

I'm interested in finding out what other people thought about this question. I assumed Gilbert's syndrome and as such chose unconjugated bilirubin as the investigation, but I could be certain. Your thoughts?

Next management in the following conditions

- A- USG abdomen
- B- Catheterisation
- C- Ascending urethrogram
- D- Splenectomy
- E- Laparoscopy
- F- Observation
- G. Abdominal tapping
- H. Laparotomy
- I. Blood transfusion
- J. Get an expert opinion
- K. IVU
- L- MRI

A rugby player was hit in the back & come with loin pain & haematuria. management

Young man with one episode of frank haematuria & he was stable but presented with anuria.

A male with anuria brought to A&E after injury with bruising on perineum, the digital rectal exam was normal next step

A pt with h/o RTA have FRACTURE of Left lower ribs. Pt is having left sided abdominal pain with progressive guarding of Left hypochondrium. O/E, PR=110/min & BP 90/60. What is the next

q 120 i was thinking at usg to see if there is any damage,but why not ivu?

121. catheterization or ascending urethrogram. i don't know which one is more indicated here it is a case of trauma. it could be a urethra rupture. one episode of frank hematuria and after anuria.so? could it be urethra rupture?

Pt with frank hematuria and kick to back, I was puzzled by. Didn't think the u/s abdomen would do us much good (as kidneys are retroperitoneal), and wasn't sure that IVP was a good option as it may spill blood into body cavity if a major artery had been avulsed. I believe I cut my losses and chose nephrectomy and moved on quickly.

The gentleman with anuria, injury and a bruised perineum. I can't remember what I chose, honesty, perhaps MRI or some other imaging. I stayed away from anything that required catheter insertion (including catheterization) as I believe this is CONTRAINDICATED in possible urethra damage/rupture (as you may inflict more damage with the insertion).

The hypotensive man with fractured left lower ribs. I presumed injured spleen and was hemodynamically unstable as a result. Figured the best way to get control of bleeding would be to do an emergency splenectomy

report this post to a moderator (<http://www.rxpgonline.com/report/index.php?p=899367&h=12&u=>)

please rate this post (<http://www.rxpgonline.com/modules.php?name=usertools&file=pvote&vote=up&u=503349&s=70530&n=12&f=138&t=108126&p=899367>)

(<http://www.rxpgonline.com/modules.php?name=usertools&file=pvote&vote=down&u=503349&s=70530&n=12&f=138&t=108126&p=899367>)

Back to top

[Reply](#) ([modules.php?name=Forums&file=posting&mode=reply&t=108126](http://www.rxpgonline.com/modules.php?name=Forums&file=posting&mode=reply&t=108126)) [Quote](#) ([modules.php?name=Forums&file=posting&mode=quote&p=899367](http://www.rxpgonline.com/modules.php?name=Forums&file=posting&mode=quote&p=899367))

[Scrapbook](#) (<http://www.rxpgonline.com/modules.php?name=RxPGites&mode=scrapbook&uid=70530>)

[PM](#) ([modules.php?name=Private_Messages&file=index&mode=post&u=](http://www.rxpgonline.com/modules.php?name=Private_Messages&file=index&mode=post&u=))

Fri May 21, 2010 11:03 pm (4 years ago) #13 ([modules.php?name=Forums&file=viewpost&](http://www.rxpgonline.com/modules.php?name=Forums&file=viewpost&))

 **Syrian** (<http://www.rxpgonline.com/threads70530.html>)

(<http://www.rxpgonline.com/modules.php?name=Messenger&file=buddy&op=compose&to=Syrian>)

Titan



Posts: 124

Credits: 7019 (<http://www.rxpgonline.com/docs/credits>)

May 2005 Exam

Theme 1: Abdominal Injury

- A. Aortic rupture
- B. Splenic rupture
- C. Diaphragmatic rupture
- D. Cardiac tamponade
- E. Renal contusion
- F. Renal pedicle avulsion
- G. Bladder rupture
- H. Pancreatic rupture

1. A Boy was riding his bicycle when he was hit by a car. After examination in the A & E, he was found to have left upper quadrant tenderness.

2. A Man fell off a ladder, has diffuse pain on right side of the trunk. IVU shows no excretion in the right side.

3. A Man was stabbed with a 10cm knife in the left upper quadrant, stable for 20min after surgery. BP falls to 90/60mmHg. On USG, no free fluid seen in abdomen.

Theme 2: Diagnostic visual tests

- A. Colour vision test
- B. Computed tomography (CT) scan of the brain
- C. Electroencephalogram (EEG)
- D. Erythrocyte sedimentation rate (ESR)
- E. Full blood count FBC
- F. Intraocular pressure measurement
- G. Serum calcium concentration
- H. Serum urea and electrolyte concentration
- I. Visual acuity assessment
- J. Visual field mapping

4. A 76-year old woman presents with symptoms of feeling generally unwell and anorexia, weight loss. She complains of sudden loss of vision in her left eye. On the left side the pupillary light reaction is sluggish.

5. A 40-year-old woman presents with sudden onset of severe occipital headache photophobia and vomiting.

6. A 22-year-old woman complains of afternoon headaches, which have progressively worsened. She works as a visual display unit (VDU) operator.

7. A 72-year-old woman presents with tunnel vision and severe headache, nausea and vomiting of recent onset. She has noticed colored haloes for six-months.

8. A 27-year-old woman presents with severe morning headaches for two months. Full neurological examination is normal apart from bilateral papilloedema. Her blood pressure is 120/70-mmHg

Theme 3: Needle Stick Injuries

- A. CD4 count
- B. Full blood count (FBC)
- C. Hepatitis-B core antibody
- D. Hepatitis-B 'e' antibody
- E. Hepatitis-B 'e' antigen
- F. Hepatitis-B 'surface' antigen
- G. Hepatitis-C antibody
- H. Hepatitis-C ribonucleic acid (RNA) antigen
- I. Human immunodeficiency virus (HIV) antibody test
- J. Human immunodeficiency virus (HIV) viral load
- K. Liver function tests (LFTs)
- L. Retain serum sample
- M. Thick blood film

9. A nurse suffers a needle stick injury while taking blood from a patient known to have late human immunodeficiency virus (HIV). Post exposure prophylaxis with analysis is being considered. However, the nurse now admits to the possibility of already being HIV positive.

10. A nurse, who is known to be hepatitis B immune, suffers a superficial scratch while taking blood from a patient. The patient's own hepatitis and human immunodeficiency virus markers are negative. The nurse is advised to have a human immunodeficiency virus antibody test in three months time.

11. A doctor suffers a needle stick injury while taking blood from a patient said to be a chronic hepatitis-B carrier. The patient needs a test so that the doctor can be advised of his risk of acquiring hepatitis-B infection.

12. A doctor suffers a needle stick injury while taking blood from a patient known to be hepatitis C antibody positive. The doctor needs a test to know his Hepatitis-C status.

Theme 4: Terminal Care

- A. Bisphosphonates intravenously
- B. Cyclizine injection
- C. Dexamethasone tablets
- D. Haloperidol injection
- E. Hyoscine injection
- F. Indomethacin suppositories
- G. Loperamide capsules
- H. Metronidazole gel
- I. Midazolam injection
- J. Nystatin suspension
- K. Peithidine injection
- L. Prednisolone suppositories

13. A 57-year-old man with carcinoma of the bronchus develops superior vena cava obstruction following radiotherapy.

14. A 49-year-old man with metastatic carcinoma has intractable hiccoughs.

15. A 49-year-old woman has fungating malodorous breast cancer. The odor is distressing to her and her relatives.

16. A dying 57-year-old man with bronchial carcinoma is unable to cough bronchial secretions.

17. A 78-year-old man has a bloody rectal discharge following radiotherapy for carcinoma of the prostate.

Theme 5: Fractures in Children

- A. Fracture of clavicle
- B. Fracture of mid radius and ulna
- C. Fracture of neck of humerus
- D. Fracture of shaft humerus
- E. Buckle fracture of distal radius
- F. Non-accidental injury
- G. Scaphoid fracture
- H. Subluxation of radial head (pulled elbow)
- I. Supra condylar fracture of humerus

18. A seven-day-old girl baby, born after a difficult home delivery, is not moving her left arm. She cries each time she is picked up.

19. A three-year-old girl tripped while holding her mother's hand. She has not used her right arm since.

20. An eight-year-old boy fell from a tree. He is in severe pain. The radial pulse is not palpable in the injured arm.

21. A 16-year-old boy fell on his outstretched hand. His forearm was put in a plaster cast a week ago.

another hospital and he has got it well. He has come to the Accident and Emergency Department to have it repaired. He says his initial x-rays were normal. On repeat x-ray an abnormality was found.

22. A four-year-old boy fell in the playground. He has been using forearm normally but complains of pain. There is no deformity or swelling and there is minimal tenderness on examination.

23. A three-month-old baby. Whose mother says he has been crying since he rolled off the cot two days ago, is found to have bruises on his legs.

Theme 6: Natural history of Epistaxis

- A. Anticoagulant overdosage
- B. Coagulopathy
- C. Hypertensive disease
- D. Local infection
- E. Maxillary antral carcinoma
- F. Nasal polyposis
- G. Nasopharyngeal angiofibroma
- H. ORF
- I. Sarcoidosis
- J. Septal perforation
- K. Trauma

24. A 50-year-old man presents with epistaxis. He has an artificial heart valve.

25. A 50-year-old furniture maker presents with anesthesia of the left cheek and repeated episodes of epistaxis.

26. An actor presents with repeated episodes of epistaxis as associated with whistling while breathing in through the nose.

27. A 45-year-old sheep farmer presents with unilateral epistaxis. Inspection reveals a bleb polyp attached to the anterior nasal septum.

28. An 80-year-old man presents with epistaxis of two hours duration.

Theme 7: Endocrine Abnormalities

- A. Adrenaline
- B. Adrenocorticotrophic hormone (ACTH)
- C. Aldosterone
- D. Calcitonin
- E. Cortisol
- F. Follicle stimulating hormone (FSH)
- G. Glucagon hormone
- H. Insulin
- I. Luteinising hormone (LH)
- J. Prolactin
- K. Serum parathyroid hormone
- L. Somatostatin
- M. Testosterone
- N. Thyroid stimulating hormone (TSH)
- O. Thyrotrophin releasing hormone
- P. Thyroxine

29. A 55-year-old woman presents with increasing obesity. On examination, she has central obesity with a round moon face.

30. A 42-year-old man is found at routine medical examination to have a blood pressure of 170/110 mm Hg. He has been complaining of intermittent headaches, palpitations and intermittent diarrhoea for some months.

31. A 60-year-old woman is found to have an elevated calcium level on a routine biochemical profile. Repeated measurements confirm the finding.

32. A 40-year-old man presents with thirst, polyuria and marked muscle weakness. His blood pressure is 150/110 mmHg. His serum sodium concentration is normal and his serum potassium concentration is low. His blood glucose is normal.

Theme 8: Pain relief

- A. Acupuncture
- B. Bolus of intravenous opiate
- C. Carbamazepine
- D. Corticosteroid
- E. Hypnotherapy
- F. Intramuscular non-steroidal anti-inflammatory drugs
- G. Oral non-steroidal anti-inflammatory drugs
- H. Oral opiate
- I. Proton pump inhibitor
- J. Selective serotonin re-uptake inhibitor
- K. Simple analgesic
- L. Subcutaneous opiate infusion

M Transcutaneous electrical nerve stimulation (TENS) machine
N Tricyclic antidepressant drug

33. A 70-year-old man presents with severe, retrosternal chest pain and sweating. Electrocardiogram (ECG) shows acute myocardial infarction.

34. A 70-year-old man with inoperable gastric cancer causing obstruction, and multiple metastases, is taking a large dose of oral analgesia. Despite this, his pain is currently controlled.

35. A 30-year-old woman has just been diagnosed as having rheumatoid arthritis and a rheumatologist has begun giving her gold injections. She continues to complain of joint pain and stiffness, particularly for the first two hours of each day.

36. A 60-year-old man with a known hiatus hernia presents with recurrent, severe, retrosternal chest pain associated with acid regurgitation and increased oral flatulence.

37. An 80-year-old woman reports severe paroxysms of knife-like or electric shock like lasting seconds, in the lower part of the right side of her face

Theme 9: Differential Diagnosis of Ectopic Pregnancy

- A. Appendicitis
- B. Inevitable miscarriage
- C. Missed abortion
- D. Septic abortion
- E. Acute PID
- F. Diverticular disease
- G. Torsion of an ovarian cyst
- H. Irritable bowel syndrome
- I. Incomplete abortion
- J. Ectopic pregnancy

38. A pregnant woman with an LMP of 9 weeks and a positive home pregnancy test presents with an enlarged tender uterus and bright red bleeding per vagina. On examination her cervix is fully open.

39. A 16 year old with right iliac fossa pain has a vaginal ultrasound which demonstrates an echogenic cystic mass just superior to the right fornix.

40. An 18 year old girl is doing her exams and is very stressed. She has missed her last period. A pregnancy test is negative. She complains of a three month history of generalised abdominal pain and bloating.

41. A 22 year old girl with a history of two terminations of pregnancy, now pregnant, complains of right iliac fossa pain and a watery brownish vaginal discharge.

42. A 27 year old girl relying on oral contraceptives develops a high white cell count, fever and malodorous vaginal discharge.

Theme 10: Bites and Stings

- A. Thick and thin blood film
- B. Chest Xray
- C. Full blood count
- D. Hepatitis A serology
- E. Hepatitis B serology
- F. Leptospirosis serology
- G. Lyme disease serology
- H. MRI Skull
- I. Nasal swab
- J. Skin prick test
- K. Skin swab culture

43. A 28 year old police officer is bitten by a heroin addict during the course of an arrest. The police officer presents to A&E with a deep wound on his right hand.

44. A 16 year old girl has a lesion on her right leg. She removed an insect from her leg while walking through a forest 3 weeks ago. The lesion is red and raised.

45. A 52 year old business man presents to A&E with fever and rigors ten days after returning from a trip to Zambia.

Theme 11: Jaundice in Childhood

- A. Alpha 1 anti-trypsin deficiency
- B. Biliary atresia
- C. Breast milk jaundice
- D. Congenital spherocytosis
- E. Galactosemia
- F. Congenital viral infection
- G. G6PD Deficiency
- H. Hepatitis A infection
- I. Hypothyroidism

- J. Physiological jaundice
- K. Rhesus haemolytic disease
- L. UTI

46. A previously well 10 year old girl presents with 2 day history of fever, nausea, anorexia, stools. She has yellow sclerae and is tender in the right upper quadrant on abdominal palpation.

47. A baby becomes jaundiced and pale on the 2nd day of life. Cord blood tested at birth Coombs' test positive.

48. A one month bottle fed baby is found to be deeply jaundiced. His weight gain is poor and stools are pale and urine is dark yellow.

49. A two month baby is noted to have jaundiced, He is breast feeding well and has gained weight, His stools are yellow and his urine is pale straw coloured.

Theme 12: Infectious Diseases

- A- Lyme disease
- B- Brucellosis
- C- Plasmodium vivax
- D- Plasmodium falciparum
- E- Plasmodium Malaria
- F- Tuberculosis
- G- Lymphoma
- H- Bronchial CA

50. A patient coming back from holiday in a farm presents with malaise & fevers & splenomegaly

51. A patient coming back from Africa complains of recurrent fevers, loss of appetite & fits

52. A patient presents with fevers night sweats & malaise & lymphadenopathy

53. A patient with haemoptysis & cough story like TB but chronic without travel history

Theme 13: Pre-Operative Investigations and Preparations

- A- Stop smoking
- B- Refer to alcohol dependency group
- C- Give Vitamin K
- D- Stop Smoking
- E- S/C heparin
- F- Withdraw some blood Pre-Op
- G- Empty bowels Pre-Op
- H- Total Bed Rest Pre-Op
- I- Antibiotics Pre-Op
- J- Admission to addiction Center,
- K- Loose weight

54. A patient has to undergo a hernia repair and has been given graduated compression stockings

55. A patient is going to have femoral neck replacement & is obese

56. A woman who is at term needs analgesia for pregnancy termination

57. Patient with incisional hernia, BMI - 28 planned for repair & smokes 40 cigarettes

58. Patient with to be operated for thyroid drinks 30 units alcohol

59. A 60-year-old man with BMI 34, who drinks 20-units of alcohol per day & smokes cigarettes/day for the last 5 years going for a hip replacement surgery which will last for > 1 hrs

Theme 14: Management of Trauma in Children

- A. I/V morphine.
- B. Endotracheal intubation.
- C. Intraosseous line.
- D. CV line
- E. Oropharyngeal airway.
- F. Nasopharyngeal airway.
- G. Dobutamide.

60. A 4 yr. Old child with 10 % scalds on chest.

61. 2 yr. Old with hypovolemic shock, unable to get iv access.

62. 13 yr. Old in shock, unable to get iv access.

63. 6 yr. Old, intubated after RTA, BP low, pulse high

Theme 15: Psychiatry - Next step

- A. Chlorpromazine.
- B. Clozapine.
- C. ECT
- D. Benzhexol.
- E. Continue the same drug orally.
- F. Stop the treatment.
- G. Hyoscine.
- H. Stop the drug
- I. Review medication

64. A patient after treatment with antipsychotic says he develops hyper salivation.

65. A patient after treatment with haloperidol, a man develops stiffness of limbs.

66. A patient stabbed his father in acute psychosis, & then was treated with anti psychotic believes himself to have recovered from the illness.

67. A patient who has recurrent hiccups, due to anti psychotic treatment

Theme 16: Toxicology - side effects

- A- Salicylates
- B- Paracetamol
- C- Metoclopramide
- D- Opioids
- E- Tricyclic Antidepressants
- F- Digoxin
- G- CO
- H- Diazepam
- I- Carbamazepine.

68. Development of hepatitis 3-4 days after indigestion

69. Dystonia, oculogyric crisis

70. Pinpoint pupils respiratory depression, bradycardia

71. Women on neuropsychiatric drugs at night now c/o agitation & dizziness

72. Visual problems, & bradycardia

Theme 17: Anatomy of Heart

- A- Left atrium
- B- Right atrium
- C- Left ventricle
- D- Right ventricle
- E- Mitral valve
- F- Tricuspid valve
- G- Coronary arteries
- H- Interatrial septum
- I- Interventricular septum
- J- broncho pulmonary dysplasia
- K- SA-node
- L- AV-node
- M- Bundle of His

73. Endocarditis in IV drug abuser

74. Patent foramen ovale

75. Site of Cardiac aneurysm

76. Complete heart block

77. Some question regarding Mitral valve

Theme 18: Thyroid Disorders

- A. Anaplastic carcinoma
- B. Follicular Ca
- C. Papillary Ca
- D. Hashimoto's thyroiditis
- E. Thyrotoxic goitre
- F. Autoimmune hypothyroidism
- G. Drug induced thyrotoxicosis.

78. Female, 41 yrs old, presents with hard, irregular fixed swelling, stridor, dysphagia since months.

79. Old lady with smooth neck swelling, bradycardia, sparse coarse hair, macrocytic anemia.

80. Female on treatment for supraventricular tachycardia C/O seeing dots & glare on drive at night, exophthalmos, no goitre.

81. Female, swelling in the neck, tremor irritability, diarrhoea, bruit.

Theme 19: Treatment of Menstrual Disorders

- A. COCP
- B. Tranexamic acid
- C. Mefenamic acid
- D. Levonorgestrel containing pills
- E. Norethisterone
- F. Danazol
- G. Myomectomy
- H. Hysterectomy
- I. IUCD
- J. Mirena coil

82. A 13 year old school girl presents with primary dysmenorrhoea who skips school because of pain.

83. A 30 year old with heavy painless bleeding with regular cycles but with passage of clots.

84. A 25 year old girl presents with irregular cycles with heavy painless bleeding

Theme 20: Diagnosis of Dementia

- A. Alzheimer's dementia
- B. Alcoholic dementia
- C. Huntington's chorea
- D. Creutzfeldt-Jakob's disease
- E. Pick's disease
- F. Lewy body dementia
- G. Multi infarct dementia
- H. HIV
- I. Frontotemporal dementia

85. A 40-year-old lady with right handed involuntary writhing movement with strong family history

86. A 55-year-old man with no previous history of disease brought to A&E by his wife who says that he has become progressively more forgetful tends to lose his temper and emotionally labile

87. A 77-year-old man with weakness in his arm and leg from which he recovered within few days but with short term memory loss has extensor plantar response. He has similar episodes 2 yrs ago and became unable to identify objects and make proper judgments

88. A 70-year-old man with early loss of speech and memory with visuospatial orientation preserved

Theme 21: Rectal Disorders

- A. Angiodysplasia
- B. Inflammatory bowel disease
- C. Hemorrhoids
- D. Diverticulosis
- E. Carcinoma rectum
- F. Carcinoma caecum
- G. Anal fissure
- H. Ulcerative colitis
- I. Crohn's disease

89. A patient with myocardial infarction develops sudden severe bleeding per rectum. PR normal

90. A young patient with chronic diarrhea presents with bleeding per rectum

91. A 40-year-old man with painful defecation and blood streaked in the stool

92. A pt with chronic diarrhea and left iliac fossa pain presents with bleeding per rectum, tenesmus and mass in the rectum.

Theme 22: Investigations of Renal Problems

- A. Ascending urethrogram
- B. Micturating cystourethrogram
- C. IVU
- D. KUB Film
- E. DEXA scan
- F. CT Scan - Pelvis
- G. MRI
- H. Mid stream urine culture
- I. Trans urethral resection of prostate
- J. Trans rectal biopsy of prostate

93. A 30-year-old woman fractured her pelvis following a road traffic accident five years ago and is experiencing increasing difficulty in passing urine

94. An 80-year-old man has been admitted from long stay residential care with a history of diarrhoea and recent inability to pass urine

95. An 80-year-old man has a two-month history of intermittent haematuria, low back pain and a high prostate specific antigen.

96. A patient presents with lower abdominal pain, mild haematuria. The IVU shows an opacity in the lower portion of the bladder.

Theme 23: Diagnosis of Hearing Loss

- A. Noise induced hearing loss
- B. Presbycusis
- C. Otosclerosis
- D. Acoustic neuroma
- E. Otitis media
- F. Drug induced hearing loss

97. Patient with unilateral sensory neural hearing loss

[snip]. Patient with bilateral sensori neural hearing loss which resolved spontaneously.

99. Patient with bilateral conductive hearing loss with family history of hearing loss

100. Patient with bilateral sensori-neural hearing loss.

Theme 24: Investigations for Cervical cancer

- A Cancer cell surface antigen 125 (CA 125)
- B Cervical smear
- C Colposcopy
- D Day 21 progesterone
- E Endometrial sampling
- F Full blood count (FBC)
- G High vaginal swab (HVS)
- H Laporoscopy
- I Pregnancy test
- J Serum estradiol concentration
- K Serum follicle stimulating Hormone (FSH)
- L Vaginal ultrasound

101. A 68-year-old woman presents with a single episode of post-menopausal bleeding.

102. A 20-year-old woman who has been using the oral contraceptive pill has had three episodes of bright red post coital bleeding.

103. A patient who has had a cervical smear one year back now presents with bleeding.

Theme 25: Investigations of Breast disease

- A. FNAC
- B. Mammography
- C. Ultrasound
- D. BRCA-1&2
- E. Triple examination (palpation, scan, cytology)
- F. Reassurance
- G. Antibiotics
- H. Incision and drainage

104. A 55-year-old woman presents with a two-month history of a lump in her right breast. On examination there is a firm, irregular lump in the upper outer quadrant of the right breast. In addition, there are small, palpable mobile nodes in the right axilla.

105. A 20-year-old female student presents to the breast clinic having noticed lumps in both breasts, which has been painful pre-menstrually.

106. A 75-year-old woman presents to the breast clinic having noticed that she has had a bloody stained discharge from the left nipple, together with 'dry skin' over the left areola. On examination there was a blood stained discharge with dry, flaky skin noted on the left areola. No lump in the nipple was noted to be ulcerated.

107. A patient who has no complaints but the radiologist found some calcification in both breasts on the Chest Xray

Theme 26: Treatment of Pneumonia

- A. Erythromycin
- B. Tetracycline
- C. Flucloxacillin
- D. Benzyl penicillin

- E. Prednisolone
- F. Rifampicin+Isoniazid+Pyrazinamide and Ethambutol
- G. Cotrimaxazole
- H. Ciprofloxacin
- I. Salbutamol inhaler

108. A 30 year old man with AIDS presents with fever, dry cough and dyspnoea. CXR shows bilateral alveolar and interstitial in the perihilar region.

109. A 20 year old student with fever, malaise and dry cough presents with bilateral perihilar consolidation.

110. A woman working in a parrot shop complains of fever, dry cough and breathlessness.

111. A man just returned from a conference with fever, dry cough and patchy consolidation.

Theme 27: Causes of Haemoptysis

- A. Pulmonary edema
- B. Tuberculosis
- C. Mitral stenosis
- D. Foreign body inhalation
- E. Pulmonary embolism
- F. Bronchogenic carcinoma
- G. Pneumonia
- H. Bronchiectasis
- I. Good Pasture's syndrome

112. A woman post surgery presents with severe chest pain, shortness of breath and haemoptysis.

113. A 55 yr old smoker with a history of recurrent chest infections presents with haemoptysis and greenish sputum. He had clubbing.

114. A 70 year old smoker presents with cough, haemoptysis and weight loss. There is clubbing.

115. A patient presents with cough, haemoptysis and haematuria.

Theme 28: GIT

- A. Ulcerative colitis
- B. Crohn's disease
- C. Irritable bowel syndrome
- D. Carcinoma caecum
- E. Sigmoid carcinoma
- F. Rectal Carcinoma
- G. Coeliac disease
- H. Gall stones

116. A 40 yr old obese multiparous woman presents with malabsorption of fat food and flatulence.

117. A disorder which began at a young age with systemic manifestations which improved following a certain diet.

118. A low residue diet causes this associated with bleeding per rectum.

SINGLE BEST QUESTIONS

119. A mother brought her child 2 hrs after paracetamol ingestion. When do you check the levels?

- A. After 2 hrs
- B. After 4 hrs
- C. After 1 hr
- D. After 8hrs

120. A mother wants to know the risk of their second child developing cystic fibrosis.

- A. No risk
- B. 1:8
- C. 1:2
- D. 1:4

121. A random study on Pulmonary embolism shows 10 pt. out of 1000 died who did not get treatment 5 pt out of 1000 died who got proper treatment

- A. Absolute risk 5%
- B. Absolute risk 10%
- C. Absolute risk 2 %
- D. Relative risk 5%
- E. Relative risk 10%

122. A Type 2 Diabetic, BP 140/90, raised creatinine, ankle oedema which Anti hypertensive would you prescribe?

- A. Thiazide diuretics
- B. Beta blockers

- C. Calcium channel blockers
- D. Potassium sparing diuretics

123. Calculation of Trimethoprim dosage for a child... quite straight forward

124. A woman with long standing Rheumatoid arthritis on Naproxen and Methotrexate.... Wi 8mg/dL and few more values.. What type of anemia

- F. Aplastic anemia
- G. Anemia of chronic disease
- H. Iron deficiency anemia
- I. Macrocytic anemia

125. Interpretation of ABG -

pH : 7.2
pCO2: 4kpa
pO2: 10kpa
Base excess: -15

- A. Metabolic alkalosis
- B. Metabolic acidosis
- C. Respiratory Acidosis
- D. Respiratory Alkalosis

126. A patient is back from Africa after holidays presents with fever, night sweats, neck stif photophobia. He has already taken malarial prophylaxis.



- A. CT Scan
- B. MRI
- C. Lumbar puncture
- D. Pheripheral blood picture

127. Time taken by SSRI's to have an effect on depression.

128. A mother whose previous child died asks how to protect the present child from SIDS

- A. Apnoea monitor
- B. Allow child to sleep in supine position


report this post to a moderator (<http://www.rxpgonline.com/report/index.php?p=899370&h=13&u=>)


please rate this post  (<http://www.rxpgonline.com/modules.php?name=usertools&file=pvote&vote=up&u=503349&s=70530&n=13&f=138&t=108126&p=899370>) 

(<http://www.rxpgonline.com/modules.php?name=usertools&file=pvote&vote=down&u=503349&s=70530&n=13&f=138&t=108126&p=899370>)

(<http://www.rxpgonline.com/modules.php?name=usertools&file=pvote&vote=down&u=503349&s=70530&n=13&f=138&t=108126&p=899370>)


 [Reply](http://www.rxpgonline.com/modules.php?name=Forums&file=posting&mode=reply&t=108126) ([modules.php?name=Forums&file=posting&mode=reply&t=108126](http://www.rxpgonline.com/modules.php?name=Forums&file=posting&mode=reply&t=108126))  [quote](http://www.rxpgonline.com/modules.php?name=Forums&file=posting&mode=quote&p=899370) ([modules.php?name=Forums&file=posting&mode=quote&p=899370](http://www.rxpgonline.com/modules.php?name=Forums&file=posting&mode=quote&p=899370))

 [Scrapbook](http://www.rxpgonline.com/modules.php?name=RxPGites&mode=scrapbook&uid=70530) (<http://www.rxpgonline.com/modules.php?name=RxPGites&mode=scrapbook&uid=70530>)

 [PM](http://www.rxpgonline.com/modules.php?name=Private_Messages&file=index&mode=post&u=) ([modules.php?name=Private_Messages&file=index&mode=post&u=](http://www.rxpgonline.com/modules.php?name=Private_Messages&file=index&mode=post&u=))

[Back to top](#)



Syrian (<http://www.rxpgonline.com/threads70530.html>) 

(<http://www.rxpgonline.com/modules.php?name=Messenger&file=buddy&op=compose&to=Syrian>)

Titan



Posts: 124

Credits: 7019 (<http://www.rxpgonline.com/docs/credits>)

Fri May 21, 2010 11:05 pm (4 years ago) **#14** ([modules.php?name=Forums&file=viewpost&](http://www.rxpgonline.com/modules.php?name=Forums&file=viewpost&))

July 2005

Theme : Non Accidental Injury Investigations

Options

- A. CT head
- B. FBC & Coagulation profile
- C. Serial height & weight measurment
- D. No Investigations
- E. MSU cytology & culture
- F. Skeletal survey
- G. Look for blue sclera
- H. Nutritional history

1. A child just started living with her foster mother was found have weight in the 3rd perc
The child appears well and no abnormalities found.

2. A child with bleeding from mouth was found to have torn lingual frenulum.

3. A child brought with complaints of sudden stoppage of breath. Ophthalmoscopy shows m
retinal h'ges.

4. An 18 month baby brought to A/E with bronchiolitis has 6 posterior rib healing fractures.

5. An 8 yr old boy sustained a wrist FRACTURE following a fall in rugby match. He has a histor

6 FRACTURE in previous 3 years. Father is deaf.

6. A child with multiple bruise on her body. Parent fail to explain the cause.

Theme : Pathology : cells of origin

Options

- A. Adipocyte
- B. Ganglion cells
- C. Plasma cells
- D. Megakaryoblast
- E. Skeletal muscle cell
- F. Lymphocytes
- G. Erythroblast
- H. Monocytes
- I. Schwann cells
- J. Neutrophil precursors
- K. Astrocytes
- L. Erythrocyte Precursor
- M. Lymphocyte Precursor
- N. Smooth muscle cell

7. An elderly with bone pain & visual loss. Pathologist gives a diagnosis of multiple myeloma bone marrow biopsy.

8. A young male with recent onset seizures. Brain biopsy done to give a diagnosis of Glioblastoma multiforme.

9. A young female with lymph node enlargement & splenomegaly. Diagnosed to be suffering from Acute myeloid leukemia.

10. A small baby with paravaginal mass. Biopsy was done to come to a diagnosis of rhabdomyosarcoma.

SBA

11. A mentally retarded child puts a green pea in his ear while having his dinner. The doctor confirms this. Otoscopy shows a green colored object in the ear canal. Most appropriate best approach to remove this :

- 1) by a magnet
- 2) syringing
- 3) under GA
- 4) by hook
- 5) by instilling olive oil(?)

12. A trocar inserted midway b/w umbilicus & anterior superior iliac spine, which structure is likely to be pierced :

- a-The rectus abdominis muscle
- b-The linea alba
- c-The External oblique aponeurosis and internal oblique muscle
- d-The External oblique muscle and the internal oblique muscle
- e-the conjoint tendon
-

13. An alcoholic takes 10 units of alcohol per day; on examination he has raised alkaline phosphatase and bilirubin. Most likely cause could be:

- 1. alcoholic hepatitis
- 2. chronic hepatitis
- 3. viral hepatitis
- 4. Primary sclerosing cholangitis

Theme Mechanism of Disease

Options

- A. Infection
- B. Allergy
- C. Genetic
- D. Immune process
- E. Chloride channel defect
- F. Alpha-1 antitrypsin def.

- 14. Asthma
- 15. Cystic fibrosis
- 16. Bronchiolitis

17. A boy develops barking cough associated with inspiratory & expiratory stridor; A diagnosis of laryngotracheobronchitis is reached. What is the single most likely prognosis of the disease if untreated ?

- a) bronchiectasis
- b) complete resolution
- c) lung abscess

18. A boy develops generalized edema with proteinuria ++++1. He is started on steroids. What is the single long term prognosis of the disease?

- a) complete resolution
- b) recurrence with gradual resistance to steroids
- c) recurrence with complete resolution with steroids

Theme : Management of Acute eye Conditions - Topical eye drops
Options

- A. Antibiotic
- B. Mast cell stabilizer
- C. Prednisolone
- D. Mydriatic
- E. Miotic
- F. Prostaglandins
- G. NSAIDs
- H. carbonic anhydrase inhibitor

- 19. Acute bacterial conjunctivitis
- 20. Acute allergic conjunctivitis
- 21. Acute angle closure glaucoma
- 22. Keratitis (non infective)
- 23. corneal abrasion
- 24. Uveitis (?)

25. A diabetic with blood pressure 140/90 with proteinuria 0.2 mg/day. Single most likely agent to offer him benefit :

- a) ACE inhibitors
- b) angiotensin inhibitors
- c) beta blockers
- d) fibrates
- e) statins

26. A 30 yr old lady treated for CIN 2, two years back was a heavy smoker till few months ago. She was on oral contraceptives all these years, but now her partner uses condoms. She is alive as her aunt died of ovarian carcinoma at the age of 48. The most important factor which puts her at the risk of ovarian cancer is :

- a) age
- b) family history
- c) CIN 2
- d) smoking
- e) oral contraceptives

Theme : Overdoses/ poisoning

Options

- A. Paracetamol
- B. Salicylate
- C. sodium hypochlorite (bleach)
- D. paraquat
- E. organophosphorus
- F. Digoxin
- G. Tricyclics
- H. Methanol
- I. Ethanol

- 27. Child with nausea/ vomiting and features of heart block.
- 28. Farmer with excessive sweating, abdominal pain and other cholinergic symptoms.
- 29. A man with sore mouth, pulmonary edema & renal failure.
- 30. A girl with hyperventilation & acidosis.
- 31. A girl with right upper quadrant pain with raised biochemical parameters for liver function.

32. An elderly underwent an operation for rectal carcinoma (?), has not yet opened and complains of abdominal distension & NG tube aspirating large amount of fluids. Most single cause for his condition :

- A. calcium 2.2 mmol/l
- B. potassium 2.4 mmol/litre
- C. sodium 128 mmol/litre

Theme : Side Effects of Antipsychotics

Options

- A. Clozapine
- B. Chlorpromazine
- C. Amitriptyline
- D. Fluoxetine
- E. Lithium

- 33. A chronic schizophrenic on treatment develops sore throat & agranulocytosis.
- 34. A schizophrenic on treatment develops galactorrhea and loss of libido.

35. A schizophrenic on treatment develops stiffness of limbs, raised temperature and creatinine kinase.
 36. A patient with long term bipolar disorder complains of lethargy, weight gain & hypothermia.
 37. A female patient on treatment for depression develops dry SKIN & mouth.

Theme : Side effects of anti epileptics

Options

- A. Carbamazepine
- B. Sodium Valproate
- C. Phenytoin
- D. Ethosuximide
- E. Vigabatrin
- D. Tigabain

38. An epileptic patient with raised levels of urea, creatinine.
 39. A boy on treatment for generalized tonic clonic epilepsy, develops features of hepatic failure in few weeks of starting treatment.
 40. A lady on treatment for epilepsy develops ataxia, gum hypertrophy.

Theme: Seizure Investigations

Options

- A. EEG
- B. ECG
- C. CT head
- D.

41. An adult with recent onset seizure. O/e papilloedema present.
 42. A child with 2 episodes of jerking limb movements. teacher says he does not concentrate in class.
 43. Adult lady with jerking of thumb, followed by limb and then generalized convulsions.

Theme : Diagnosis of Dementia

- A. Depression
- B. Alzheimer's Disease
- C. Frontal Lobe syndrome
- D. Vascular dementia
- E. carbon monoxide poisoning
- F. Huntington's Disease
- G. Pick's disease
- H. Creutzfeldt Jacob Syndrome
- I. Delirium

44. Elderly with history of stroke & falls, now confused and can't remember things.
 45. Elderly with normal memory on examination; wife complains of him becoming aggressively talking about their sexual life publicly.
 46. Elderly lady with no medical complaints, is found entering shop at odd hours of early morning.
 47. An elderly man refuses to talk. says that it's no point talking to him as he is a complete failure and that his memory has given up.
 48. A man admitted in hospital develops features of disorientation & visual hallucinations on day of admission.
 49. A man brought to OPD with features of disorientation & hallucinations. Wife says he was few days before when he caught cold(?).

Theme Incontinence

- A. Fistula
- B. Pelvic floor weakness
- C. Multiple sclerosis
- D. UTI
- E. Detrusor Instability

50. A lady post hysterectomy develops continuous dribbling of urine.
 51. A lady after child birth complains of passing urine on coughing and stressing.
 52. A young girl with history of visual loss & limb weakness complains of not able to pass urine at all.
 53. A lady with frequency & unavoidable desire to urinate at a few seconds' notice but no dysuria;

SBA

54. A lady with unilateral weakness of arm & headache. On examination brisk reflexes & increased tone of the affected arm. Rest of examination appears normal. Single best investigation to do

- a. Skull X ray
- b. CT scan

Theme : Endocrinology

Options

- A. Aldosterone

- B.Cortisole
- C.Erythropoetin
- D.Parathormone
- E.Prolactin

55. A heavy smoker with raised hematocrit & hemoglobin.
 56. Hypokalemic hypertension.
 57. hypotensive, muscle weakness present.
 58. lethargy, bone pain, polyuria, polydyspia
 59. Galactorrhea, amenorrhea, infertility

60. Female with carcinoma breast complains of polyuria ,polydyspia confusion. single best w manage ;

- a. Dexamethasone
- b. palmidronate
- c. Fluid restriction

Theme : Dermatology Colored Slides

61. A lady with breathlessness & perihilar shadow. (slide showed : erythema nodosum)
 62. A man with chest pain & rash on thoracic dermatome. (herpes zoster)
 63. A man with generalized neurofibromatosis & café lau spots
 64. A child with features of meningococcal septicemia.
 65. A lady with history of liver disease. (slide showed : spider nevi)

SBA

66. A man fell from scaffold to lnjure his spine. Investigation revealed damage to S1. Which symptom will correspond to this level of injury :

- a) bladder dysfunction
- b) bowel dysfunction
- c) limb weakness
- d) numbness of sacral area
- e) numbness of sole of foot

Theme: Treatment of pneumonia

Options

- A. Benzylpenicillin
- B. Cotrimoxazole
- C. Ciprofolxacin
- D. Clarithromycin
- E. Fluconazole
- F. Griesofulvin

67. Man wid right lower lobe pneumonia, allergic to pencillin.

68. HIV positive drug abuser wid bilateral expanding shadows on CXR.

Theme : Choice of Anaesthesia

- A. General Anaesthesia
- B. Epidural
- C. IV ketamine
- D. Peribulbar infiltration wid (?)
- E. Bupivacaine linfiltration
- F. Topical Xylocaine

71. COPD wid cough, posted for cataract extraction.
 72. Removal of corneal FB.
 73. A pregnant lady posted for LSCS

Theme Psychiatry Epidemiology

Options

- A. Major Depression
- B. Acute Psychosis
- C. Bipolar Disorder
- D. Dysthymia
- E. Cyclothymia
- F. Recurrent Brief depression
- G. Seasonal Affective disorder
- H. Mixed anxiety n depression

74. More common in females; associated with low mood & depression which lasts for at l weeks.

75. More common in females; characterised by low mood, insomnia, palpitations and sweatir

76. More common in females; characterised by annual recurrence of depressive symptoms.

there wer 2 more questions in this stem, jus cant recollect! may b one was b disorder(?)...jus not sure!

Theme Epidemiology of Joint Diseases

Options

- A. Rheumatoid Arthritis
- B. Osteoarthritis
- C. Osteoporosis
- D. Osteomalacia
- E. Ankylosing Spondylitis
- F. Benign Back Ache
- G. IVDP

77. More common in females; wid incidence of 20% in Caucasian females & associated wid c in body shape. (i hope, am getting the words correct!!)

78. More common in females, affecting 1% of population, associated wid loss of activity years.

79. More common in males, associated wid stiff joints & positive HLA B27.

80. Associated wid heavy work & pulling & pushing & psychosocial factors.

81. With incidence of more than 70% & more than 90% show complete recovery.

SBA

82. A male complains of sudden onset dysphagia after eating bread which gets relieved by vomiting. He had 2 similar episodes in last 3 years while having steaks. His BMI is 32. The most likely investigation which wud lead to the diagnosis of his condition is :

- a) Barium Swallow
- b) Chest X ray
- c) Motility Studies

83. A vagrant man, dishevelled, sweating & fizzy.
(There were more symptoms).

The most likely agent to cause these symptoms cud be:

- a) alcohol
- b) heroine
- c) cocaine

84. An alcoholic is brought to A/E in agitated state, picking at imaginary things. He is started on chlorazepate. The other most important agent to be added to his treatment regimen shd be:

- a) chlormethiazole
- b) thiamine

Theme Management of PPH

- A. IM Syntometrine
- B. Prostaglandins
- C. Syntocin Drip
- D. IV fluids
- E. Blood Transfusion
- F. Laparotomy

85. A female with instrumental delivery, lost 800 ml blood. Uterus well contracted.

86. A multi-para wid previous 2 histories of PPH.

87. A lady on 10th day post LSCS, brought with bleeding lasting for 24 hrs. She has supra-pubic tenderness.

88. A lady bled 600 ml blood after placenta was taken out. (dont remember if any more c were mentioned here).

SBA

89. A female fainted while painting her bathroom wall & hit her head. She was brought to emergency, regained her consciousness & well otherwise a small laceration on her skull. The most important investigation to be done at this stage is :

- a) CT scan
- b) skull X ray
- c) Doppler

90. A 70+ lady shopping in a supermarket fainted suddenly and fractured neck of femur. A daughter who was with her said she went pale before fainting.

A. Dysrhythmia (adam-stokes)

another one with history suggestive of vertebrobasilar insufficiency?

Theme Nephrology Diagnosis

Options

- A. Henoch Schölein Purpura
- B. Hemolytic Uremic Syndrome
- C. Chronic Renal Failure
- D. Acute Glomerulonephritis
- E. Nephrotic Syndrome
- F. SLE

91. Anemia
Thrombocytopenia
Fragmented Red Cells

92. Normochromic Normocytic Anemia
Hypertension
Low erythropoietin (?)

93. Features of
renal failure +
positive ANA.

94. Proteinuria
Hypercholesterolemia
Edema

95. Hematuria
wid raised Urea & Creatinine
Hypertension

Theme Investigations in Nephrology

- A. Ultrasound Abdomen
- B. Catheterize
- C. IVU
- D. Cystoscopy
- E. PSA(?)

96. A boy suffered a blow to his flank during some match. He later complained of one episode of frank hematuria. He is normal otherwise.

97. An elderly wid painless hematuria.

[snip]. An elderly wid symptoms suggestive of BPH (? not really sure abt this one).

99. A man comes wid acute retention of urine following blow to perineum. On examination preineum swollen & bruised.

Theme : Diagnosis of PID

- A. Candidiasis
- B. Gonorrhoea
- C. Chlamydia
- D. Herpes
- E. Cervical ectropion
- F. Trichomonas
- G. Bacterial Vaginosis

100. Lady wid sore vagina & whitish discharge; smear shows mycelia.

101. Lady on OCPs wid mucoid discharge.

102. A young lady wid recently developed dysmenorrhea & deep dyspareunia. Purulent discharge from cervical os. Tested negative for gonorrhea.

103. Lady wid multiple painful, vesicular lesions at the introitus wid scanty offensive discharge.

104. Lady wid discharge per vaginum wid clue cells present.

Theme Blood supply

- A. Cavernous Sinus
- B. Internal carotid Artery
- C. Superficial temporal artery
- D. Middle meningeal artery
- E. Central retinal artery

- F. Facial artery
- G. Middle cerebral Artery
- H. Vertebral artery

- 105. A guy wid abscess near upper lip.
- 106. A diabetic/hypertensive wid sudden visual loss. On examination, fundus appears pale.
- 107. A laceration near the angle of mandible in front of masseter wid profuse bleeding.
- 108. A person wid features of transient loss of vision, dysphasia .
- 109. A person with # petrous temporal, confusion

110. Bipolar disorder (Theme - Epidemiology of Psychiatric Conditions)

111. Malignant Melanoma (Dermatology Colored Slides)

112. Anaesthesia Required during excision of Meibomian Cyst eye (Theme Choice of Anaesthetic)

113. Legionella Pneumonia (?) (Theme Treatment of Pneumonia)

Theme : Next step in management of dyspeptic symptoms

Options

- A. Anti helicobacter therapy
- B. Esophagoduodenoscopy
- C. measure serum gastrin
- D. IV proton pump inhibitors
- E. Oral proton pump inhibitors
- F. Pancreatectomy
- G. Antacids
- H. H2 antagonists

114. A patient wid hematemesis following 40% burns. His vitals stable now & esophagoduodenoscopy shows multiple superficial ulcers in stomach. (Curling's Ulcer; IV PPIs)

115. A female wid hematemesis now stable. On treatment for rheumatoid arthritis.

116. Male wid dyspeptic symptoms. Cytological brushings from stomach positive for gram negative spiral organisms.

117. Male wid severe dyspepsia. not responding to usual anti-dyspeptic measures. Esophagoduodenoscopy shows several ulcers in esophagus, stomach and small intestine.

Theme : Interpretation of Chest findings

- A. Pulmonary embolism
- B. Myocardial Infarction
- C. Simple Pneumothorax
- D. Tension pneumothorax
- E. Pneumonia
- F. hemothorax
- G. Pulmonary Edema
- H. Esophageal rupture

118. Temp 37
JVP raised
CXR normal
ECG T inversion in some (one) lead
BP 100/60; PR 130 bpm

119. Temp 37
JVP normal
CXR normal
BP 120/80 PR 110 bpm
ECG Q waves in V1, 2, 3

120. Temp 39
JVP normal
CXR consolidation of some lobe
BP 120/90 PR 100 bpm/irregular

121. Temp 37
JVP (?)
CXR reduced markings on right side
BP 130/80 PR 90 bpm/regular

122. Temp 37
JVP normal
PR 120 bpm regular
BP 90/60
CXR shows left sided effusion
surgical emphysema present on neck palpation (?)

123. Temp 37

JVP low
PR 90 bpm /regular
BP 100/90
CXR bilateral shadows
Basal creptitions

SBA

124. A man wid sudden onset breathlessness following RTA. His breathlessness not relieved after putting chest drain. Single most likely cause could be :

- a)Tension pneumothorax
- b)bronchial rupture
- c)aortic rupture

125. A neonate wid temp 38.5, is otherwise appearing normal. Single best next step wud be :

- a) reassurance
- b) discharge wid broad spectrum antibiotics
- c) admit for full infection screen
- d) admit for full infection screen & start broad spectrum antibiotics
- e) admit and observe

126. A man wid chronic atrial fibrillation develops features of pulmonary edema. (think i mentioned dat he was on digoxin). Single best next step to wud be:

- a) DC cardioversion
- b) anticoagulation & digoxin
- C)digoxin

Theme Diagnosis of Neck Lumps

Options

- A. Thyroid carcinoma
- B. Goitre
- C. Cystic Hygroma
- D. Branchial cyst
- E. Tuberculous Lymphadenitis
- F. Lymphoma
- G. Ca Stomach
- H. Ca Lung
- I. Mesothelioma

127. A lady from Asia wid lumps in her neck, FNAC of which revealed center of caseous m surrounded by fibrosis.

128. A man wid lump in supra-clavicular region and decreased appetite. He has lost 5 kg v recently.

129. A man with lump in front of his neck which moves up on swallowing. Scan shows a replacing the left lobe of thyroid & spreading to sternomastoid & adjacent muscles.

130. another one on cystic hygroma (?)

131. A shipyard worker develops shortness of breath and a lump in his neck/supraclavicular (?) wid a small pleural effusion on the same side of the lump

SBA

132. A patient wid long history of GORD, underwent esophago-duodenoscopy & Barret's Esop was diagnosed. The single most appropriate term to define this condition wud be :

- a) Squamous metaplasia
- b) Columnar Metaplasia
- c) dysplasia

133. A 30 yr old heavy smoker with previous history of treatment for DVT & varicose develops swelling/ulcer(?) just above her medial malleolus surrounded by lipodermatosclerosis induration on her right foot . She is currently on OCPs. The most likely cause for hei condition is :

- a) varicose veins
- b) DVT
- c) periphehral vascular disease

Theme Management of Electrolyte Imbalances

Options

- A. Insulin only
- B. Insulin wid Normal Saline
- C. Normal saline wid hydrocortisone
- D. Oral Potassium
- E. IV Potassium
- F. dialysis (?)

G. Saline and Potassium Supplementation

134. A 20 yr old girl wid hypotension, hyperkalemic and mildly hyponatremic. She has recent weight and her SKIN appears hyperpigmented.

135. A young boy with polyuria, has very high BLOOD GLUCOSE levels.

136. A patient has diarrhea, appears to be dehydrated wid low potassium levels.

137. A patient of vigorous diuretic therapy develops hypokalemia.

138. A person develops anuria and pulmonary edema after severe crushing injuries and he was around 60

was there one wid severe hyperkalemia (? wid K >7 mmol/L)

Theme : Scientific Basis of Diseases

A. Alpha 1 anti-trypsin deficiency

B. Surfactant deficiency

139. a child with childhood liver failure now comes with emphysema

140. Respiratory distress syndrome of pre-maturity

141. A young girl complains of abdominal pain whenever in school. She is otherwise normal on public holidays. Her epigastric (?) pain is associated wid nausea and no vomiting. She was not to be sent home from school b'cos of this abdominal pain on a number of occasions. The most likely diagnosis could be :

- a) Abdominal Migraine
- b) coeliac disease
- c) Appendicitis
- d) mesenteric adenitis.

142. A patient after a fall on his outstretched hands complains of pain in his wrist. X ray of wrist appears normal. No fractures seen. Most appropriate next step to do :

- a) discharge wid reassurance
- b) scaphoid cast for 6 weeks
- c) take X ray at a later date (?)
- d) plaster and review after 2 weeks

Theme Management of Arrhythmias

Options

- A. Adrenaline
- B. Adenosine
- C. Digoxin
- D. Carbimazole plus beta blockers
- E. Implantable pace maker
- F. external pacemaker

143. A man after falling unconscious on a number of occasions was found to have a heart rate bpm(?).

144. Female sweaty, wid tremors & weight loss. heart rate is 140 bpm/irregular.

145. there was one on SVT(?)

Theme Investigations of Palpitations

Options

- A. ECG
- B. ECHO
- C. 24 hr Holter monitoring
- D. Thyroid Function tests
- E. CXR

146. A young girl, sweaty, tremors and weight loss, says that her heart races.

147. A woman experiences 'thumping' in her chest associated wid breathlessness, while asleep sits up to get symptoms resolve in few minutes time.

148. A woman wid a family history of coronary artery disease. She has noticed palpitations especially during the night. She describes a sensation of her heartbeat momentarily stopping then racing.

149. A man complains of episodes of palpitations which last for few minutes & leave him . His pulse appears to be normal at the point of examination.

SBA

Theme Diagnosis of Coma

150. An elderly traveling alone was brought to A/E from Airport in unconscious state. The needles & a syringe in his hand baggage.

there were more in this theme.

A. Plasma Glucose Levels.

Theme Diagnosis of Accidental Injuries

151. A man after high speed automobile injury, CXR shows widened mediastinum.

A. Aortic rupture.

Theme Diagnosis of Prenatal Conditions

Options

- A. fetal Blood Sampling
- B. Chorionic Villous Sampling
- C. Amniocentesis
- D. USG
- E. check serum anti-d
- F. Fetal echo
- G. Fetal Blood at birth

152. Pregnant lady 16 wks, Scan shows nuchal folds & double bubble sign; Most reliable way to diagnose Down's syndrome?

153. Pregnant lady with previous baby affected with cystic fibrosis, wants to confirm if her present baby is ok.

154. Pregnant lady with previous baby with severe anemia and jaundice.

155. A lady 24 weeks pregnant with a previous child dead from congenital heart disease-

156. A lady wants to know about hypothyroidism

SBA

157. A man with ear ache & on examination his left tonsil is ulcerated with rolled out edges.

- A. Tonsillar tumour
- B. Quinsy
- C. Lymphoma

Theme Pelvic Inflammatory Diseases Investigations

Options

- A. Endocervical Swab
- B. High Vaginal Swab
- C. Contact Tracing
- D. Laparoscopy

158. A lady with pelvic pain & offensive vaginal discharge.

159. An asymptomatic lady says her husband had a purulent urethral discharge and doesn't want to talk about it.

160. An elderly with bleeding per vaginum. USG shows thickened endometrium.

Theme Diagnosis of Abdominal pain

Options

- A. CXR
- B. Abdominal Xray
- C. Barium Enema
- D. Laparotomy
- E. USG

161. A man underwent sigmoidoscopy after which he develops features of peritonitis.

162. A man with features of peritonitis; Erect CXR shows gas under diaphragm.

163. A child with abdominal pain & current jelly stools. sausage shaped mass palpable abdomen.

164. A lady in RTA, with hypotension & rigid abdomen. broken left ribs 10-12.

SBA

165. A pt comes again n agian to g.p and is saying hes got aids wen all his results r negative times

options

- A) ocd
- B) hypochondriasis
- C) others i dont remember

Theme Ovarian Carcinoma Investigations

Options

- A. Pelvic USG
- B. Pelvic CT
- C. CA 125
- D. CA 153
- E. Laparotomy
- F. Laparoscopy
- G. Paracentesis

166. A lady wid family history of ovarian carcinoma. Pelvic USG fails to reveal any abnormali

167. A lady had undergone abdominal hysterectomy wid bilateral salpingo-oophorectomy, omentectomy for Ca ovary, now comes for follow up. Her CA 125 had come to normal levels Surgery.

168. A lady underwent debulking Surgery for ovarian carcinoma now presents wid sig intestinal obstruction.

169. Another lady wid previous history of treated ovarain Ca, now we need to rul recurrence(?).

170. Theme Blood supply (q 105-109) --- A person has injury over temple reigon

Ans. C. Superficial temporal artery

SBA

173: A patient post op has fever after 48 hours with mild abd distension. most likely cause is:

- A. pleural effusion
- B. uti
- C. thrombophlebitis
- D. sepsis

174. A tall guy wid acute onset scrotal pain associated wid vomiting. Single most likely dia wud be:

- a) testicular torsion
- b) torsion of appendicualr appendage
- c) epididymorchitis
- d) UTI

175- a 40 year old lady with a painless non growing swelling in the post superior part of neck.

A. Pleomorphic adenoma

176- DEMENTIA theme.

a 40 year old man brought in with his wife because of his clumsy movements and his fathe had same problems.

A. Huntintons chorea.

177. An elderly living wid granddaughter comes to OP wid bruises on both wrists.

A - Non accidental Injury

Theme : TREATMENT OF PNEUMONIA:

Options

- A. salbutamol inhaler
- B. ipratropium inhaler

- C. flu vaccine
- D. clarithromycin

178. An elderly man with COPD having attacks of pneumonia every winter for the past 2 years wants your advice for this winter.

179. An 18-year-old comes with fever, myalgia-half of her hostel is similarly ill. (something like)

Theme : Childhood Rashes

Options

- A) HSP
- B) Meningococemia

180. Child with colicky abdominal pain with arthritis and purpuric rashes on extensor surfaces. Family history of atopy present.

181. Child taken MMR 2 weeks before, now comes with fever, headache, photophobia rapidly spreading purpuric rash.

was there one suggesting ITP, in this same theme?

Theme Headache Diagnosis

Options

- A. Petrous Temporal FRACTURE
- B. Base of the skull FRACTURE

182. A man in RTA with CSF rhinorrhea ,

183. A man after fall with hemotympanum ,

in this same theme was the question on Unilateral temporal headache (which we also discussed and landed on temporal arteritis as answer).

Theme Gastro Diagnosis

- A. Irritable Bowel disease
- B. Carcinoma Caecum
- C. Carcinoma Rectum
- D. Crohn's Disease
- E. Ulcerative colitis
- F. Solitary rectal ulcer

184. A 37-year-old lady with chronic history of constipation, diarrhea and passing bloody intermittently. Barium enema shows rose thorn ulcers.

185. A man with recent change of bowel habits, weight loss and occult blood in stools positive

186. A young girl with features of alternating diarrhoea & constipation. No weight loss.

187. A man with recent change of bowel habits, tenesmus & bloody stools. Sigmoidoscopy : ulcerative mass in rectum.

188. (continuation of Theme Mechanism of Disease) A boy with mental retardation & learning difficulties. father & uncle had similar problems?

ans. A. Trinucleotide repeats
(hinting at Fragile X syndrome).

190. Male with needle marks, brought in coma with pinpoint pupils.

ans. A: heroine

(continuation of Diagnosis of Coma)

191. one was on with history of repeated falls.

A. subdural hematoma

was there one on extradural too?(apart from the one associated with petrous temporal FRACTURE)

192. then one lady in PID theme, was having bilateral iliac fossae pain with terminal hematuria (blood at the end of micturition).

193. Then another guy in Mechanism of Disease with repeated respiratory tract infections & infertility.

A. ciliary dyskinesia - Young's Syndrome.

194. Another patient in Endocrinology theme had features of Acromegaly.

195. In some chest theme a patient wid with a lymph node wid its calcified circumfe (typical of egg shell calcification).

A. Sarcoidosis

196. In Theme Treatment of Pneumonia

An alcoholic wid hemoptysis; CXR shows right upper lobe consolidation.

ans. A: Anti Tuberculous Therapy

197. (continuation of Overdosages/ poisoning theme,,q27-31).

Male, presents with metabolic acidosis , dilated pupil , elevated serum amylase, hyperglycena

Ans. I. Ethanol

ANSWERS

1. H
2. D
3. A
4. F
5. G
6. B

7. C
8. K
9. J
10.E

11.3

12.C

13.1/4

14.B
15.E
16.A

17.B

18.C

19.A
20.B
21.E
22.C
23.G
24.C

25.A

26.

27.F
28.E
29.D
30.B
31.A
197.I

32.B

33.A
34.B
35.B
36.E
37.C

38.A
39.B
40.C

41.C
42.A
43.

44.D
45.C
46.B
47.A
48.I
49.I

50.A ?
51.B
52.C
53.E

54.B

55.C
56.A
57.B
58.D
59.E

60.B

61-65 - colour slides

66.E

67.C
68.B

69.
70.

71.F
72.F
73.A/B

74.F
75.H
76.G

77.B
78.A
79.E
80. G/B
81.F

82.A

83.A

84.B

85.E
86.C
87.F
88.A

89.A

90.A

91.B
92.C
93.F
94.E
95.D

96.A
97.D
[snip].E
99.B (suprapubic?)

100.A
101.E
102.C
103.D
104.G

105.A
106.E
107.F
108.
109.

110.
111.
112.
113.

114.D
115.E
116.A

117.F

118.A
119.B
120.E
121.C
122.F
123.G

124.B

125.C

126.A

127.E
128.G
129.A
130.C
131.I

132.

133.A

134.C
135.B
136.G
137.D
138.F

139.A
140.B

141.A

142.B/C

143.F
144.D
145.B

146.D
147.B
148.A
149.C

150.A

151.A

152.C
153.B
154.A
155.F
156.G

157.

158.A
159.B
160.A

161.A ?
162.D
163.C
164.E

165.B

166.C
167.B
168.E
169.A

170. C

171.
172.

173.B/D

174.A

175.A

176.A

177.A

178.B

179.C

180.A

181.B

182.B

183.A

184.D

185.B

186.A

187.C

188.A

189.

190.A

191.A

192.A

193.A

194.A

195.A

196.A

197.I

report this post to a moderator (<http://www.rxpgonline.com/report/index.php?p=899374&h=14&u=>)

please rate this post  (<http://www.rxpgonline.com/modules.php?name=usertools&file=pvote&vote=up&u=503349&s=70530&n=14&f=138&t=108126&p=899374>) 

(<http://www.rxpgonline.com/modules.php?name=usertools&file=pvote&vote=down&u=503349&s=70530&n=14&f=138&t=108126&p=899374>)

(<http://www.rxpgonline.com/modules.php?name=Forums&file=posting&mode=reply&t=108126>)

 [Reply](#)

([modules.php?name=Forums&file=posting&mode=reply&t=108126](http://www.rxpgonline.com/modules.php?name=Forums&file=posting&mode=reply&t=108126))

 [quote](#)

([modules.php?name=Forums&file=posting&mode=quote&p=899374](http://www.rxpgonline.com/modules.php?name=Forums&file=posting&mode=quote&p=899374))

 [Scrapbook](#)

(<http://www.rxpgonline.com/modules.php?name=RxPGites&mode=scrapbook&uid=70530>)

 [PM](#)

([modules.php?name=Private_Messages&file=index&mode=post&u=](http://www.rxpgonline.com/modules.php?name=Private_Messages&file=index&mode=post&u=))

[Back to top](#)



Syrian (<http://www.rxpgonline.com/threads70530.html>)

(<http://www.rxpgonline.com/modules.php?name=Messenger&file=buddy&op=compose&to=Syrian>)

name=Messenger&file=buddy&op=compose&to=Syrian)

Titan



Posts: 124

Credits: 7019 (<http://www.rxpgonline.com/docs/credits>)

Fri May 21, 2010 11:10 pm (4 years ago) **#15** ([modules.php?name=Forums&file=viewpost&](http://www.rxpgonline.com/modules.php?name=Forums&file=viewpost&))

September. 2005

1.A35 year old lawyer became increasingly anxious before court appearances.she is now reluctant to speak in public.wants long term solution.

2.45 yrs old woman has become tearful.feels unable to cope.she worries about very thing.di to get sleep.always tired.

3.55 yr old wishes to attend daughters wedding in newzealandin 2 weeks time.she is frighter flying.

4.18 yr old in a state of terrorcame to a&e.he is concinced that he is pursued by people wt out to kill.

5.50yr old man in surgical ward suddenly became anxious and agitatated .he was admitted 3 da with hematemesis which is now settled and there apears no other physical cause to explain.

options:

A.chlorpromazine.

Bcognitive behavioural therapy.

Ccounselling.

d.desensitisation

e.diazepam.

f.hypnotherapy.

g.intersonal therapy.

h.lofepramide

i.phenelezine.

j.propranolol

k.psychoanalysis

l.relaxation therapy.

answers:

- 1.b
- 2.h
- 3.d
- 4.a
- 5.e

theme: causative agent.

1. 8yr old boy has cellulitis of both hands with well demarcated edges, pyrexia & increased wbc

2. 24 yr old with dry cough skin manifestations bone and muscle aches. chest x ray shows p shadows.

3. 60 yr old male has pyrexia and axillary abscess.

4. patient in hosp given with third generation cephalosporins. it resulted in diarrhea.

options:

- a. staphylococci
- b. mycoplasma
- c. strepto cocci
- d. clostridium difficile

answers:

- 1.c
- 2.b
- 3.a
- 4.d

- postural hypotension-
measure lying standing BP
- 2- fluid overload
- 3- tension pneumothorax
- 4- cardiac tamponade
- 5- pin point pupil- give naloxone
- 6- arrhythmia , dilated pupil- amitrytalline
- 7- IV bisphosphonates patient shows sclerotic changes in pelvis
- 8- case of over anticoagulation inr 5.1
- 9- reduce dose of insulin
- 10- cystic fibrosis
- 11- coeliac disease
- 12- patientt with panic attack- rebreath in air bag
- 13- case of alzheimer disease
- 14 - another alzheimer disease
- 15- pseudodementia
- 15- multiinfarct -hypertension

16- lady h/o miscarriages- do antiphospholipid

17- patient with dry eyes- do autoantibodies

18- patientt on bendro develop hot knee- check uric acid

19- case of crf- initial investigation- do u/s abdomen

20- case og acute GN

- 21- side effect- alcohol- dysarthria cerebellum,
- 22- tiredness- beta bloker
- 23- case of haemochromatosis, increase risk of liver cancer

- 24- case of aortic stenosis
- 25- case of mitral stenosis
- 26- median nerve damage- index middle finger
- 27- Ca head of pancreas involve- common bile duct

- 28- diabtict amyotrophy
- 29- breast Ca complications- lymphoedema
- 30- cerebral metastases
- 31- patho fractures

32- hypercalcaemia

- 33- foul smelling discharge from breast- give metronidazole gel
- 34- case of pulmonary embolism- investigation of choice CT
- 35- renal colic 1st line drug - oral paracetamol/ diclofenac suppository
- 36- lady on thyroxine- monitor -TSH
- 37- dx of vaginal discharge -actino, nisseria, chlamidia, trichomona
- 38. managent of incontinence

39. staph ,strp pyogenes- repeat
 40. immobilisation- tibia fibula fracture in a child, crying with pain
 41. distraction- catheterisation in a child 6 yrs
42. terminal pain relief- hyoscine, haloperidol, metronidazole, oral dexamethasone
 43. inv of vaginal bleed
 44. repeat themes about Anatomy of bile duct
45. anemia- pernicious, aplastic, vitb12 deficiency
46. investigations of red eye
 47. shingles management- topical acyclovir, oral aciclovir, 7 days etc
 48. investigations of syncope
 49. heart failure management- aortic valve surgery, iv digoxin, propranolol
 50. antibody to intrinsic factor- pernicious anemia
51. management of tension pneumothorax -needle thoracocentesis
 52. man working in a metal factory/foreign body in eye investigation-xray orbit
 53. s/s of meningitis/inv
 54. man with hypoglycemia blood sugar-2.0 mmole/l -50% dextrose
 55. a 76 month baby with lethargy .constipation inv- tsh
 56. a presents with c/o urge incontinence when she plays tennis
 57. bloody diarrhoea after tt cyclosporine- clostridium
 58. a child presents with vomiting /pyloric stenosis metabolic alkalosis
 59. villous adenoma - metabolic acidosis
 60. inv for cystic fibrosis .sweat test
 61. copd acute exacerbation -24% oxygen
 62. 18 yr old boy presents with 4 hrs h/o red swollen testes
 63. anemia in vegetarians - Vit B 12 deficiency
64. a 3 yo with crust and lesions 10-20 mm peribuccal. with yellowish secretion (diagnosis)
 65. 8 yo fell and complains of severe pain in middle tibia. there is no abnormality at exploration
 66. 14 yo boy unable to swallow, fever, pain in lower end of right jaw, faector oris and swollen gum.
67. 9. 28 yo girls complains of infertility, laparoscopy shows perhepatic adhesions
 68. -perifollicular haemorrhages- vit c def
 69. eczema resistant to antibiotics-? deficiency mg/vit a / ?
 70. sba 57 yr old male tired and pale urine 2 plus protein and 2 plus blood, haemoglobin
 71- vitamin deficiency, b6 b12 iron mg.....
72. mediastinal ttt of supraventricular tachycardia, ventricular tachycardia. atrial fibrillation
73. c125 cancer ovaries
 74- epidemiology of dementia
 75- pain relieving of bronchial ca. ca breast with offensive vaginal discharge...etc
 76- sba - multiple myeloma bence jones protein?
 77- child with bilateral facial swelling- parotitis?
 78- child with gum swelling and pain in right side of lower jaw- dental abscess?
 79- 34 yr businessman has recurrent episodes of palpitation every 2 months- do 24h monitoring?
 80- treatment of svt- dc cardioversion
 81- lady with ra pain not responding to paracetamol- give nsaid oral
 82- a lady afraid to fly has to go to her daughter's wedding in nz. treatment
 83- a man on warfarin complains of painless haematuria, inr 2.1(dx)
 84- a woman on warfarin has painless haematuria inr 5.1
 85- a man thinks there is a metal foreign body in his eye (investigation)
 86- a man complains of eye pain while gardening
- 87- a woman complains of blurred vision, eye pain and vomiting. she has history of migraine
 88- 3. terminal care (treatment) -lady with malodorous breast ca
 89- terminal care (treatment)- man dying of bronchial ca has cough
 90- complications of breast ca (diagnosis) - lady with a swollen arm
- 91- complications of breast ca (diagnosis)- lady with headache and papilloedema
 92- complications of breast ca (diagnosis)- lady unable to pass urine, back pain and weakness in

AETIOLOGIC AGENT:

AXILLARY ABSCESS- S. AUREUS

TENDER WARM LEG- S. PYOGENES (NOT REALLY SURE)

WHITE CURDY VAGINAL DISCHARGE- CANDIDA

X-RAY FINDINGS:

POSTERIOR MI- IS IT NORMAL? WIDENED MEDIASTINUM?

STABBED CHEST (A CASE OF PERICARDIAL EFFUSION)- GLOBULAR HEART

BP DIFFERENT ARM- WIDENED MEDIASTINUM

DIVERTICULITIS- FREE GAS BENEATH DIAPHRAGM OR MEDIASTINAL GAS??

VAGINAL DISCHARGE

-PTN HAS A GREEN VAGINAL DISCHARGE, HER PARTNER HAS A PURULENT DISCHARGE

-CANDIDIASIS, PREGNANT, WHITE DISCHARGE, SORE VAGINA

-MULTIPLE VAGINAL ULCERS
-WHICH ORGANISM AFTER IUD INSERTION

6-A GARDENER WITH PHOTOPHOBIA AND PELPHROSSPAM
PTN TREATED FOR A LONG TIME RHEUMATIC ARTERITIS, RED PAINFUL EYE
A METAL WORKER COMPLAINS OF SUDDEN PAINFUL EYE

SBA- 20 YR GIRL, FOUGHT WITH BF, TOOK PARACETAMOL NOT EXCEEDING LIMITS, CONSCIOUS, ASKED THAT IT WAS INCORRECT, WHAT IS UR NEXT MANAGEMNT

1. DISCHARGE HOME
2. REFERRAL 2 PSYCHTRY OPD
3. COGNITIVE BEHAVIORAL THERPY
4. ADMISION IN Psychiatry (I DONT REMEMBER EXACTLY) WARD

9.5, SERUM CREATININE 350, WHICH URGENT INVESTIGATION U DO

-MSU
-URINE FOR BENCE JONES
-U/S ABDOMEN
I PUT U/S ABDOMEN TO SEE WEATHER THIS IS ACUTE OR CHRONIC RENAL FAILURE?
SOME PUT URINE BENCE JONES, VERY TRICKY QS

10. MAIN CAUSE OF DEMENTIA
INVESTIGATION FOR CURABLE DEMENTIA
IT RESPONDS TO TRYCYCLICS.
A DEMENTIA WITH PERSONALITY CHANGES AND MINIMAL INTELECTUAL DETERIORATION
A DEMENTIA WITH NEUROFIBRILARY TANGLES IN CORTEX
Management of herpes zoster

oral acyclovir
acyclovir and urgent referral to specialist
reassurance
immunoglobulins

- 1 a 30 wks pregnant patient with thoracic eruption
- 2 an immunosuppressed child exposed to chicken pox
- 3 a pt with healed lesions and only discoloration
- 4 a pt with thoracic eruption came within 24 hrs
- 5 a pt with ophthalmic shingles

there was a new theme on hernia treatment
inpatient mesh hernia repair
herniotomy
orchidopexy
(i can't remember the other options)

1. child with inguinal hernia not having any difficulty
 2. a healthy man having inguinoscrotal hernia
 3. a man with repeated hernia
- i think there were 2 more ques in this theme

Diagnosis of ulcer
arterial
venous
basal cell ca
traumatic
squamous cell ca
decubitus

1. a man with ulcer on medial malleolus
 2. a man with motor neuron disease since 5 yrs now ulcer on lateral malleolus
 - 3 a smoker with leg ulcer
 - 4 another man with leg ulcer with raised edges
 - 5 ulcer which occurs after trauma but not healing
- Quote:

A MAN TREATING HIMSELF FOR DYSPEPTIC SYMPTOMS. NO H/O WT LOSS. ON ENDOSCOPY NARROWING OF LOWER END OF OESOPHAGUS N INFLAMMATION. HE IS ALCOHOLIC N SMOKER IS 34.

- A. BARRETS OESOPHAGUS
 - B. OESOPHAGEAL STRICTURE (I THINK THIS IS CORRECT?? DUE TO ALCOHOLISM??)
 - C. CA OESOPHAGUS
 - D. HIATUS HERNIA. ROLLING TYPE
- Quote:

A BOY WITH VESICLES AROUND MOUTH WHICH HAVE BURSTED N DISCHARGE COMING OUT

THEM. A. [bleep] IMPETIGO - ans? B. SHINGLES C. CHICKEN POX

Quote:

SHINGLES OPTIONS AV ACYCLOVIR ORAL ACYCLOVIR FOR 2 DAYS ORAL ACYCLOVIR FOR 7
IMMUNOGLOBULIN STEROIDS(HIGH DOSE) REASSURE N ADVISE
1.30 WKS PREGNANT WOMEN WITH SHINGLES..ORAL ACYCLOVIR FOR 7 DAYS

2.AN ELDERLY MAN IN INSTITUTION. STEROIDS

3. A CHILD WITH LEUKEMIA HAS SHINGLES. IMMUNOGLOBULINS

4. A MAN WITH SHINGLES ON CHEST N TRUNK - ORAL ACYCLOVIR FOR 7 DAYS

5. A MAN WHOSE SHINGLES HAS RESOLVED ONLY SCRATCH MARKS LEFT - REASSURE N ADVISE.

Post Options: Reply

Quote:

A CHILD OF 6 DRINKS A LOT OF MILK EVERY DAY BUT EATS NOTHING ELSE , HE IS LETHARGIC
B6 VITB12 VIT D CA IRON AND SO ON THE QUESTION OF RESISTANT ECZEMA WAS FROM THE
THEME BUT THERE WAS NOT AN OPTION OF VITA

Quote:

NASAL BLEEDING-30YR OLD LADY WITH H/O NASAL SEPTAL BLEEDING 2-3 TIMES IN TWO DAYS
RASH. LADY WITH NASAL BLEEDING,HER FATHER HAD H/O REPEATED BLOOD TRANSFUSION.

Quote:

54 YR OLD MAN WITH PROGRESSIVE DYSPHAGIA SMOKES 15-20 CIG. /DAY ON EXAM LAR C
PALS Y SINGLE MOST INVESTIGATION OF CHIOCE A.BARIUM SWALLOW B.CT SCAN C.MRI

Quote:

A LADY AFRAID TO FLY HAS TO GO TO HER DAUGHTER'S WEDDING IN NZ AFT
WEEKS.TREATMENT: DESENSITIZATION - AS ITS PHOBIA A LAWYER CANT SPEAK INFRONT OF
COGNITIVE BEHAVIOURAL THERAPY A GIRL COLLAPSED IN ASSEMBLY ALSO COLLAPSES IN DEN
CLINIC. A MAN COLLAPSED AFTER DONATING BLOOD. VASOVAGAL SYNCOPE

Quote:

MAN USING CRUTCHES, LOSS OF SENSATION OVER DORSUM OF MIDDLE N INDEX FINGER.V
NERVE INJURES. 1. MEDIAN 2. RADIAL??

Quote:

A BOY HAD ACCIDENT CAME TO A & E WITH FRACTURED TIBIA N FIBULA N CRYING WITH PAIN
PARACETAMOL or IMMOBILIZATION

ACID BASE

PYLORIC STENOSIS--MET ALKALOSIS

VILLOUS ADENOMA--HYPOKALEMIA

WOMEN BREATHLESS AFTER HYSTERECTOMY--FLUID OVERLOAD

A WOMEN PRESENTS WITH C/O URGE INCONTINENCE ONLY WHEN SHE PLAYS TENNIS
? DETRUSOR ?ANXIETY

Quote:

EAR INFECTION.. A. A BOY WITH FEVER N EARACHE BUT TYMPANIC MEMBRANE WAS NO
OTITIS MEDIA B. A BOY WITH EARACHE N DISCHARGE. OTITIS EXTERNA

Quote:

A WOMEN 48 YRS WITH IRREGULAR VAGINAL BLEEDING, HOT FLUSHES..ETC. CYCLICAL HORMONAL

Quote:

A WOMEN POST MENOPAUSAL WITH HOT FLUSHES..CONTINUOUS HORMONAL THERAPY.

Quote:

WHAT CAUSES LIVER CANCER IN 3-4 YEARS- -ALCOHOL DRINKING

NASAL BLEEDING- 30YR OLD LADY WITH H/O NASAL SEPTAL BLEEDING 2-3 TIMES IN TWO DAYS
RASH. MOTHER ALSO HAD THIS PROBLEM--VON WILLIBRAND LADY WITH NASAL BLEEDING
FATHER HAD H/O REPEATED BLOOD TRANSFUSION, BLEEDING DISORDER.

Quote:

DISEASE INHERITANCE HAEMOPHILIA...X LINKED RECESSIVE

Quote:

TREATMENT OF SVT-AMIDARONE

Quote:
POISONING : DIGOXIN , AMYTRYPTALINE ETC

Quote:
A DIABETIC WITH HAEMOCHROMATOSIS HAS RISK OF CANCER OF WHICH ORGAN-PANCREAS



Quote:
A PT WITH HEART FAILURE.MEDICAL TREATMENT FAILED -HEART TRANSPLANT

Quote:
VAGINAL DISCHARGE-GREEN COLOURED-TRICHOMONAS, IUCD RELATED , ACTINOMUCES ISRAELI





Quote:
SBA: 57 YR OLD MALE TIERD AND PALE URINE 2 PLUS PROTEIN AND 2 PLUS BLOOD, HAEMOG 9.5, SERUM CREATININE 350, WHICH URGENT INVESTIGATION U DO -MSU -URINE FOR BENCE -U/S ABDOMEN 24 HR URINARY PROTEINS




Young woman presents in hospital after taking some tabs of paracetamol on breaking up with boyfriend. Tests indicate n-acetylcysteine is not necessary. next step?

- a: cognitive behavioral therapy
- b: admission to psychiatric ward
- c: discharge and follow up
- d: place on psychiatric drugs
- d: place on antipsychotic medication

report this post to a moderator (<http://www.rxpgonline.com/report/index.php?p=899378&h=15&u=>)
please rate this post  (<http://www.rxpgonline.com/modules.php?name=usertools&file=pvote&vote=up&u=503349&s=70530&n=15&f=138&t=108126&p=899378>) 
(<http://www.rxpgonline.com/modules.php?name=usertools&file=pvote&vote=down&u=503349&s=70530&n=15&f=138&t=108126&p=899378>)

Back to top

 [Reply](http://www.rxpgonline.com/modules.php?name=Forums&file=posting&mode=reply&t=108126) ([modules.php?name=Forums&file=posting&mode=reply&t=108126](http://www.rxpgonline.com/modules.php?name=Forums&file=posting&mode=reply&t=108126))  [quote](http://www.rxpgonline.com/modules.php?name=Forums&file=posting&mode=quote&p=899378) ([modules.php?name=Forums&file=posting&mode=quote&p=899378](http://www.rxpgonline.com/modules.php?name=Forums&file=posting&mode=quote&p=899378))  [Scrapbook](http://www.rxpgonline.com/modules.php?name=RxPGites&mode=scrapbook&uid=70530) (<http://www.rxpgonline.com/modules.php?name=RxPGites&mode=scrapbook&uid=70530>)  [PM](http://www.rxpgonline.com/modules.php?name=Private_Messages&file=index&mode=post&u=) ([modules.php?name=Private_Messages&file=index&mode=post&u=](http://www.rxpgonline.com/modules.php?name=Private_Messages&file=index&mode=post&u=))

 **Syrian** (<http://www.rxpgonline.com/threads70530.html>) 
(<http://www.rxpgonline.com/modules.php?name=Messenger&file=buddy&op=compose&to=Syrian>)
Titan

Posts: 124
Credits: 7019 (<http://www.rxpgonline.com/docs/credits>)

Fri May 21, 2010 11:13 pm (4 years ago) #16 ([modules.php?name=Forums&file=viewpost&](http://www.rxpgonline.com/modules.php?name=Forums&file=viewpost&))



March 2005

Themes of March 2005 EMQ and SBA PLAB 1 Paper





Hey guys. How did everyone do the paper? It was ok I guess. I just pray and hope we all will through These are the themes i can recollect for now




1. Side effects of medication in pain relief
2. Clinical features of poisoning
3. History of weight loss (somewhat familiar)
4. Another one in Ophthalmology about concave convex lens cataracts etc
5. Epidemiological data in dementia
6. Diagnosis of anaemia
7. Electrolyte abnormalities
8. Limb ischemia
9. Fever and rash
10. Diagnosis of shock
11. Vertigo
12. Cervical Pathology
13. Chest X ray in shock this was also been reposted from November or January not sure
14. Another drug side effects some with lithium tricyclics etc
15. Preoperative test for hernia
16. Wrist injuries
17. Diagnosis in dizziness
- 18... another about syncope in children i guess?
19. Vaginal discharge treatments
19. Acute dyspnoea
20. Another themes with croup epiglottitis etc
- 21 aetiology of infection repeated from November 2004
22. Retention treatment (mixed questions from past paper)
23. One more horrible statistics one bone pain
24. One SBA about faecal impaction. Options were oral laxative...phosphate enema. High diet and questions was immediate management
25. Another SBA was administration of adrenaline 1.1000 i.m.
26. One more SBA about epiglottitis i hope i
27. Hey one more on diff diagnosis of acute abdomen in women or something the typical one
- 27 emq in pyschiatry about major depression... etc
28. SBA in pyschiatry i answered propranol if anybody can recollect
29. Ante partum haemorrhage
30. Was on terminal care...biphosphonates, haloperidol, hyoscine etc?


31. Investigation in anaemia

report this post to a moderator (<http://www.rxpgonline.com/report/index.php?p=899380&h=16&u=>)
 please rate this post  (<http://www.rxpgonline.com/modules.php?name=usertools&file=pvote&vote=up&u=503349&s=70530&n=16&f=138&t=108126&p=899380>)  (<http://www.rxpgonline.com/modules.php?name=usertools&file=pvote&vote=down&u=503349&s=70530&n=16&f=138&t=108126&p=899380>)

Back to top

 [Reply](#) (<modules.php?name=Forums&file=posting&mode=reply&t=108126>)  [quote](#) (<modules.php?name=Forums&file=posting&mode=quote&p=899380>)  [Scrapbook](#) (<http://www.rxpgonline.com/modules.php?name=RxPGites&mode=scrapbook&uid=70530>)  [PM](#) (modules.php?name=Private_Messages&file=index&mode=post&u=

 **Syrian** (<http://www.rxpgonline.com/threads70530.html>) 
 (<http://www.rxpgonline.com/modules.php?name=Messenger&file=buddy&op=compose&to=Syrian>)
 Titan

 Posts: 124
 Credits: 7019 (<http://www.rxpgonline.com/docs/credits>)

 Fri May 21, 2010 11:17 pm (4 years ago) **#17** (<modules.php?name=Forums&file=viewpost&>

March 2004

1 Theme: Scientific basis of CNS disease

Options

- A. Berry aneurysm
- B. Multiple sclerosis
- C. Alzheimer's dementia
- D. Toxoplasmosis
- E. Meningioma
- F. Glioblastoma multiforme
- G. Cerebral infarct
- H. Cerebral hemorrhage
- I. Secondary carcinoma
- J. Astrocytoma
- K. Meduloblastoma

1. It is characterized by large areas of demyelination throughout the brain"
2. A circumscribed and limited lesion with glandular columnar cells with pleomorphic nuclei
3. A wedge shaped area of discoloration involving both gray and white matter
- 4 A mass present on the outer aspect of the brain with pressure over the brain. Psammoma t are present
5. Present at the junction of internal carotid artery and middle cerebral artery (or Mid cereb & Ant cerebral art)

2 Theme: Scientific basis of Heart disease

Options

- A. Nutritional
- B. Congenital
- C. Autoimmune
- D. Infective
- E. Hormonal
- F. Degenerative
- G. Neoplastic
- H.

6. A 55-year-old lady has palpitation, weight loss despite increased diet.
7. A 24-year-old female presents with pyrexia, finger clubbing and splinter hemorrhages:
8. A 34-year-old patient underwent valvular replacement surgery, afterwards she presents fever, a newly developed murmur and altered intensity of heart sounds.
9. A 34-year-old man has symptoms of syncope, he has a bicuspid aortic valve
10. An alcoholic 60-year-old man who is on his own, with no one to look after him, has JVP, pedal edema and spider neavei. On C-XR he is found to have massive cardiomegaly (gl heart)

3. Theme: Diagnosis of Eye Conditions

Options

- A. Corneal Abrasion
- B. Dendritic Ulcer
- C. Foreign Body
- D. Viral Conjunctivitis
- E. Limbal Dermoid
- F. Pterygium
- G. Interstitial Keratitis
- H. Band Keratopathy
- I. Herpes zoster
- J. Keratoconus.
- K. Interstitial keratitis.

L. Degenerative changes.

- 11. Metal sheet worker complains of pain photophobia and lacrimation
- 12. A welsh farmer has fleshy bilateral swellings on the white of the eye
- 13. A patient presents with pain in the eye and decreased vision along with photophobi lacrimation. He has painful vesicular eruptions around the mouth
- 14. A female patient wakes up from sleep to find blurring of vision along with pain and lacrim in the eye. 12 months back she was treated for a scratch in the eye by her daughter's nail playing
- 15. A patient has a history of sore throat along with flu like symptoms. He now has a red eye

4. Theme: Management of Ear complaints

Options

- A. Admit & IV antibiotics.
- B. Oral Amoxicillin
- C. Oral Amoxicillin + Metronidazole.
- D. Syringing.
- E. Pack the ear.
- F. Surgical intervention
- G. Out patient review.

- 16. Girl with fever, earache not able to swallow
- 17. A 24-year-old man newly joins swimming classes and presents with earache and dimir hearing. On exam he is found to be normal except for some wax in the ear
- 18. A 24-year-old Rugby player has ear discharge and loss of hearing in right ear, on exam th small ragged perforation in the tympanic membrane
- 19. A 34-year-old woman presents with high fever, vomiting, headache and rigors. Sh already been having earache along with ear discharge, tenderness over mastoid antrum
- 20. A 33-year-old female undergoes root canal treatment at a dentist. 5 days afterwards st tenderness over the maxillary sinus associated with earache.
- 21. A 32-year-old boxer has bleeding in the ear after an injury sustained in a boxing match.

5. Theme: Management of cardiac Arrhythmias

Options

- A. Heparin
- B. Warfarin
- C. Atenolol
- D. Streptokinase,
- E. Alteplase
- F. Heparin + Cardioversion
- G. Adenosine
- H. Isosorbide mononitrate
- I. Glyceryl trinitrate
- J. r-TPA
- K. Low dose Aspirin
- L. NTG Patch

- 22. A 40-year-old male presents with chest pain for 2 hours, now after 1 hour he has no pain. But the ECG shows T wave inversion in L II, III, aVF
- 23. Patient with previous history of MI treated with thrombolysis now presents with ST se; elevation
- 24. Post MI patient, with narrow complex tachycardia.
- 25. A patient presents with an irregular pulse, HR. 160 /min., BP. 100/70 mm Hg | Fibrillation]
- 26. A patient has his apical impulse shifted to the Left and has difficulty in breathing and L V

6. Theme: Diagnosis of post MI complications

Options

- A. Papillary muscle rupture
- B. Atrial Fibrillation
- C. Ventricular Fibrillation
- D. Complete Heart block
- E. Pulmonary Embolism
- F. Acute pericarditis
- G. Congestive cardiac failure
- H.

- 27. Five days after myocardial infarction a patient presents with collapse. O/E pansystolic m
- 28. Pt presents 12-hours after MI with recurrent chest pain, breathlessness & heart rate of 40
- 29. Post MI with irregularly irregular pulse

7. Theme: Diagnosis of chest infection

Options

- A. M. Tuberculosis
- B. Pseudomonas.
- C. Strep pneumoniae.
- D. Mycoplasma pneumoniae.
- E. Legionella.
- F. Chlamydia.
- G. Pneumocystis carinii.

30. A 30-year-old patient loses weight within the last 4-months, presents with dry cough bilateral interstitial marking on C-X ray
31. A 20-year-old previously very healthy has general malaise, dry cough and breathlessness: significant changes on examination. Chest X-ray shows patchy consolidation throughout the fields.
32. Patient with history of travel, presented with diarrhea vomiting and chest infection.
33. A 50 kg weight loses 5 kgs weight and has night sweats, fever and hemoptysis & cough ray shows upper sided lesion
34. Cystic fibrosis severe cough

8. Theme: Infections Causative agent

Options

- A. Strep pneumoniae
- B. Strep pyogenes
- C. Staph aureus
- D. Chlamydia
- E. E. Coli
- F. Gonococcus
- G. Clostridium difficile
- H. Campylobacter
- I.

35. A 14-year-old boy presents with a circumscribed swelling on his arm. It is erythematous the margins are very limited. Pyrexia is present.
112. A 25-year-old presents with an axillary abscess
36. 25-year-old male patient having pus from axilla
37. Old hospitalized lady on cefuroxime now developed bloody diarrhea
38. A patient has very severe lower abdominal pain along with pyrexia after changing her partner.
- 39.

9. Theme: Management of asthma

Options

- A. Nebulized Beta2 agonist
- B. Long acting inhaled B2 agonist
- C. Inhaled Steroid
- D. Reduce inhaled steroid dose
- E. Inhaled cromoglycate
- F. Oral Steroids
- G. Reassurance
- H. Inhaled short acting B2 agonist
- I. Iv steroids
- J. Leukotrienes antagonist
- K. Antibiotics
- L. Oral Theophylline

41. A 7-year-old child has intermittent asthma, he has been using inhaled B agonists and steroids. He is allergic to aspirin and is still having symptoms
42. Patient well maintained on 1000ugm inhaled steroid but develops thrush
43. A 25-year-old man is taking inhaled B agonist 3 times in a day. Still he wakes up at night wheezing.
44. A 36-year-old woman is a known asthmatic. She is on treatment with oral steroids presents to the A&E breathless and wheezing
45. A 45-year-old man suffering from chronic asthma is unwell, he has pyrexia and green sputum His PEFr is <80% of his normal value.

10. Theme: Diagnosis of Upper GI Diseases (Dysphagia)

Options

- A. Barrett's esophagus

- B. Achalasia cardia
- C. Plummer Vinson syndrome
- D. Scleroderma
- E. Hiatus Hernia
- F. Peptic ulcer
- G. Parkinsonism
- H. GORD
- I.

- 46. Transformation of squamous epithelium to columnar epithelium
- 47. A 50-year-old female presents with pallor and fatigue, blood smear shows microcyti hypochromasia. She has post cricoid webs and has difficulty in swallowing.
- 48. A boy with dysphagia, an organ protrusion into the thoracic cavity
- 49. A layer of submucosal hyaloid fibrosis
- 50- s/s achalasia

11. Theme: Appropriate investigation in constipation

Options

- A. Rectal biopsy
- B. Reassure
- C. Barium meal + follow through
- D. NM studies of gut
- E. Sigmoidoscopy
- F. CT scan
- G. USG abdomen
- H. UGI endoscopy
- I.

- 51. An 8-year-old girl with weekly abdominal pain, no h/o diarrhea or vomiting. Ph examination was unremarkable.
- 52. A 6-year-old child had been having repeated constipation which is not being relieved by treatment with laxatives. O/E there is no ano-rectal anomalies
- 53. A 8-year-old child presents with epigastric pain a/w food. It appears before eating ; relieved by eating food
- 54. A patient presents with a painless bladder, which is distended up to the umbilicus. The patient has been suffering from constipation since the last 3 months and his sigmoid colon is palpable in the abdomen

12. Theme: Rectal bleeding

Options

- A. Hemorrhoids
- B. Diverticulitis
- C. Diverticulosis
- D. CA rectum
- E. CA colon
- F. U C
- G. Campylobacter jejuni.
- H. Pseudomembranous colitis.

- 55. A 45-year-old male with loose stools, blood, and progressive feeling of incomplete defecation
- 56. A 54-year-old man presents with altered bowel habits and bleeding PR.
- 57. History of chronic constipation, hard stool passage now presenting with bleeding PR. Stool coated with blood and splash in pan
- 58. A 28-year-old woman returns from Thailand, she had an episode of bloody diarrhea ; then she was all right. She came back and has similar episode
- 59. Young boy with bloody diarrhea and vomiting for one day.

13. Theme: Investigation of complications CA prostate

Options

- A. PSA
- B. Serum acid phosphatase
- C. Serum alkaline phosphatase
- D. Transrectal USG guided biopsy
- E. Serum Calcium level
- F. Isotope bone scans
- G. Full skeletal survey
- H. X ray pelvis and lumbar spine

- 60. A patient with CA. Prostate presents with urinary incontinence along with weakness of legs and backache
- 61. Known case of CA Prostate presents with humerus fracture. On x-ray we find osteosclerotic lesions
- 62. Male with high PSA levels and on rectal exam has loss of median sulcus + on USG nodularity in prostate next step
- 63. A 56-year-old has a family h/o of prostatic CA. He presents for examination and wants to

if he has prostatic CA. He is found to have a normal per-rectal exam and no lymphadenopathy
 64. Man on GnRH's for prostate cancer comes after 2 months for follow up

14. Theme: Cause of urinary retention

Options

- A. BPH
- B. Prostate Ca
- C. Fecal impaction
- D. Clot retention
- E. Ureteral stricture
- F. Bladder stone
- G.
- H.

65. An old patient with the history of constipation with palpable sigmoid colon & bladder palpable till umbilicus

66. A patient with Bladder Ca. wants to undergo surgery. A day before the admission to hospital he presents with inability to pass urine.

67. A patient is unable to pass urine after drinking 5 pints of beer. Earlier he had difficulty with micturition, dribbling and nocturia.

68. 75-year-old male with bladder outflow obstruction with other BPH symptoms

69.

15. Theme: Investigations of Postop complications

Options

- A. Blood Culture
- B. Ultrasound abdomen
- C. Wound swab
- D. Doppler study
- E. CT scan
- F. Venogram
- G. Serum Creatinine level
- H. Chest X-ray
- I. Blood Glucose
- J. ECG
- K. Full blood count
- L. VQ scan

70. A 64-year-old woman underwent an emergency laparotomy for peritonitis. On the 6th day after surgery she is noted to have a serosanguinous discharge from the wound. There is no surrounding erythema & she has normal temperature

71. A 50-year-old woman underwent surgery for Ca. Rectum, 10 days back. She has low-grade fever of 37.5 deg. C and is complaining of pain in the left calf. She has oedema of the left lower ankle.

72. A 24-year-old man underwent appendicectomy 7 days back. He was making good recovery but suddenly developed high fever. On exam there is no abnormality except for slight lower abdominal tenderness.

73. A 55-year-old man underwent emergency repair for an abdominal aortic aneurysm rupture. Before the surgery his BP was 60/40 mm Hg. During the surgery and after, his blood pressure was satisfactory, but his urine output was < 5-ml in the first hour after surgery.

74. A 75-year-old woman underwent left hemicolectomy for Ca. Sigmoid Colon. On the 4th day after surgery she becomes sick. On exam she is having fever 38.6°C, BP. 60/40, PR. 130/min and hands and feet are warm.

16. Theme: Pre-op investigation

Options

- A. ECG
- B. 24-hr ECG
- C. EEG
- D. Echocardiography
- E.
- F.

75. A 10-year-old child is posted for Herniorrhaphy. He is clinically normal, but has an irregular pulse.

76. A person wants to undergo surgery. He is evaluated and found to be completely normal. ECG however shows RBBB. Next step.

77.

17. Theme: Diagnosis of Fractures

Options

- A. Transverse Fracture ulna
- B. Fracture clavicle
- C. Spiral Fracture humerus
- D. Fracture neck of humerus
- E. Scaphoid Fracture
- F. Bennett's Fracture
- G. Supracondylar Fracture humerus
- H. Fracture Metacarpals
- I. No evidence of fracture
- J.

78. A 43-year-old lady oversteps the footpath while carrying her shopping bags and falls presents with pain in arm and no deformity but movements are slightly restricted.

79. A 16-year-old girl falls on the outstretched hand and complains of pain from shoulder to elbow, she is unable to use her arm.

80. A man hit by baseball bat while protecting himself using his hand in a fight.

81. A patient has a fall on a outstretched hand. He is unable to lift his wrist placed on the table.

82. A Rugby player injures his hand during the game. He has pain swelling and tenderness in region distal to the lower end of radius. On the X-ray there is no evidence of fracture.

83. Guy presents with pain after punching his fist on the wall

18. Theme: Management of traumatic injuries

Options:

- A. Shoulder-Wrist Sling
- B. Collar & Cuff Sling
- C. Simple Sling
- D. Reassure
- E. Immobilization in cast
- F. Resuscitation
- G. Resuscitation and External Fixation
- H. Manipulation
- I. POP Cast

85. A patient undergoes a RTA and has fracture pelvis.

86. A 3-year-old boy his father pulls his hand while swinging him in the garden. He has displacement at the elbow region.

87. A child is knocked down and run over by a bus over his legs, he is tachycardic and hypotension. Next step.

88. After injury, pain distal to radius, initial investigations seem normal.

89. Clavicle or some joint dislocation

19. Theme: Trauma investigation

Options:

- A. Abdominal CT
- B. Thoracic CT
- C. Pelvic CT
- D. Chest x-ray
- E. Neck x-ray
- F. Abdominal X-ray
- G. IVU
- H. Urethrogram
- I. Skeletal Survey
- J.

90. A 10-year-old boy is knocked down by a car while cycling, brought to A&E. He is vomit and upper abdominal pain and tenderness.


91. A child from RTA pain in upper abdomen with pain in left shoulder tip.

92. A patient had an episode of epilepsy following which he has difficulty in breathing and swallow his saliva. O/E his dentures are missing

93. A 32-year-old man has a kick in loin region, developed hematuria, no blood at urethral meatus no perineal injury seen.

94. A patient was wearing a soft neck collar and is involved in a RTA and she had been sitting in the rear seat. After 10 days she presents with

report this post to a moderator (<http://www.rxpgonline.com/report/index.php?p=899386&h=17&u=>)

12 credits  (<http://www.rxpgonline.com/modules.php?name=usertools&file=pvote&vote=up&u=503349&s=70530&n=17&f=138&t=108126&p=899386>)

(<http://www.rxpgonline.com/modules.php?name=usertools&file=pvote&vote=down&u=503349&s=70530&n=17&f=138&t=108126&p=899386>)

([modules.php?name=Forums&file=posting&mode=reply&t=108126](http://www.rxpgonline.com/modules.php?name=Forums&file=posting&mode=reply&t=108126))



([modules.php?name=Forums&file=posting&mode=reply&t=108126](http://www.rxpgonline.com/modules.php?name=Forums&file=posting&mode=reply&t=108126))



([modules.php?name=Forums&file=posting&mode=quote&p=899386](http://www.rxpgonline.com/modules.php?name=Forums&file=posting&mode=quote&p=899386))



(<http://www.rxpgonline.com/modules.php?name=RxPGites&mode=scrapbook&uid=70530>)



([modules.php?name=Private_Messages&file=index&mode=post&u=](http://www.rxpgonline.com/modules.php?name=Private_Messages&file=index&mode=post&u=))

Back to top



Fri May 21, 2010 11:25 pm (4 years ago) #18 ([modules.php?name=Forums&file=viewpost&id=108126](http://www.rxpgonline.com/modules.php?name=Forums&file=viewpost&id=108126))



Syrian (<http://www.rxpgonline.com/threads70530.html>)

(<http://www.rxpgonline.com/modules.php?name=Messenger&file=buddy&op=compose&to=Syrian>)

Titan



Posts: 124

Credits: 7019 (<http://www.rxpgonline.com/docs/credits>)

Back to top

..... DONE

If anyone has the right answers or other questions , please don't hesitate to post.....

report this post to a moderator (<http://www.rxpgonline.com/report/index.php?p=899394&h=18&u=>)

please rate this post (<http://www.rxpgonline.com/modules.php?name=usertools&file=pvote&vote=up&u=503349&s=70530&n=18&f=138&t=108126&p=899394>)

(<http://www.rxpgonline.com/modules.php?name=usertools&file=pvote&vote=down&u=503349&s=70530&n=18&f=138&t=108126&p=899394>)



([modules.php?name=Forums&file=posting&mode=reply&t=108126](http://www.rxpgonline.com/modules.php?name=Forums&file=posting&mode=reply&t=108126)) ([quote](http://www.rxpgonline.com/modules.php?name=Forums&file=posting&mode=quote&p=899394))



(<http://www.rxpgonline.com/modules.php?name=RxPGites&mode=scrapbook&uid=70530>) ([PM](http://www.rxpgonline.com/modules.php?name=Private_Messages&file=index&mode=post&u=))



esmeralda (<http://www.rxpgonline.com/threads44973.html>)

(<http://www.rxpgonline.com/modules.php?name=Messenger&file=buddy&op=compose&to=esmeralda>)

Senior Guru



Posts: 413

Credits: 6120 (<http://www.rxpgonline.com/docs/credits>)

Aim PLAB Part 2 (<http://www.rxpgonline.com/forum175.htm>)

Back to top

This is fantastic.Thanks,Syrian!

report this post to a moderator (<http://www.rxpgonline.com/report/index.php?p=899460&h=19&u=>)

please rate this post (<http://www.rxpgonline.com/modules.php?name=usertools&file=pvote&vote=up&u=503349&s=44973&n=19&f=138&t=108126&p=899460>)

(<http://www.rxpgonline.com/modules.php?name=usertools&file=pvote&vote=down&u=503349&s=44973&n=19&f=138&t=108126&p=899460>)



([modules.php?name=Forums&file=posting&mode=reply&t=108126](http://www.rxpgonline.com/modules.php?name=Forums&file=posting&mode=reply&t=108126)) ([quote](http://www.rxpgonline.com/modules.php?name=Forums&file=posting&mode=quote&p=899460))



(<http://www.rxpgonline.com/modules.php?name=RxPGites&mode=scrapbook&uid=44973>) ([PM](http://www.rxpgonline.com/modules.php?name=Private_Messages&file=index&mode=post&u=))



blaila (<http://www.rxpgonline.com/threads60017.html>)

(<http://www.rxpgonline.com/modules.php?name=Messenger&file=buddy&op=compose&to=blaila>)

Elite Veteran



Posts: 80

Credits: 1240 (<http://www.rxpgonline.com/docs/credits>)

Aim MRCP Part 1 (<http://www.rxpgonline.com/forum11.htm>)

Back to top

great effort
have u finished the plab?

report this post to a moderator (<http://www.rxpgonline.com/report/index.php?p=899686&h=20&u=>)

please rate this post (<http://www.rxpgonline.com/modules.php?name=usertools&file=pvote&vote=up&u=503349&s=60017&n=20&f=138&t=108126&p=899686>)

(<http://www.rxpgonline.com/modules.php?name=usertools&file=pvote&vote=down&u=503349&s=60017&n=20&f=138&t=108126&p=899686>)



([modules.php?name=Forums&file=posting&mode=reply&t=108126](http://www.rxpgonline.com/modules.php?name=Forums&file=posting&mode=reply&t=108126)) ([quote](http://www.rxpgonline.com/modules.php?name=Forums&file=posting&mode=quote&p=899686))




(<http://www.rxpgonline.com/modules.php?name=RxPGites&mode=scrapbook&uid=60017>) ([PM](http://www.rxpgonline.com/modules.php?name=Private_Messages&file=index&mode=post&u=))



stresshead83 (<http://www.rxpgonline.com/threads81203.html>)

(<http://www.rxpgonline.com/modules.php?name=Messenger&file=buddy&op=compose&to=stresshead83>)

Senior Veteran



Posts: 65

Credits: 1177 (<http://www.rxpgonline.com/docs/credits>)

Aim PLAB Part 2 (<http://www.rxpgonline.com/forum175.htm>)

Back to top

thanks a lot

report this post to a moderator (<http://www.rxpgonline.com/report/index.php?p=899801&h=21&u=>)

please rate this post (<http://www.rxpgonline.com/modules.php?name=usertools&file=pvote&vote=up&u=503349&s=81203&n=21&f=138&t=108126&p=899801>)

(<http://www.rxpgonline.com/modules.php?name=usertools&file=pvote&vote=down&u=503349&s=81203&n=21&f=138&t=108126&p=899801>)



([modules.php?name=Forums&file=posting&mode=reply&t=108126](http://www.rxpgonline.com/modules.php?name=Forums&file=posting&mode=reply&t=108126)) ([quote](http://www.rxpgonline.com/modules.php?name=Forums&file=posting&mode=quote&p=899801))



(<http://www.rxpgonline.com/modules.php?name=RxPGites&mode=scrapbook&uid=81203>) ([PM](http://www.rxpgonline.com/modules.php?name=Private_Messages&file=index&mode=post&u=))



Syrian (<http://www.rxpgonline.com/threads70530.html>)

(<http://www.rxpgonline.com/modules.php?name=Messenger&file=buddy&op=compose&to=Syrian>)



Titan







Quote:

Posts: 124
Credits: 7019 (<http://www.rxpgonline.com/docs/credits>)



Nop blaila , i will appear in september exam

report this post to a moderator (<http://www.rxpgonline.com/report/index.php?p=899865&h=22&u=>)
please rate this post  (<http://www.rxpgonline.com/modules.php?name=usertools&file=pvote&vote=up&u=503349&s=70530&n=22&f=138&t=108126&p=899865>) 
(<http://www.rxpgonline.com/modules.php?name=usertools&file=pvote&vote=down&u=503349&s=70530&n=22&f=138&t=108126&p=899865>)

 [Reply](#) (modules.php?name=Forums&file=posting&mode=reply&t=108126)  [quote](#) (modules.php?name=Forums&file=posting&mode=quote&p=899865)  [Scrapbook](#) (<http://www.rxpgonline.com/modules.php?name=RxPGites&mode=scrapbook&uid=70530>)  [PM](#) (modules.php?name=Private_Messages&file=index&mode=post&u=)



Back to top







gf (<http://www.rxpgonline.com/threads98904.html>) 
(<http://www.rxpgonline.com/modules.php?name=Messenger&file=buddy&op=compose&to=gf>)
Elite Titan


Posts: 266
Credits: 2972 (<http://www.rxpgonline.com/docs/credits>)
Aim PLAB Part 1 (<http://www.rxpgonline.com/forum138.htm>)


thx...

report this post to a moderator (<http://www.rxpgonline.com/report/index.php?p=903860&h=23&u=>)
please rate this post  (<http://www.rxpgonline.com/modules.php?name=usertools&file=pvote&vote=up&u=503349&s=98904&n=23&f=138&t=108126&p=903860>) 
(<http://www.rxpgonline.com/modules.php?name=usertools&file=pvote&vote=down&u=503349&s=98904&n=23&f=138&t=108126&p=903860>)

 [Reply](#) (modules.php?name=Forums&file=posting&mode=reply&t=108126)  [quote](#) (modules.php?name=Forums&file=posting&mode=quote&p=903860)  [Scrapbook](#) (<http://www.rxpgonline.com/modules.php?name=RxPGites&mode=scrapbook&uid=98904>)  [PM](#) (modules.php?name=Private_Messages&file=index&mode=post&u=)



Back to top







piagoy (<http://www.rxpgonline.com/threads107010.html>) 
(<http://www.rxpgonline.com/modules.php?name=Messenger&file=buddy&op=compose&to=piagoy>)
Expert Member
☆☆☆☆☆

Posts: 24
Credits: 345 (<http://www.rxpgonline.com/docs/credits>)
Aim PLAB Part 1 (<http://www.rxpgonline.com/forum138.htm>)



tnx syrian for the lengthy effort x
i hav a query for u ,the question on feb2010
whats the screening for spina bifida? is it not afp..
while definitive dx is by usg?
hope u cn clear tis 1 for me.. many thnx again

report this post to a moderator (<http://www.rxpgonline.com/report/index.php?p=905513&h=24&u=>)
please rate this post  (<http://www.rxpgonline.com/modules.php?name=usertools&file=pvote&vote=up&u=503349&s=107010&n=24&f=138&t=108126&p=905513>) 
(<http://www.rxpgonline.com/modules.php?name=usertools&file=pvote&vote=down&u=503349&s=107010&n=24&f=138&t=108126&p=905513>)

 [Reply](#) (modules.php?name=Forums&file=posting&mode=reply&t=108126)  [quote](#) (modules.php?name=Forums&file=posting&mode=quote&p=905513)  [Scrapbook](#) (<http://www.rxpgonline.com/modules.php?name=RxPGites&mode=scrapbook&uid=107010>)  [PM](#) (modules.php?name=Private_Messages&file=index&mode=post&u=1)



Back to top







Syrian (<http://www.rxpgonline.com/threads70530.html>) 
(<http://www.rxpgonline.com/modules.php?name=Messenger&file=buddy&op=compose&to=Syrian>)
Titan


Posts: 124
Credits: 7019 (<http://www.rxpgonline.com/docs/credits>)


hi piagoy .
I suggest if u can check gp notebook or OHCS .

report this post to a moderator (<http://www.rxpgonline.com/report/index.php?p=905668&h=25&u=>)
please rate this post  (<http://www.rxpgonline.com/modules.php?name=usertools&file=pvote&vote=up&u=503349&s=70530&n=25&f=138&t=108126&p=905668>) 
(<http://www.rxpgonline.com/modules.php?name=usertools&file=pvote&vote=down&u=503349&s=70530&n=25&f=138&t=108126&p=905668>)

 [Reply](#) (modules.php?name=Forums&file=posting&mode=reply&t=108126)  [quote](#) (modules.php?name=Forums&file=posting&mode=quote&p=905668)  [Scrapbook](#) (<http://www.rxpgonline.com/modules.php?name=RxPGites&mode=scrapbook&uid=70530>)  [PM](#) (modules.php?name=Private_Messages&file=index&mode=post&u=)

Back to top



doctorplab1 (<http://www.rxpgonline.com/threads92593.html>) 
(<http://www.rxpgonline.com/modules.php?name=Messenger&file=buddy&op=compose&to=doctorplab1>)
Titan

thanx, it will really help us.



Posts: 116
Credits: 1486 (<http://www.rxpgonline.com/docs/credits>)
Aim MRCP Part 1 (<http://www.rxpgonline.com/forum11.htm>)

Back to top

report this post to a moderator (<http://www.rxpgonline.com/report/index.php?p=905782&h=26&u=>)
please rate this post (<http://www.rxpgonline.com/modules.php?name=usertools&file=pvote&vote=up&u=503349&s=92593&n=26&f=138&t=108126&p=905782>) (<http://www.rxpgonline.com/modules.php?name=usertools&file=pvote&vote=down&u=503349&s=92593&n=26&f=138&t=108126&p=905782>)

[Reply](http://www.rxpgonline.com/modules.php?name=Forums&file=posting&mode=reply&t=108126) (modules.php?name=Forums&file=posting&mode=reply&t=108126) [quote](http://www.rxpgonline.com/modules.php?name=Forums&file=posting&mode=quote&p=905782) (modules.php?name=Forums&file=posting&mode=quote&p=905782) [Scrapbook](http://www.rxpgonline.com/modules.php?name=RxPGites&mode=scrapbook&uid=92593) (http://www.rxpgonline.com/modules.php?name=RxPGites&mode=scrapbook&uid=92593) [PM](http://www.rxpgonline.com/modules.php?name=Private_Messages&file=index&mode=post&u=) (modules.php?name=Private_Messages&file=index&mode=post&u=)



esmeralda (<http://www.rxpgonline.com/threads44973.html>)
 (<http://www.rxpgonline.com/modules.php?name=Messenger&file=buddy&op=compose&to=esmeralda>)
Senior Guru

Posts: 413
Credits: 6120 (<http://www.rxpgonline.com/docs/credits>)
Aim PLAB Part 2 (<http://www.rxpgonline.com/forum175.htm>)

Back to top

Fri May 28, 2010 3:14 am (4 years ago) **#27** (modules.php?name=Forums&file=viewpost&)

@Piagoy, you are right.
Maternal serum alpha feto-protein will be done for screening of spina bifida. If the result is then the detailed ultrasound examination will be carried out

report this post to a moderator (<http://www.rxpgonline.com/report/index.php?p=905802&h=27&u=>)
please rate this post (<http://www.rxpgonline.com/modules.php?name=usertools&file=pvote&vote=up&u=503349&s=44973&n=27&f=138&t=108126&p=905802>) (<http://www.rxpgonline.com/modules.php?name=usertools&file=pvote&vote=down&u=503349&s=44973&n=27&f=138&t=108126&p=905802>)

[Reply](http://www.rxpgonline.com/modules.php?name=Forums&file=posting&mode=reply&t=108126) (modules.php?name=Forums&file=posting&mode=reply&t=108126) [quote](http://www.rxpgonline.com/modules.php?name=Forums&file=posting&mode=quote&p=905802) (modules.php?name=Forums&file=posting&mode=quote&p=905802) [Scrapbook](http://www.rxpgonline.com/modules.php?name=RxPGites&mode=scrapbook&uid=44973) (http://www.rxpgonline.com/modules.php?name=RxPGites&mode=scrapbook&uid=44973) [PM](http://www.rxpgonline.com/modules.php?name=Private_Messages&file=index&mode=post&u=) (modules.php?name=Private_Messages&file=index&mode=post&u=)



nileshagrawal (<http://www.rxpgonline.com/threads118592.html>)
 (<http://www.rxpgonline.com/modules.php?name=Messenger&file=buddy&op=compose&to=nileshagrawal>)
Addicted Member
☆☆☆☆☆
Posts: 14
Credits: 277 (<http://www.rxpgonline.com/docs/credits>)
Aim PLAB Part 1 (<http://www.rxpgonline.com/forum138.htm>)

Back to top

Fri Jun 11, 2010 12:51 pm (4 years ago) **#28** (modules.php?name=Forums&file=viewpost&)

Really kind of you to help out so many people... Thanks!

report this post to a moderator (<http://www.rxpgonline.com/report/index.php?p=916218&h=28&u=>)
please rate this post (<http://www.rxpgonline.com/modules.php?name=usertools&file=pvote&vote=up&u=503349&s=118592&n=28&f=138&t=108126&p=916218>) (<http://www.rxpgonline.com/modules.php?name=usertools&file=pvote&vote=down&u=503349&s=118592&n=28&f=138&t=108126&p=916218>)

[Reply](http://www.rxpgonline.com/modules.php?name=Forums&file=posting&mode=reply&t=108126) (modules.php?name=Forums&file=posting&mode=reply&t=108126) [quote](http://www.rxpgonline.com/modules.php?name=Forums&file=posting&mode=quote&p=916218) (modules.php?name=Forums&file=posting&mode=quote&p=916218) [Scrapbook](http://www.rxpgonline.com/modules.php?name=RxPGites&mode=scrapbook&uid=118592) (http://www.rxpgonline.com/modules.php?name=RxPGites&mode=scrapbook&uid=118592) [PM](http://www.rxpgonline.com/modules.php?name=Private_Messages&file=index&mode=post&u=1) (modules.php?name=Private_Messages&file=index&mode=post&u=1)



Konduri (<http://www.rxpgonline.com/threads90850.html>)
 (<http://www.rxpgonline.com/modules.php?name=Messenger&file=buddy&op=compose&to=Konduri>)
Elite Member
☆☆☆☆☆
Posts: 33
Credits: 792 (<http://www.rxpgonline.com/docs/credits>)
Aim MRCOG Part 1 (<http://www.rxpgonline.com/forum144.htm>)

Back to top

Fri Jun 11, 2010 6:58 pm (4 years ago) **#29** (modules.php?name=Forums&file=viewpost&)

thank you so much syrian, it is really very helpful.

report this post to a moderator (<http://www.rxpgonline.com/report/index.php?p=916365&h=29&u=>)
please rate this post (<http://www.rxpgonline.com/modules.php?name=usertools&file=pvote&vote=up&u=503349&s=90850&n=29&f=138&t=108126&p=916365>) (<http://www.rxpgonline.com/modules.php?name=usertools&file=pvote&vote=down&u=503349&s=90850&n=29&f=138&t=108126&p=916365>)

[Reply](http://www.rxpgonline.com/modules.php?name=Forums&file=posting&mode=reply&t=108126) (modules.php?name=Forums&file=posting&mode=reply&t=108126) [quote](http://www.rxpgonline.com/modules.php?name=Forums&file=posting&mode=quote&p=916365) (modules.php?name=Forums&file=posting&mode=quote&p=916365) [Scrapbook](http://www.rxpgonline.com/modules.php?name=RxPGites&mode=scrapbook&uid=90850) (http://www.rxpgonline.com/modules.php?name=RxPGites&mode=scrapbook&uid=90850) [PM](http://www.rxpgonline.com/modules.php?name=Private_Messages&file=index&mode=post&u=) (modules.php?name=Private_Messages&file=index&mode=post&u=)



doc__doc (<http://www.rxpgonline.com/threads57573.html>)
 (http://www.rxpgonline.com/modules.php?name=Messenger&file=buddy&op=compose&to=doc__doc)
Serious Veteran
☆☆☆☆☆
Posts: 41
Credits: 647 (<http://www.rxpgonline.com/docs/credits>)
Aim PLAB Part 2 (<http://www.rxpgonline.com/forum175.htm>)

<http://www.rxpgonline.com/postt108126.html>

Mon Jun 21, 2010 6:03 am (4 years ago) **#30** (modules.php?name=Forums&file=viewpost&)

thnx alot

My Gawddddd!!!!u have done amazing work
All my questions got answered:)
thnx alot

report this post to a moderator (<http://www.rxpgonline.com/report/index.php?p=921650&h=30&u=>)
please rate this post (<http://www.rxpgonline.com/modules.php?name=usertools&file=pvote&vote=up&u=503349&s=57573&n=30&f=138&t=108126&p=921650>) (<http://www.rxpgonline.com/modules.php?name=usertools&file=pvote&vote=down&u=503349&s=57573&n=30&f=138&t=108126&p=921650>)

name=usertools&file=pvote&vote=up&u=503349&s=57573&n=30&f=138&t=108126&p=921650) (http://www.rxpgonline.com/modules.php?name=usertools&file=pvote&vote=down&u=503349&s=57573&n=30&f=138&t=108126&p=921650) (modules.php?name=Forums&file=posting&mode=reply&t=108126) (modules.php?name=Forums&file=posting&mode=quote&p=921650) (http://www.rxpgonline.com/modules.php?name=RxPGites&mode=scrapbook&uid=57573) (modules.php?name=Private_Messages&file=index&mode=post&u=

Back to top



PLAB1942 (http://www.rxpgonline.com/threads110713.html) (http://www.rxpgonline.com/modules.php?name=Messenger&file=buddy&op=compose&to=PLAB1942) Senior Titan
 Posts: 195
 Credits: 2759 (http://www.rxpgonline.com/docs/credits)
 Aim PLAB Part 2 (http://www.rxpgonline.com/forum175.htm)

gr8 job syrian. tnx a lot.

report this post to a moderator (http://www.rxpgonline.com/report/index.php?p=922151&h=31&u=) please rate this post (http://www.rxpgonline.com/modules.php?name=usertools&file=pvote&vote=up&u=503349&s=110713&n=31&f=138&t=108126&p=922151) (http://www.rxpgonline.com/modules.php?name=usertools&file=pvote&vote=down&u=503349&s=110713&n=31&f=138&t=108126&p=922151) (modules.php?name=Forums&file=posting&mode=reply&t=108126) (modules.php?name=Forums&file=posting&mode=quote&p=922151) (http://www.rxpgonline.com/modules.php?name=RxPGites&mode=scrapbook&uid=110713) (modules.php?name=Private_Messages&file=index&mode=post&u=1

Back to top



taylanonur (http://www.rxpgonline.com/threads92226.html) (http://www.rxpgonline.com/modules.php?name=Messenger&file=buddy&op=compose&to=taylanonur) Addicted Member
 Posts: 14
 Credits: 292 (http://www.rxpgonline.com/docs/credits)
 Aim MRCPsych Paper 1 (http://www.rxpgonline.com/forum62.htm)

This is wonderful. Thanks for your time and effort

report this post to a moderator (http://www.rxpgonline.com/report/index.php?p=922876&h=32&u=) please rate this post (http://www.rxpgonline.com/modules.php?name=usertools&file=pvote&vote=up&u=503349&s=92226&n=32&f=138&t=108126&p=922876) (http://www.rxpgonline.com/modules.php?name=usertools&file=pvote&vote=down&u=503349&s=92226&n=32&f=138&t=108126&p=922876) (modules.php?name=Forums&file=posting&mode=reply&t=108126) (modules.php?name=Forums&file=posting&mode=quote&p=922876) (http://www.rxpgonline.com/modules.php?name=RxPGites&mode=scrapbook&uid=92226) (modules.php?name=Private_Messages&file=index&mode=post&u=

Back to top



hamadashraf (http://www.rxpgonline.com/threads120282.html) (http://www.rxpgonline.com/modules.php?name=Messenger&file=buddy&op=compose&to=hamadashraf) Senior Veteran
 Posts: 73
 Credits: 1595 (http://www.rxpgonline.com/docs/credits)
 Aim PLAB Part 2 (http://www.rxpgonline.com/forum175.htm)
 Location: Lahore, Pakistan

thank u so much dear... thats really a great effort, wish u a good career in UK

report this post to a moderator (http://www.rxpgonline.com/report/index.php?p=925423&h=33&u=) please rate this post (http://www.rxpgonline.com/modules.php?name=usertools&file=pvote&vote=up&u=503349&s=120282&n=33&f=138&t=108126&p=925423) (http://www.rxpgonline.com/modules.php?name=usertools&file=pvote&vote=down&u=503349&s=120282&n=33&f=138&t=108126&p=925423) (modules.php?name=Forums&file=posting&mode=reply&t=108126) (modules.php?name=Forums&file=posting&mode=quote&p=925423) (http://www.rxpgonline.com/modules.php?name=RxPGites&mode=scrapbook&uid=120282) (modules.php?name=Private_Messages&file=index&mode=post&u=1

Back to top



Syrian (http://www.rxpgonline.com/threads70530.html) (http://www.rxpgonline.com/modules.php?name=Messenger&file=buddy&op=compose&to=Syrian) Titan
 Posts: 124
 Credits: 7019 (http://www.rxpgonline.com/docs/credits)

Well guys i did nothing , i just collected and pasted .
 Thank you all for you wishes

report this post to a moderator (http://www.rxpgonline.com/report/index.php?p=925648&h=34&u=) please rate this post (http://www.rxpgonline.com/modules.php?name=usertools&file=pvote&vote=up&u=503349&s=70530&n=34&f=138&t=108126&p=925648) (http://www.rxpgonline.com/modules.php?name=usertools&file=pvote&vote=down&u=503349&s=70530&n=34&f=138&t=108126&p=925648) (modules.php?name=Forums&file=posting&mode=reply&t=108126) (modules.php?name=Forums&file=posting&mode=quote&p=925648) (http://www.rxpgonline.com/modules.php?name=RxPGites&mode=scrapbook&uid=70530) (modules.php?name=Private_Messages&file=index&mode=post&u=

Back to top

name=Private_Messages&file=index&mode=post&u=



jeetex (<http://www.rxpgonline.com/threads92712.html>)
(<http://www.rxpgonline.com/modules.php?name=Messenger&file=buddy&op=compose&to=jeetex>)
Serious Veteran
☆☆☆☆☆
Posts: 44
Credits: 800 (<http://www.rxpgonline.com/docs/credits>)
Aim UK Exams (<http://www.rxpgonline.com/forum.htm>)

Tue Jul 06, 2010 11:33 pm (4 years ago) #35 (modules.php?name=Forums&file=viewpost&

wish u pass dis time

wishing u pass dis time syriani still rember the badluck we both had...124 i lol.....but

report this post to a moderator (<http://www.rxpgonline.com/report/index.php?p=927910&h=35&u=>)
please rate this post (<http://www.rxpgonline.com/modules.php?name=usertools&file=pvote&vote=up&u=503349&s=92712&n=35&f=138&t=108126&p=927910>)
(<http://www.rxpgonline.com/modules.php?name=usertools&file=pvote&vote=down&u=503349&s=92712&n=35&f=138&t=108126&p=927910>)

[Reply](#) (modules.php?name=Forums&file=posting&mode=reply&t=108126) [quote](#) (modules.php?name=Forums&file=posting&mode=quote&p=927910) [Scrapbook](#) (<http://www.rxpgonline.com/module=RxPGites&mode=scrapbook&uid=92712>) [PM](#) (modules.php?name=Private_Messages&file=index&mode=post&u=

Back to top



Syrian (<http://www.rxpgonline.com/threads70530.html>)
(<http://www.rxpgonline.com/modules.php?name=Messenger&file=buddy&op=compose&to=Syrian>)
Titan
☆☆☆☆☆
Posts: 124
Credits: 7019 (<http://www.rxpgonline.com/docs/credits>)

Wed Jul 07, 2010 9:49 am (4 years ago) #36 (modules.php?name=Forums&file=viewpost&

Re: wish u pass dis time

jeetex wrote:

wishing u pass dis time syriani still rember the badluck we both had...124 it was lol.....but

hhhh it was 123 , unforgettable experince .
i hope we all do it this time....

report this post to a moderator (<http://www.rxpgonline.com/report/index.php?p=928044&h=36&u=>)
please rate this post (<http://www.rxpgonline.com/modules.php?name=usertools&file=pvote&vote=up&u=503349&s=70530&n=36&f=138&t=108126&p=928044>)
(<http://www.rxpgonline.com/modules.php?name=usertools&file=pvote&vote=down&u=503349&s=70530&n=36&f=138&t=108126&p=928044>)

[Reply](#) (modules.php?name=Forums&file=posting&mode=reply&t=108126) [quote](#) (modules.php?name=Forums&file=posting&mode=quote&p=928044) [Scrapbook](#) (<http://www.rxpgonline.com/module=RxPGites&mode=scrapbook&uid=70530>) [PM](#) (modules.php?name=Private_Messages&file=index&mode=post&u=

Back to top



simplicity (<http://www.rxpgonline.com/threads119608.html>)
(<http://www.rxpgonline.com/modules.php?name=Messenger&file=buddy&op=compose&to=simplicity>)
Senior Veteran
☆☆☆☆☆
Posts: 57
Credits: 1140 (<http://www.rxpgonline.com/docs/credits>)
Aim PLAB Part 2 (<http://www.rxpgonline.com/forum175.htm>)

Wed Jul 07, 2010 7:33 pm (4 years ago) #37 (modules.php?name=Forums&file=viewpost&

past papers

hi syrian, i have started a new thread "Lets solve past papers" in which we are going to solve papers u have added... i wanted to know that have u solved these recalls and are u sure i the answers u have given?

report this post to a moderator (<http://www.rxpgonline.com/report/index.php?p=928204&h=37&u=>)
please rate this post (<http://www.rxpgonline.com/modules.php?name=usertools&file=pvote&vote=up&u=503349&s=119608&n=37&f=138&t=108126&p=928204>)
(<http://www.rxpgonline.com/modules.php?name=usertools&file=pvote&vote=down&u=503349&s=119608&n=37&f=138&t=108126&p=928204>)

[Reply](#) (modules.php?name=Forums&file=posting&mode=reply&t=108126) [quote](#) (modules.php?name=Forums&file=posting&mode=quote&p=928204) [Scrapbook](#) (<http://www.rxpgonline.com/module=RxPGites&mode=scrapbook&uid=119608>) [PM](#) (modules.php?name=Private_Messages&file=index&mode=post&u=1

Back to top





Syrian (<http://www.rxpgonline.com/threads70530.html>)
(<http://www.rxpgonline.com/modules.php?name=Messenger&file=buddy&op=compose&to=Syrian>)
Titan
☆☆☆☆☆
Posts: 124
Credits: 7019 (<http://www.rxpgonline.com/docs/credits>)






Thu Jul 08, 2010 10:26 am (4 years ago) #38 (modules.php?name=Forums&file=viewpost&

Re: past papers

simplicity wrote:


hi syrian, i have started a new thread "Lets solve past papers" in which we are going to solve the papers have added... i wanted to know that have u solved these recalls and are u sure abt all the answers u have given?

	<p>i will be glad to participate .</p> <p>As i said when i posted the thread , im not sure about the answers , because i just collected them .</p> <p>so check them .</p> <p>all the best</p> <p>report this post to a moderator (http://www.rxpgonline.com/report/index.php?p=928409&h=38&u=)</p> <p>please rate this post  (http://www.rxpgonline.com/modules.php?name=usertools&file=pvote&vote=up&u=503349&s=70530&n=38&f=138&t=108126&p=928409) </p> <p>(http://www.rxpgonline.com/modules.php?name=usertools&file=pvote&vote=down&u=503349&s=70530&n=38&f=138&t=108126&p=928409)</p>
Back to top	<p> Reply (modules.php?name=Forums&file=posting&mode=reply&t=108126)  quote (modules.php?name=Forums&file=posting&mode=quote&p=928409)  Scrapbook (http://www.rxpgonline.com/modules.php?name=RxPGites&mode=scrapbook&uid=70530)  PM (modules.php?name=Private_Messages&file=index&mode=post&u=</p>
sakis19762010 (http://www.rxpgonline.com/threads122233.html) #suspended (http://www.rxpgonline.com/docs/suspension)	<p> Fri Jul 30, 2010 7:46 am (4 years ago) #39 (modules.php?name=Forums&file=viewpost&</p> <p><i>#All posts made by this person are deleted by RxPG Bot because of the violaion of RxPG terms of service (http://www.rxpgonline.com/docs/tos). Please make sure that you observe RxPG TOS while posting in forums or elsewhere ii</i></p> <p>report this post to a moderator (http://www.rxpgonline.com/report/index.php?p=936454&h=39&u=)</p> <p>please rate this post  (http://www.rxpgonline.com/modules.php?name=usertools&file=pvote&vote=up&u=503349&s=122233&n=39&f=138&t=108126&p=936454) </p> <p>(http://www.rxpgonline.com/modules.php?name=usertools&file=pvote&vote=down&u=503349&s=122233&n=39&f=138&t=108126&p=936454)</p>
Back to top	<p> Reply (modules.php?name=Forums&file=posting&mode=reply&t=108126)  quote (modules.php?name=Forums&file=posting&mode=quote&p=936454)  Scrapbook (http://www.rxpgonline.com/modules.php?name=RxPGites&mode=scrapbook&uid=122233)  PM (modules.php?name=Private_Messages&file=index&mode=post&u=1</p>
sakis19762010 (http://www.rxpgonline.com/threads122233.html) #suspended (http://www.rxpgonline.com/docs/suspension)	<p> Sat Jul 31, 2010 10:56 pm (4 years ago) #40 (modules.php?name=Forums&file=viewpost&</p> <p><i>#All posts made by this person are deleted by RxPG Bot because of the violaion of RxPG terms of service (http://www.rxpgonline.com/docs/tos). Please make sure that you observe RxPG TOS while posting in forums or elsewhere ii</i></p> <p>report this post to a moderator (http://www.rxpgonline.com/report/index.php?p=937183&h=40&u=)</p> <p>please rate this post  (http://www.rxpgonline.com/modules.php?name=usertools&file=pvote&vote=up&u=503349&s=122233&n=40&f=138&t=108126&p=937183) </p> <p>(http://www.rxpgonline.com/modules.php?name=usertools&file=pvote&vote=down&u=503349&s=122233&n=40&f=138&t=108126&p=937183)</p>
Back to top	<p> Reply (modules.php?name=Forums&file=posting&mode=reply&t=108126)  quote (modules.php?name=Forums&file=posting&mode=quote&p=937183)  Scrapbook (http://www.rxpgonline.com/modules.php?name=RxPGites&mode=scrapbook&uid=122233)  PM (modules.php?name=Private_Messages&file=index&mode=post&u=1</p>
 eliashayan (http://www.rxpgonline.com/threads120045.html)  (http://www.rxpgonline.com/modules.php?name=Messenger&file=buddy&op=compose&to=eliashayan) Elite Veteran ☆☆☆☆☆ Posts: 87 Credits: 1065 (http://www.rxpgonline.com/docs/credits) Aim PGIMS (http://www.rxpgonline.com/forum51.htm)	<p>Sun Aug 08, 2010 5:26 am (4 years ago) #41 (modules.php?name=Forums&file=viewpost&</p> <p>thanks a lot its realy wonderfull</p> <p>report this post to a moderator (http://www.rxpgonline.com/report/index.php?p=939925&h=41&u=)</p> <p>please rate this post  (http://www.rxpgonline.com/modules.php?name=usertools&file=pvote&vote=up&u=503349&s=120045&n=41&f=138&t=108126&p=939925) </p> <p>(http://www.rxpgonline.com/modules.php?name=usertools&file=pvote&vote=down&u=503349&s=120045&n=41&f=138&t=108126&p=939925)</p>
Back to top	<p> Reply (modules.php?name=Forums&file=posting&mode=reply&t=108126)  quote (modules.php?name=Forums&file=posting&mode=quote&p=939925)  Scrapbook (http://www.rxpgonline.com/modules.php?name=RxPGites&mode=scrapbook&uid=120045)  PM (modules.php?name=Private_Messages&file=index&mode=post&u=1</p>
 Swinaa (http://www.rxpgonline.com/threads123647.html)  (http://www.rxpgonline.com/modules.php?name=Messenger&file=buddy&op=compose&to=Swinaa) Senior Member ☆☆☆☆☆ Posts: 28 Credits: 411 (http://www.rxpgonline.com/docs/credits) Aim PLAB Part 1 (http://www.rxpgonline.com/forum138.htm)	<p>Sun Aug 08, 2010 7:14 am (4 years ago) #42 (modules.php?name=Forums&file=viewpost&</p> <p>Thank you Syrian 🙏</p> <p>report this post to a moderator (http://www.rxpgonline.com/report/index.php?p=939947&h=42&u=)</p> <p>please rate this post  (http://www.rxpgonline.com/modules.php?name=usertools&file=pvote&vote=up&u=503349&s=120045&n=42&f=138&t=108126&p=939947) </p>







name=usertools&file=pvote&vote=up&u=503349&s=123647&n=42&f=138&t=108126&p=939947)  (http://www.rxpgonline.com/modules.php?name=usertools&file=pvote&vote=down&u=503349&s=123647&n=42&f=138&t=108126&p=939947)  [Reply](#) (modules.php?name=Forums&file=posting&mode=reply&t=108126)  [quote](#) (modules.php?name=Forums&file=posting&mode=quote&p=939947)  [Scrapbook](#) (http://www.rxpgonline.com/modules.php?name=RxPGites&mode=scrapbook&uid=123647)  [PM](#) (modules.php?name=Private_Messages&file=index&mode=post&u=1)

Back to top

sakis19762010
(http://www.rxpgonline.com/threads122233.html)
#suspended (http://www.rxpgonline.com/docs/suspension)


 Sat Aug 14, 2010 7:29 am (4 years ago) **#43** (modules.php?name=Forums&file=viewpost&tid=122233)

#All posts made by this person are deleted by RxPG Bot because of the violaion of RxPG terms of service (http://www.rxpgonline.com/docs/tos). Please make sure that you observe RxPG TOS while posting in forums or elsewhere in the site.







report this post to a moderator (http://www.rxpgonline.com/report/index.php?p=943146&h=43&u=) please rate this post  (http://www.rxpgonline.com/modules.php?name=usertools&file=pvote&vote=up&u=503349&s=122233&n=43&f=138&t=108126&p=943146)  (http://www.rxpgonline.com/modules.php?name=usertools&file=pvote&vote=down&u=503349&s=122233&n=43&f=138&t=108126&p=943146)  [Reply](#) (modules.php?name=Forums&file=posting&mode=reply&t=108126)  [quote](#) (modules.php?name=Forums&file=posting&mode=quote&p=943146)  [Scrapbook](#) (http://www.rxpgonline.com/modules.php?name=RxPGites&mode=scrapbook&uid=122233)  [PM](#) (modules.php?name=Private_Messages&file=index&mode=post&u=1)

Back to top

sakis19762010
(http://www.rxpgonline.com/threads122233.html)
#suspended (http://www.rxpgonline.com/docs/suspension)


 Mon Aug 16, 2010 6:16 am (4 years ago) **#44** (modules.php?name=Forums&file=viewpost&tid=122233)


#All posts made by this person are deleted by RxPG Bot because of the violaion of RxPG terms of service (http://www.rxpgonline.com/docs/tos). Please make sure that you observe RxPG TOS while posting in forums or elsewhere in the site.

report this post to a moderator (http://www.rxpgonline.com/report/index.php?p=944461&h=44&u=) please rate this post  (http://www.rxpgonline.com/modules.php?name=usertools&file=pvote&vote=up&u=503349&s=122233&n=44&f=138&t=108126&p=944461)  (http://www.rxpgonline.com/modules.php?name=usertools&file=pvote&vote=down&u=503349&s=122233&n=44&f=138&t=108126&p=944461)  [Reply](#) (modules.php?name=Forums&file=posting&mode=reply&t=108126)  [quote](#) (modules.php?name=Forums&file=posting&mode=quote&p=944461)  [Scrapbook](#) (http://www.rxpgonline.com/modules.php?name=RxPGites&mode=scrapbook&uid=122233)  [PM](#) (modules.php?name=Private_Messages&file=index&mode=post&u=1)

Back to top









shankares2002
(http://www.rxpgonline.com/threads112611.html) 
(http://www.rxpgonline.com/modules.php?name=Messenger&file=buddy&op=compose&to=shankares2002)
Senior Veteran
☆☆☆☆☆
Posts: 67
Credits: 1146 (http://www.rxpgonline.com/docs/credits)
Aim MRCP Part 1 (http://www.rxpgonline.com/forum11.htm)

 Wed Aug 25, 2010 7:12 pm (4 years ago) **#45** (modules.php?name=Forums&file=viewpost&tid=112611)


thankyou


Thank you very much for taking the time to help us all.

report this post to a moderator (http://www.rxpgonline.com/report/index.php?p=950852&h=45&u=) please rate this post  (http://www.rxpgonline.com/modules.php?name=usertools&file=pvote&vote=up&u=503349&s=112611&n=45&f=138&t=108126&p=950852)  (http://www.rxpgonline.com/modules.php?name=usertools&file=pvote&vote=down&u=503349&s=112611&n=45&f=138&t=108126&p=950852)  [Reply](#) (modules.php?name=Forums&file=posting&mode=reply&t=108126)  [quote](#) (modules.php?name=Forums&file=posting&mode=quote&p=950852)  [Scrapbook](#) (http://www.rxpgonline.com/modules.php?name=RxPGites&mode=scrapbook&uid=112611)  [PM](#) (modules.php?name=Private_Messages&file=index&mode=post&u=1)







Back to top



doctor7860 (http://www.rxpgonline.com/threads109398.html) 
(http://www.rxpgonline.com/modules.php?name=Messenger&file=buddy&op=compose&to=doctor7860)
Elite Veteran
☆☆☆☆☆
Posts: 86
Credits: 1497 (http://www.rxpgonline.com/docs/credits)
Aim MRCP Part 1 (http://www.rxpgonline.com/forum11.htm)

 Wed Sep 08, 2010 3:25 am (4 years ago) **#46** (modules.php?name=Forums&file=viewpost&tid=109398)

Thank you very much for such a great effort for all of us. My prayers and best wishes for you the best to every one here for plab1 exams.

report this post to a moderator (http://www.rxpgonline.com/report/index.php?p=959577&h=46&u=) please rate this post  (http://www.rxpgonline.com/modules.php?name=usertools&file=pvote&vote=up&u=503349&s=109398&n=46&f=138&t=108126&p=959577)  (http://www.rxpgonline.com/modules.php?name=usertools&file=pvote&vote=down&u=503349&s=109398&n=46&f=138&t=108126&p=959577)  [Reply](#) (modules.php?name=Forums&file=posting&mode=reply&t=108126)  [quote](#) (modules.php?name=Forums&file=posting&mode=quote&p=959577)  [Scrapbook](#) (http://www.rxpgonline.com/modules.php?name=RxPGites&mode=scrapbook&uid=109398)  [PM](#) (modules.php?name=Private_Messages&file=index&mode=post&u=1)

Back to top

Wed Oct 06, 2010 3:14 am (3 years ago) #47 (modules.php?name=Forums&file=viewpost&



doc_tawa (<http://www.rxpgonline.com/threads133743.html>)
 (http://www.rxpgonline.com/modules.php?name=Messenger&file=buddy&op=compose&to=doc_tawa)
 Serious Member
 ★★★★★
 Posts: 5
 Credits: 153 (<http://www.rxpgonline.com/docs/credits>)
 Aim PLAB Part 1 (<http://www.rxpgonline.com/forum138.htm>)

Back to top

oh, this is really great. thanks a lot for sharing doc. God bless!!!

report this post to a moderator (<http://www.rxpgonline.com/report/index.php?p=979508&h=47&u=>)
 please rate this post (http://www.rxpgonline.com/modules.php?name=usertools&file=pvote&vote=up&u=503349&s=133743&n=47&f=138&t=108126&p=979508)
 (http://www.rxpgonline.com/modules.php?name=usertools&file=pvote&vote=down&u=503349&s=133743&n=47&f=138&t=108126&p=979508)

[Reply](#) (modules.php?name=Forums&file=posting&mode=reply&t=108126) [quote](#) (modules.php?name=Forums&file=posting&mode=quote&p=979508) [Scrapbook](#) (http://www.rxpgonline.com/modules.php?name=RxPGites&mode=scrapbook&uid=133743) [PM](#) (modules.php?name=Private_Messages&file=index&mode=post&u=1)

Sat Oct 16, 2010 2:20 am (3 years ago) #48 (modules.php?name=Forums&file=viewpost&



AJ007 (<http://www.rxpgonline.com/threads121616.html>)
 (http://www.rxpgonline.com/modules.php?name=Messenger&file=buddy&op=compose&to=AJ007)
 Elite Veteran
 ★★★★★
 Posts: 97
 Credits: 1296 (<http://www.rxpgonline.com/docs/credits>)
 Aim PLAB Part 1 (<http://www.rxpgonline.com/forum138.htm>)

Back to top

nice effort.

report this post to a moderator (<http://www.rxpgonline.com/report/index.php?p=985170&h=48&u=>)
 please rate this post (http://www.rxpgonline.com/modules.php?name=usertools&file=pvote&vote=up&u=503349&s=121616&n=48&f=138&t=108126&p=985170)
 (http://www.rxpgonline.com/modules.php?name=usertools&file=pvote&vote=down&u=503349&s=121616&n=48&f=138&t=108126&p=985170)

[Reply](#) (modules.php?name=Forums&file=posting&mode=reply&t=108126) [quote](#) (modules.php?name=Forums&file=posting&mode=quote&p=985170) [Scrapbook](#) (http://www.rxpgonline.com/modules.php?name=RxPGites&mode=scrapbook&uid=121616) [PM](#) (modules.php?name=Private_Messages&file=index&mode=post&u=1)

Sat Oct 16, 2010 2:23 am (3 years ago) #49 (modules.php?name=Forums&file=viewpost&



AJ007 (<http://www.rxpgonline.com/threads121616.html>)
 (http://www.rxpgonline.com/modules.php?name=Messenger&file=buddy&op=compose&to=AJ007)
 Elite Veteran
 ★★★★★
 Posts: 97
 Credits: 1296 (<http://www.rxpgonline.com/docs/credits>)
 Aim PLAB Part 1 (<http://www.rxpgonline.com/forum138.htm>)

Back to top

but can u plz post sept attempt ques as well?

report this post to a moderator (<http://www.rxpgonline.com/report/index.php?p=985171&h=49&u=>)
 please rate this post (http://www.rxpgonline.com/modules.php?name=usertools&file=pvote&vote=up&u=503349&s=121616&n=49&f=138&t=108126&p=985171)
 (http://www.rxpgonline.com/modules.php?name=usertools&file=pvote&vote=down&u=503349&s=121616&n=49&f=138&t=108126&p=985171)

[Reply](#) (modules.php?name=Forums&file=posting&mode=reply&t=108126) [quote](#) (modules.php?name=Forums&file=posting&mode=quote&p=985171) [Scrapbook](#) (http://www.rxpgonline.com/modules.php?name=RxPGites&mode=scrapbook&uid=121616) [PM](#) (modules.php?name=Private_Messages&file=index&mode=post&u=1)

Thu Nov 01, 2012 3:31 am (1 year ago) #50 (modules.php?name=Forums&file=viewpost&



bushra271289 (<http://www.rxpgonline.com/threads275424.html>)
 (http://www.rxpgonline.com/modules.php?name=Messenger&file=buddy&op=compose&to=bushra271289)
 Serious Veteran
 ★★★★★
 Posts: 44
 Credits: 469 (<http://www.rxpgonline.com/docs/credits>)
 Aim PLAB Part 2 (<http://www.rxpgonline.com/forum175.htm>)

Back to top

thanks man

report this post to a moderator (<http://www.rxpgonline.com/report/index.php?p=1581180&h=50&u=>)
 please rate this post (http://www.rxpgonline.com/modules.php?name=usertools&file=pvote&vote=up&u=503349&s=275424&n=50&f=138&t=108126&p=1581180)
 (http://www.rxpgonline.com/modules.php?name=usertools&file=pvote&vote=down&u=503349&s=275424&n=50&f=138&t=108126&p=1581180)

[Reply](#) (modules.php?name=Forums&file=posting&mode=reply&t=108126) [quote](#) (modules.php?name=Forums&file=posting&mode=quote&p=1581180) [Scrapbook](#) (http://www.rxpgonline.com/modules.php?name=RxPGites&mode=scrapbook&uid=275424) [PM](#) (modules.php?name=Private_Messages&file=index&mode=post&u=2)

Topic Tags: # **papers** (<http://www.rxpgonline.com/tags/papers/>)

Search PLAB 1 forum

Go

Advertisement solutions
(<http://www.rxpg.com/ad.htm>)
:
Terms of service (TOS)
(http://www.rxpgonline.com/tos_forums.html)
:
CC BY-NC-SA
(<http://creativecommons.org/licenses/by-nc-sa/3.0>)

Quick Reply:

 (modules.php?name=Forums&file=posting&mode=newtopic&f=138)

 (modules.php?name=Forums

☐ Quote the last message

☒ Attach signature (signatures can be changed in profile)

Preview

Submit

Home
(<http://www.rxpgonline.com>)
->
Forums
(<http://www.rxpgonline.com/forumss.html>)
->
PLAB 1
(<http://www.rxpgonline.com/forum138.htm>)
-> All Plab Past Papers HERE

New posts in your browsing history

Plab 1 study material (/postp2529798.html) (1 new post)
PLAB 2 courses in Birmingham, books, etc (/postp2530794.html) (1 new post)
Got 8.5 overall (/postp2528455.html) (2 new posts)
Serious female study partner for plab 2 (/postp2528882.html) (1 new post)
November 2014 study group (/postp2529799.html) (8 new posts)

Server Status: 147 pages served in last minute. Page generation time: 1.107 seconds

Site Maps: [Books (<http://www.rxpgonline.com/allbooks.html>)] [News (<http://www.rxpgonline.com/allnews.html>)] [Forums (<http://www.rxpgonline.com/allforums.html>)] [Reviews (<http://www.rxpgonline.com/allreviews.html>)] [Mnemonics (<http://www.rxpgonline.com/allmedicalmnemonics.html>)]
sitemap (<http://www.rxpgonline.com/topics.html>) - top30 (<http://www.rxpgonline.com/top.html>) - centuries (http://www.rxpgonline.com/modules.php?name=Browse_Forum&file=centuries) - testimonials (<http://www.rxpgonline.com/modules.php?name=Guestbook>)

About Us (<http://www.rxpgonline.com/docs/about>) :: Disclaimer (<http://www.rxpgonline.com/docs/disclaimer>) :: Contact Us (<http://www.rxpgonline.com/docs/feedback>) :: Reporting abuse (<http://www.rxpgonline.com/docs/abuse>) :: Terms of Services (<http://www.rxpgonline.com/docs/tos>) :: Privacy Policy (<http://www.rxpgonline.com/docs/privacy>)
Advertise with RxPG! (<http://sales.rxpg.com>)
Made in India (<http://www.incredibleindia.org/>) by RxPG (<http://www.rxpgonline.com/modules.php?name=Feedback>) Medical Solutions Private Limited

"RxPG" is a Registered Trademark

 (<http://www.rxpgonline.com/modules.php?name=usertools&file=redirect&url=https://chrome.google.com/webstore/search-extensions/rxpg>)

 (<http://www.youtube.com/user/rxpgchannel/videos?flow=list>)

 (<http://www.rxpgonline.com/modules.php?name=usertools&file=redirect&url=http://twitter.com/RxPG>)

 (<http://www.linkedin.com/e/vgh/1816991/>)

 (<http://en.wikipedia.org/wiki/RxPG>)

 (<http://www.facebook.com/rxpgonline>)